

**PATIENT**

Gale Cayton

SPECIES

Canine

BREED

Lab X

SEX

Spayed Female

AGE

9 Years

WEIGHT

57 Pounds

INTERPRETED BYKathleen Sennello DVM,
MS, Diplomate ACVIM
(Small Animal Internal
Medicine)**IMAGING PERFORMED BY**

Amy Mayhew, LVT

HOSPITAL NAME

SVS Imaging MI

REFERRING VET

Oxford Vet Hospital

INVOICE

39476

DATE

7/13/22

PRESENTING CLINICAL SIGNS

Blood & protein loss

Abnormal PE/Chem/CBC/UA Results: 5/27/22 HCT 35.8 6/6/22 HCT 38.0 6/17/22 HCT 36.8 BW pending today.

ULTRASONOGRAPHIC EXAMINATION OF THE ABDOMEN**Urinary System**

The urinary bladder is moderately distended with anechoic urine. The Bladder wall, trigone, ureteral papillae and visible urethra (to a depth of 2cm) appear normal with no evidence of wall thickening, mucosal irregularities, masses or cystic calculi.

The left kidney has a normal shape and size (5.46 cm). Overall echogenicity is normal with adequate corticomedullary distinction and a typical 1:3 cortex:medulla ratio. There is no evidence of perinephric inflammation or effusion. There is no evidence of pyelectasia, nephroliths, infarcts or hydroureter. Renal vasculature is normal.

The right kidney has a normal shape and size (6.29 cm). Overall echogenicity is normal with adequate corticomedullary distinction and a typical 1:3 cortex:medulla ratio. There is no evidence of perinephric inflammation or effusion. There is no evidence of pyelectasia, nephroliths, infarcts or hydroureter. Renal vasculature is normal.

Adrenal Glands

The left adrenal gland is normal in size measuring 0.52 cm at the caudal pole. It is observed in its normal position cranial to the left renal artery. It is normal in appearance (uniformly hypoechoic) and shape with no evidence of a mass effect.

The right adrenal gland is normal in size measuring 0.69 cm at the caudal pole. It is observed in its normal position between the cranial aspect of the right kidney and the caudal vena cava. It is normal in appearance (uniformly hypoechoic) and shape with no evidence of a mass effect.

Spleen

The spleen is subjectively normal in size, echotexture is homogenous, and the splenic capsule is smooth with no irregularities. The blood flow through the hilus and splenic parenchyma appears normal. No focal parenchymal abnormalities are visualized.

Liver

The liver is normal/borderline small in size, and echogenicity with smooth peripheral margins. The parenchyma is heterogenous in echotexture with subtle, indistinct focal mottling. The visible portions of the vasculature and biliary tract appear normal. No focal nodules or cystic lesions are observed.

The gallbladder lumen is moderately distended. The wall of the gall bladder is not thickened and has a smooth mucosal surface. Luminal contents are primarily anechoic. The cystic and common bile ducts are normal/not visible.

Gastrointestinal

The stomach is moderately distended with air, causing a shadow that obscures visualization of portions of the wall. In the areas visualized, it measures at a normal thickness of 0.60 cm with some variability due to the presence of rugal folds. The distinction of the gastric wall layers is adequate and there is no impression of reduced peristaltic activity. No masses or focal lesions were observed.

IMAGING PERFORMED BYSVS Mobile Imaging MI 734-637-7711
svsimagingmi@gmail.comEDUCATIONAL TELECONSULTATION SERVICES™
1-800-838-4268 info@sonopath.com SonoPath.com**PATIENT**

Gale Cayton

SPECIES

Canine

BREED

Lab X

SEX

Spayed Female

AGE

9 Years

WEIGHT

57 Pounds

INTERPRETED BYKathleen Sennello DVM,
MS, Diplomate ACVIM
(Small Animal Internal
Medicine)**IMAGING PERFORMED BY**

Amy Mayhew, LVT

HOSPITAL NAME

SVS Imaging MI

REFERRING VET

Oxford Vet Hospital

INVOICE

39476

DATE

7/13/22

The visualized areas of duodenum, jejunum and ileum have a relatively uniform diameter with minimal fluid distension. Wall thickness is normal. Bowel loops follow a curvilinear path with distinct wall layering maintaining the typical 1:3 muscularis:mucosa layer ratio. Jejunum wall measured 0.36 cm. Duodenum wall measured 0.44 cm. Visualized peristalsis appears appropriate. There were no focal lesions consistent with obstruction or a mass effect observed.

The ileocecal junction was visualized and exhibited normal intact wall layering and is subjectively of normal thickness. Sections of colon are visualized with formed fecal material and gas shadowing distally. There is no observed focal or generalized colon wall thickening or loss of layering.

Pancreas

The pancreas is normal and isoechoic to surrounding mesentery. There is no evidence of nodules or cystic lesions. There is no evidence of regional mesenteric inflammation or fluid.

Free Abdomen

Evaluation of the peritoneal cavity did not reveal any evidence of effusion. A solitary cystic prominent lymph node is visualized in the right mid abdomen, measuring 1.06 cm x 1.68 cm. The omentum is of normal echogenicity.

ULTRASONOGRAPHIC FINDINGS

- Normal/borderline small, heterogeneous liver – The diffuse hepatic changes are non-specific and could be consistent with vacuolar hepatopathy, nodular hyperplasia, inflammatory/immune-mediated disease, fibrosis, extramedullary hematopoiesis, toxic hepatopathy (e.g., copper), infiltrative neoplasia (less likely) or other hepatopathy.
- Prominent cystic lymph node in the mid abdomen – The prominent abdominal lymph nodes are most consistent with reactive lymphadenitis or lymphoid hyperplasia. Neoplastic infiltration is considered less likely.

INTERPRETATION OF THE FINDINGS & FURTHER RECOMMENDATIONS

No definitive lesion is identified in the GI tract to explain the anemia and hypoalbuminemia reported. Unfortunately, there can still be ulcerations and lesions particularly in the gastric wall that can be difficult to identify due to gas shadowing, etc. If there is melena on rectal exam, then the anemia and hypoalbuminemia is likely due to GI blood loss. Consider an upper GI endoscopy to further evaluate the stomach.

If there is no melena, this anemia could also represent an anemia of chronic disease, and you still need to consider other causes for protein loss. Provided a urine protein to creatinine ratio is normal, a protein losing nephropathy is unlikely. Recommend pre- and post-prandial bile acids to look for any evidence of liver dysfunction contributing to the hypoalbuminemia, and consider a liver biopsy +/- contrast CT scan if bile acids are significantly elevated.

If bile acids are normal, and a UPC is normal, then a protein losing enteropathy is most likely.

- Recommend screening for Addison's prior to GI workup.
- If cortisol levels are normal, then consider GI parasitism with empirical deworming and parasite screening.
- Consider anti-ulcer therapy.
- Consider further evaluation of the GI tract with upper GI endoscopy, sampling, etc. Unfortunately, this does not evaluate all of the GI tract, which could necessitate surgery or

IMAGING PERFORMED BY

SVS Mobile Imaging MI 734-637-7711
svsimagingmi@gmail.com



EDUCATIONAL TELECONSULTATION SERVICES™
1-800-838-4268 info@sonopath.com SonoPath.com

PATIENT

Gale Cayton

SPECIES

Canine

BREED

Lab X

SEX

Spayed Female

AGE

9 Years

WEIGHT

57 Pounds

INTERPRETED BY

Kathleen Sennello DVM,
MS, Diplomate ACVIM
(Small Animal Internal
Medicine)

IMAGING PERFORMED BY

Amy Mayhew, LVT

HOSPITAL NAME

SVS Imaging MI

REFERRING VET

Oxford Vet Hospital

INVOICE

39476

DATE

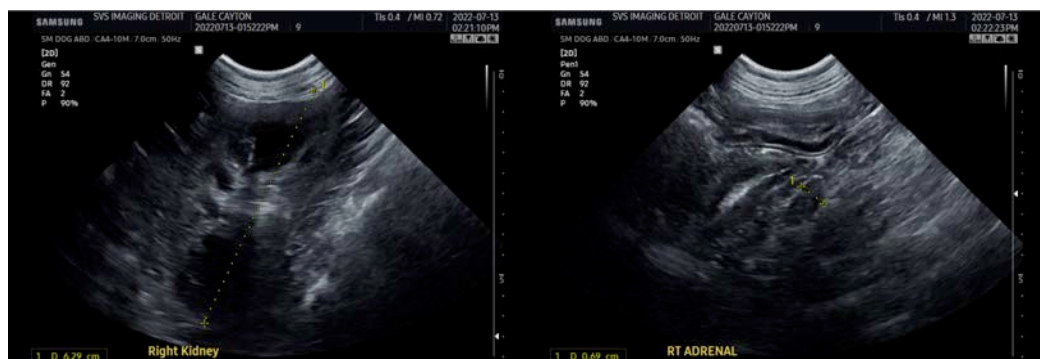
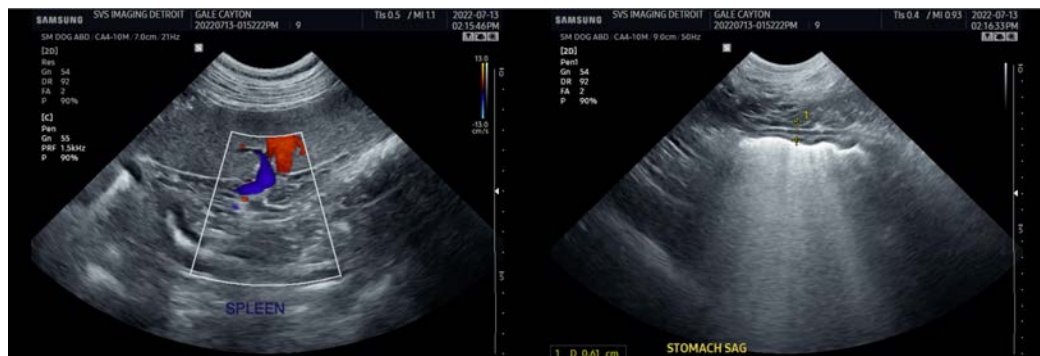
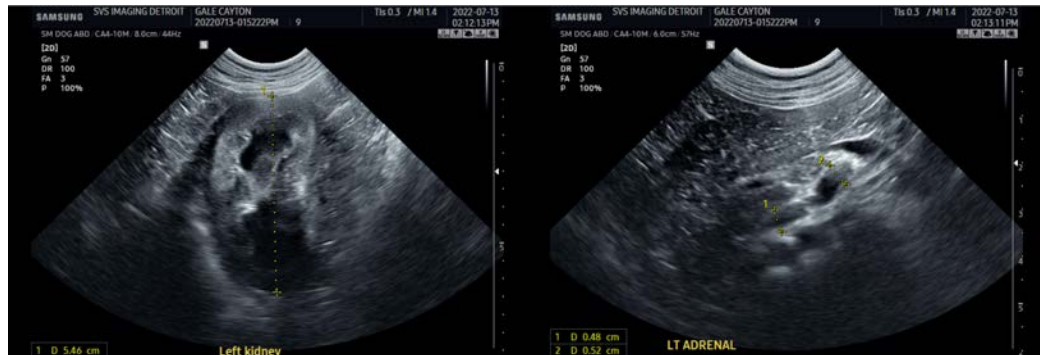
7/13/22

contrast CT scan.

Consider a novel protein/hydrolyzed protein prescription diet in case a dietary sensitivity/food allergy is contributing to ulceration. Recommend chronic probiotic therapy. Consider measuring iron levels, as an iron deficiency anemia can develop with chronic GI blood loss.

Consider three view thoracic radiographs to rule out concurrent thoracic disease/involvement.

An aspirate of the enlarged abdominal lymph node could be considered, but keep in mind there is a vessel adjacent to this node, and it is cystic, which makes this a technically challenging procedure.



IMAGING PERFORMED BY

SVS Mobile Imaging MI 734-637-7711
svsimagingmi@gmail.com



PATIENT

Gale Cayton

SPECIES

Canine

BREED

Lab X

SEX

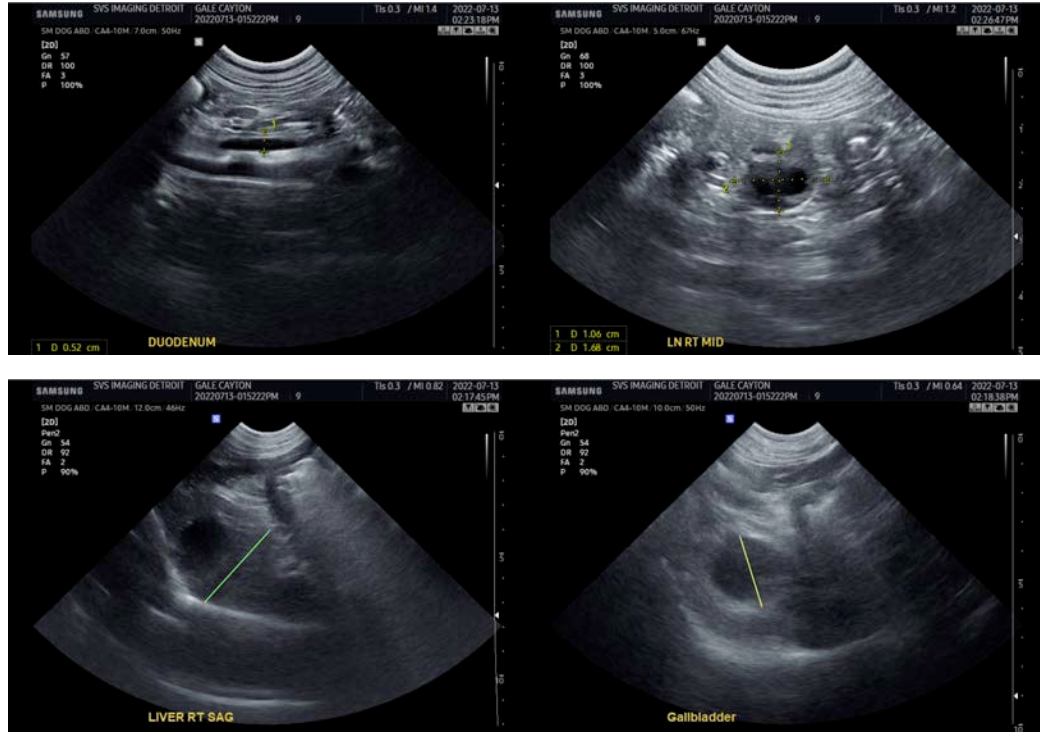
Spayed Female

AGE

9 Years

WEIGHT

57 Pounds



The information and recommendations provided are based on the images presented by the referring veterinarian/sonographer. No evaluation can be communicated regarding pathology that was not visible in the image/video clips provided.

INTERPRETED BY

Kathleen Sennello DVM,
MS, Diplomate ACVIM
(Small Animal Internal
Medicine)

Thank you for this referral. If the clinical or image interpretation does not parallel your findings or if I can be of any further assistance please contact me.

Kathleen Sennello DVM,MS, Diplomate ACVIM (Small animal Internal Medicine)

kathleen.sennello@sonopath.com

IMAGING PERFORMED BY

Amy Mayhew, LVT

HOSPITAL NAME

SVS Imaging MI

REFERRING VET

Oxford Vet Hospital

INVOICE

39476

DATE

7/13/22