

PATIENT PRESENTING CLINICAL SIGNS

PATIENT Perry Chemey
SPECIES Feline
BREED DSH
SEX Neutered Male
AGE 7 yrs
WEIGHT 8.06 lbs

7-year-old MN DSH - 1-2-year hx of diarrhea, No improvement with fortiflora. p is currently on GI Biome. P has recently started defecating outside of litter box, seems to not realize he is defecating until after it happens.

Abnormal PE/Chem/CBC/UA Results: Spec fPL 8.6 (0-3.5), Cobalamin 1585 (276-1425), positive Feline Coronavirus RealPCR and C. perfringens alpha toxin Gene RealPCR Current Medications metronidazole 62.5mg BID Radiographic Findings None taken.

ULTRASONOGRAPHIC EXAMINATION OF THE ABDOMEN

Urinary System

The urinary bladder is moderately distended with anechoic urine. The Bladder wall, trigone, ureteral papillae, and visible urethra (to a depth of 2cm) appear normal with no evidence of wall thickening, mucosal irregularities, masses, or cystic calculi.

The left kidney has a normal shape and size (4.08 cm). Overall echogenicity is normal with adequate corticomedullary distinction and a typical 1:3 cortex: medulla ratio. There is no evidence of focal perinephric inflammation or effusion. There is no evidence of pyelectasia, nephroliths, infarcts or hydroureter. Renal vasculature is normal.

The right kidney has a normal shape and size (4.45 cm). Overall echogenicity is normal with adequate corticomedullary distinction and a typical 1:3 cortex: medulla ratio. There is no evidence of focal perinephric inflammation or effusion. There is no evidence of pyelectasia, nephroliths, infarcts or hydroureter. Renal vasculature is normal.

Adrenal Glands

The left adrenal gland is borderline enlarged in size measuring 0.57 cm at the caudal pole. It is observed in its normal position cranial to the left renal artery. It is normal in appearance (uniformly hypoechoic) and shape with no evidence of a mass effect.

The right adrenal gland is borderline enlarged in size measuring 0.47 cm at the caudal pole. It is observed in its normal position between the cranial aspect of the right kidney and the caudal vena cava. It is normal in appearance (uniformly hypoechoic) and shape with no evidence of a mass effect.

Spleen

The spleen is subjectively normal in size (0.74 cm), echotexture is homogenous, and the splenic capsule is smooth with no irregularities. The blood flow through the hilus and splenic parenchyma appears normal. No focal parenchymal abnormalities are visualized.

Liver

The liver is subjectively normal in size, and echogenicity with smooth peripheral margins. The parenchyma is homogenous echotexture. The visible portions of the vasculature and biliary tract appear normal. No focal nodules or cystic lesions are observed.

INTERPRETED BY

Kathleen Sennello DVM, MS, Diplomate ACVIM (Small Animal Internal Medicine)

IMAGING PERFORMED BY

Sara Hansen

HOSPITAL NAME

West Hills Animal Hospital

REFERRING VET

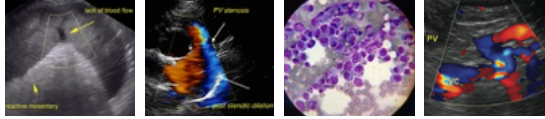
Dr. Cole

INVOICE

10316

DATE

7/12/2023



PATIENT

Perry Chemey

The gallbladder lumen is moderately distended. The wall of the gall bladder is not thickened and has a smooth mucosal surface. Luminal contents are mild and primarily anechoic. The cystic and common bile ducts are normal/not visible.

SPECIES

Feline

Gastrointestinal

The stomach contains minimal luminal contents. It measures at a normal thickness of <0.36cm with some variability due to the presence of rugal folds. The distinction of the gastric wall layers is adequate and there is no impression of reduced peristaltic activity. No masses or focal lesions were observed.

BREED

DSH

The visualized areas of duodenum, jejunum and ileum have a relatively uniform diameter with minimal fluid distension. Wall thickness is normal. Bowel loops follow a curvilinear path with distinct wall layering maintaining the typical 1:3 muscularis: mucosa layer ratio. The jejunum measured as normal (0.26 cm.) Visualized peristalsis appears appropriate. There were no focal lesions consistent with obstruction or a mass effect observed.

SEX

Neutered Male

AGE

7 yrs

The ileocecal junction was visualized and exhibited normal intact wall layering and is subjectively of normal thickness. Sections of colon are distended with liquid fecal material and gas shadowing distally. There is no observed focal or generalized colon wall thickening or loss of layering.

WEIGHT

8.06 lbs

Pancreas

The pancreas is normal and isoechoic to surrounding mesentery. There is no evidence of nodules or cystic lesions. There is no evidence of regional mesenteric inflammation or fluid.

INTERPRETED BY

Kathleen Sennello DVM,
MS, Diplomate ACVIM
(Small Animal Internal
Medicine)

Free Abdomen

Evaluation of the peritoneal cavity did not reveal any evidence of effusion. There are visible mesenteric lymph nodes, particularly a small cluster near the ileocecal junction measuring 0.26 cm and 0.29 cm. The Medial iliac nodes appear normal and there was no evidence of a caudal aortic thrombus at the bifurcation. The omentum is generally of normal echogenicity.

IMAGING PERFORMED BY

Sara Hansen

PRIMARY FINDINGS

- Fluid distended colon. Findings are consistent with the diarrhea reported.
- Prominent/visible mesenteric lymph nodes. The prominent abdominal lymph nodes are most consistent with reactive lymphadenitis or lymphoid hyperplasia. Neoplastic infiltration is considered less likely.

HOSPITAL NAME

West Hills Animal
Hospital

SECONDARY FINDINGS

- Borderline large adrenals this could be secondary to the stress of chronic illness.

REFERRING VET

Dr. Cole

INVOICE

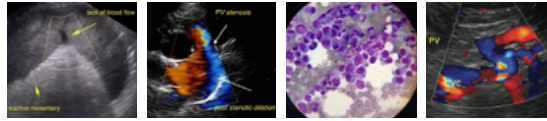
10316

DATE

7/12/2023

INTERPRETATION OF THE FINDINGS & FURTHER RECOMMENDATIONS

The changes observed on today's scan are expected with a history of chronic diarrhea. No focal GI lesions are observed to explain this diarrhea. A primary enteropathy is likely present and unfortunately is not uncommon with chronic diarrhea for the cause to not be determine by ultrasound alone.



PATIENT

Perry Chemey

SPECIES

Feline

BREED

DSH

SEX

Neutered Male

AGE

7 yrs

WEIGHT

8.06 lbs

INTERPRETED BY

Kathleen Sennello DVM,
MS, Diplomate ACVIM
(Small Animal Internal
Medicine)

IMAGING PERFORMED BY

Sara Hansen

HOSPITAL NAME

West Hills Animal
Hospital

REFERRING VET

Dr. Cole

INVOICE

10316

DATE

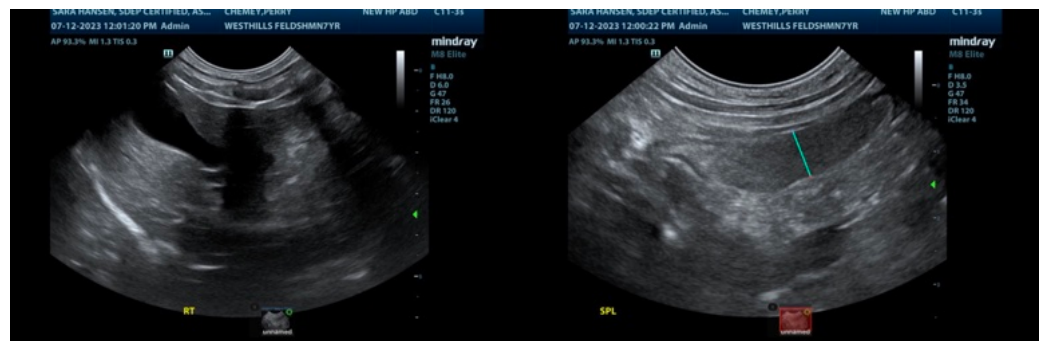
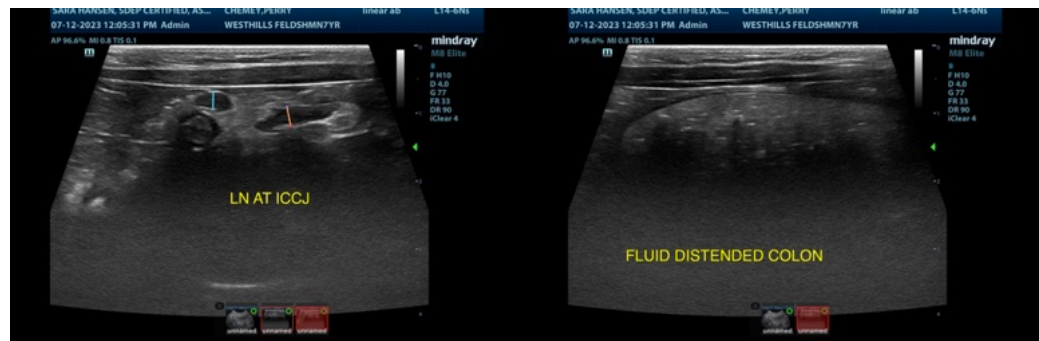
7/12/2023

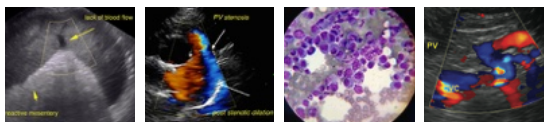
Consider such differentials as food allergy/dietary intolerance, GI parasitism, pancreatitis, dysbiosis, recurrent dietary indiscretion, IBD and less likely neoplasia, etc.....

- Consider a novel protein/hydrolyzed protein diet (exclusively at least 4-6 weeks)
- Consider a GI panel to Texas A&M for evaluation of B12 levels, folate, PLI/TLI etc. to further evaluate for pancreatic/small intestinal disease.
- Recommend chronic probiotic therapy.

Given the carnosity of these symptoms I suspect many of these steps have already been taken. If that is the case, I would strongly consider the possibility of an upper and lower GI endoscopy to further evaluated.

Recommend three view thoracic radiographs to evaluate for possible concurrent thoracic disease/involvement.





PATIENT

Perry Chemey

SPECIES

Feline

BREED

DSH

SEX

Neutered Male

AGE

7 yrs

WEIGHT

8.06 lbs

INTERPRETED BY

Kathleen Sennello DVM,
MS, Diplomate ACVIM
(Small Animal Internal
Medicine)

IMAGING PERFORMED BY

Sara Hansen

HOSPITAL NAME

West Hills Animal
Hospital

REFERRING VET

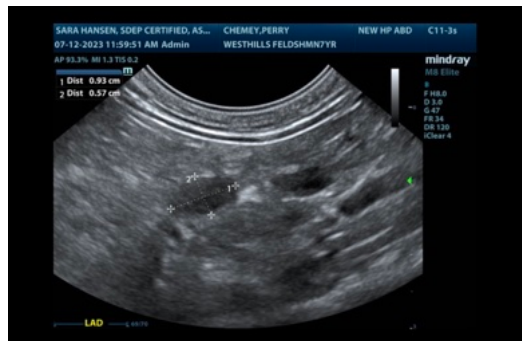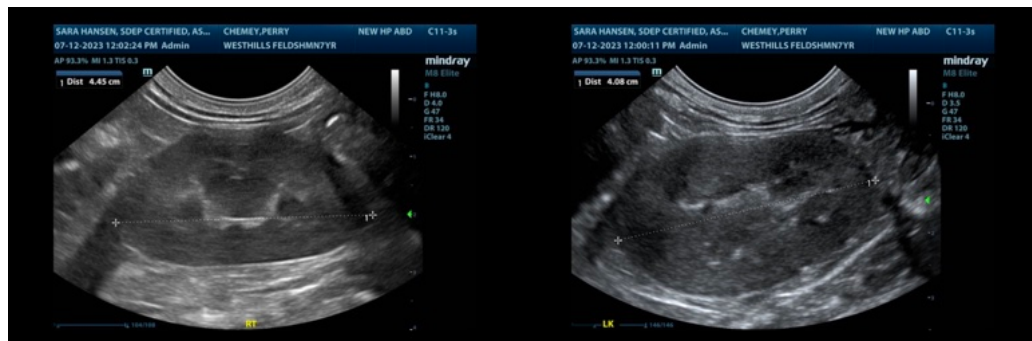
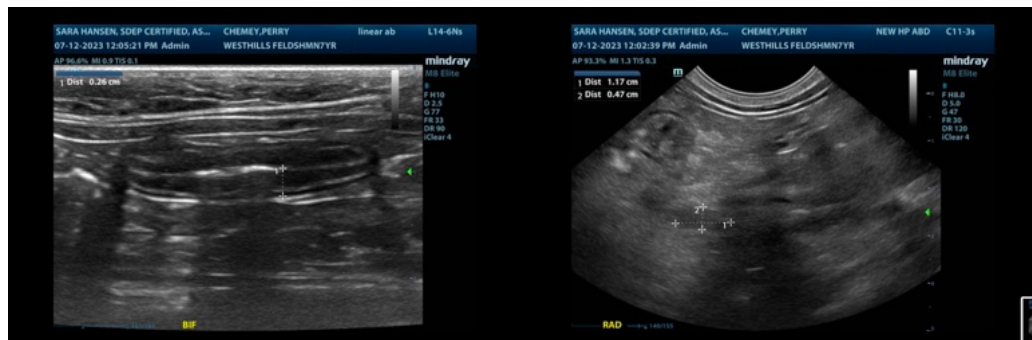
Dr. Cole

INVOICE

10316

DATE

7/12/2023



The information and recommendations provided are based on the images presented by the referring veterinarian/sonographer. No evaluation can be communicated regarding pathology that was not visible in the image/video clips provided.

Thank you for this referral. If the clinical or image interpretation does not parallel your findings or if I can be of any further assistance, please contact me.

Kathleen Sennello DVM, MS, Diplomate ACVIM (Small animal Internal Medicine)

info@sonopath.com