

IMAGING PERFORMED BY

IntraPet.com



**SonoPath**

Clinical Sonography & Telecytology

EDUCATIONAL TELECONSULTATION SERVICES™

1-800-838-4268 info@sonopath.com SonoPath.com

**DATE PRESENTING CLINICAL SIGNS**

7/12/22 Patient presented for defecating outside litterbox, exam showed doughy abdomen, pale pink MM and 2/6 murmur, owner reported vomiting food and water more frequently the last few months.

**PATIENT**

Nikki Gordon Current Medications: None listed.  
Lab Results: inc SDMA and BUN, dec WBC, Neutrophils, Lymphocytes, elevated Cardiotet.

Date of Previous IntraPet Ultrasound: No previous.

Sedation: Not required to complete full diagnostic ultrasound.

Stat Report: Not requested.

**SPECIES**

Feline

**ULTRASONOGRAPHIC EXAMINATION OF THE ABDOMEN**

**BREED**

**Urinary System**

DSH

The urinary bladder is moderately distended with mild primarily suspended echogenic debris present. The Bladder wall, trigone, ureteral papillae and visible urethra (to a depth of 2cm) appear normal with no evidence of wall thickening, mucosal irregularities, masses or calculi. Echogenic debris of this type can be associated with small crystals, cellular debris and proteinaceous debris.

**SEX**

Spayed Female

The left kidney has a normal shape and size (2.89 cm) with mild pyelectasia at 0.22 cm. Overall echogenicity is slightly hyperechoic with poor corticomedullary distinction and a typical 1:3 cortex:medulla ratio. There is no evidence of perinephric inflammation or effusion. There is no evidence of nephroliths, infarcts or hydroureter. Renal vasculature is normal.

**AGE**

7/7/04

The right kidney has a normal shape and size (3.02 cm) with mild pyelectasia at 0.15 cm. Overall echogenicity is slightly hyperechoic with poor corticomedullary distinction and a typical 1:3 cortex:medulla ratio. There is no evidence of perinephric inflammation or effusion. There is no evidence of nephroliths, infarcts or hydroureter. Renal vasculature is normal.

**WEIGHT**

6 Pounds

**INTERPRETED BY**

Kathleen Sennello DVM,  
MS, Diplomate ACVIM  
(Small Animal Internal  
Medicine)

**Adrenal Glands**

The left adrenal gland is normal in size measuring 0.38 cm at the caudal pole. It is observed in its normal position cranial to the left renal artery. There are occasional punctate hyperechoic foci visualized within the parenchyma, most consistent with small, incidental mineralizations.

**IMAGING PERFORMED BY**

Stephanie Pearce  
RDMS, RVT

The right adrenal gland is normal in size measuring 0.38 cm at the caudal pole. It is observed in its normal position between the cranial aspect of the right kidney and the caudal vena cava. It is normal in appearance (uniformly hypoechoic) and shape with no evidence of a mass effect.

**HOSPITAL NAME**

Animal Care Center

**Spleen**

The spleen is subjectively normal in size, echotexture is homogenous, and the splenic capsule is smooth with no irregularities. The blood flow through the hilus and splenic parenchyma appears normal. No focal parenchymal abnormalities are visualized.

**REFERRING VET**

Dr. Muedeking

**Liver**

The liver is subjectively normal in size, and echogenicity with smooth peripheral margins. The parenchyma is homogenous echotexture. The visible portions of the vasculature and biliary tract appear normal. No focal nodules or cystic lesions are observed.

**INVOICE**

39396

The gallbladder lumen is moderately distended. The wall of the gall bladder is not thickened and has a smooth mucosal surface. Luminal contents are primarily anechoic. The cystic and common bile ducts are normal/not visible.

### ***Gastrointestinal***

The stomach contains mild fluid within the lumen. It measures at a normal thickness of <0.36cm with some variability due to the presence of rugal folds. The distinction of the gastric wall layers is adequate and there is no impression of reduced peristaltic activity. No masses or focal lesions were observed.

Most of the visualized areas of duodenum, jejunum and ileum have a relatively uniform diameter with minimal fluid distension. Wall thickness is normal. Bowel loops follow a curvilinear path with distinct wall layering maintaining the typical 1:3 muscularis:mucosa layer ratio. Jejunum wall measured 0.26 cm. Visualized peristalsis appears appropriate. There were no focal lesions consistent with obstruction or a mass effect observed. There is mild intermittent fluid dilation of some areas of small intestine.

The ileocecal junction was visualized and exhibited normal intact wall layering and is subjectively of normal thickness. Sections of colon are visualized with formed fecal material and gas shadowing distally. There is no observed focal or generalized colon wall thickening or loss of layering.

### ***Pancreas***

The pancreas is prominent and hypoechoic as compared to the surrounding isoechoic mesentery. There is no evidence of nodules or cystic lesions. There is no evidence of regional mesenteric inflammation or fluid.

### ***Free Abdomen***

Evaluation of the peritoneal cavity did not reveal any evidence of effusion, or subjective lymphadenomegaly. The Medial iliac nodes appear normal and there was no evidence of a caudal aortic thrombus at the bifurcation. The omentum is of normal uniform echogenicity.

### ***Other***

A brief view of the heart was submitted. No significant pericardial effusion was seen.

## **PRIMARY FINDINGS**

- Decreased corticomedullary distinction in both kidneys with mild pyelectasia – The bilateral renal findings are consistent with age-related change. Pyelectasia of the left/right kidney could be consistent with pyelonephritis, chronic renal disease, secondary to PU/PD or fluid therapy (if applicable), other.
- Prominent, hypoechoic pancreas – The pancreatic changes are most consistent with mild pancreatitis or a recent episode of pancreatic inflammation.
- Mildly fluid dilated stomach and some areas of small intestine – could be consistent with mild ileus/enteritis. No obvious foreign material is visualized, but correlate with abdominal radiographs, as some types of foreign material can be difficult to visualize with ultrasound.

## **SECONDARY FINDINGS**

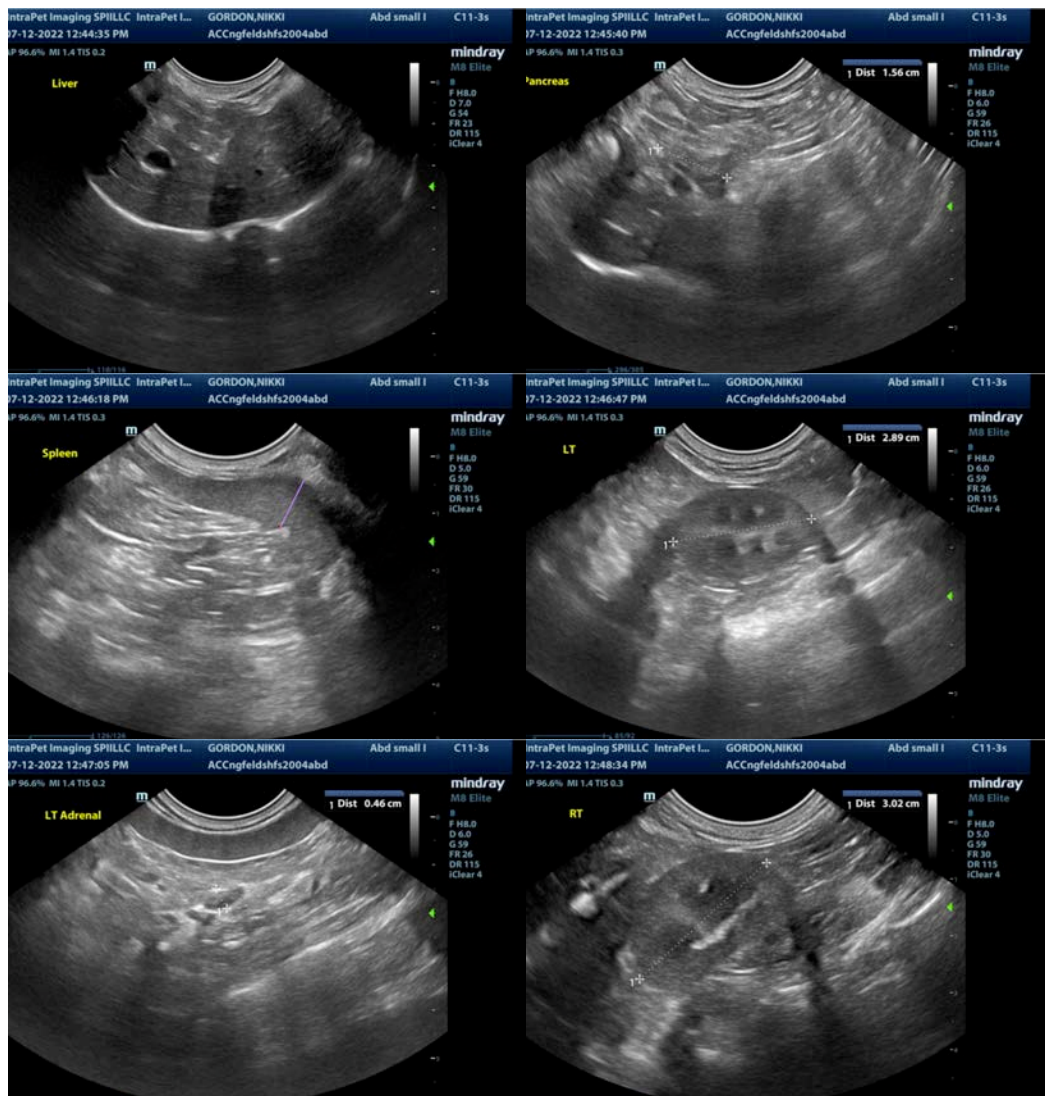
- Mildly echogenic debris in the urinary bladder – The echogenic debris in the bladder lumen could be consistent with cells, crystals, and/or mucus.
- Hyperechoic foci within the left adrenal gland – most consistent with mild mineralization. This is likely an incidental change.

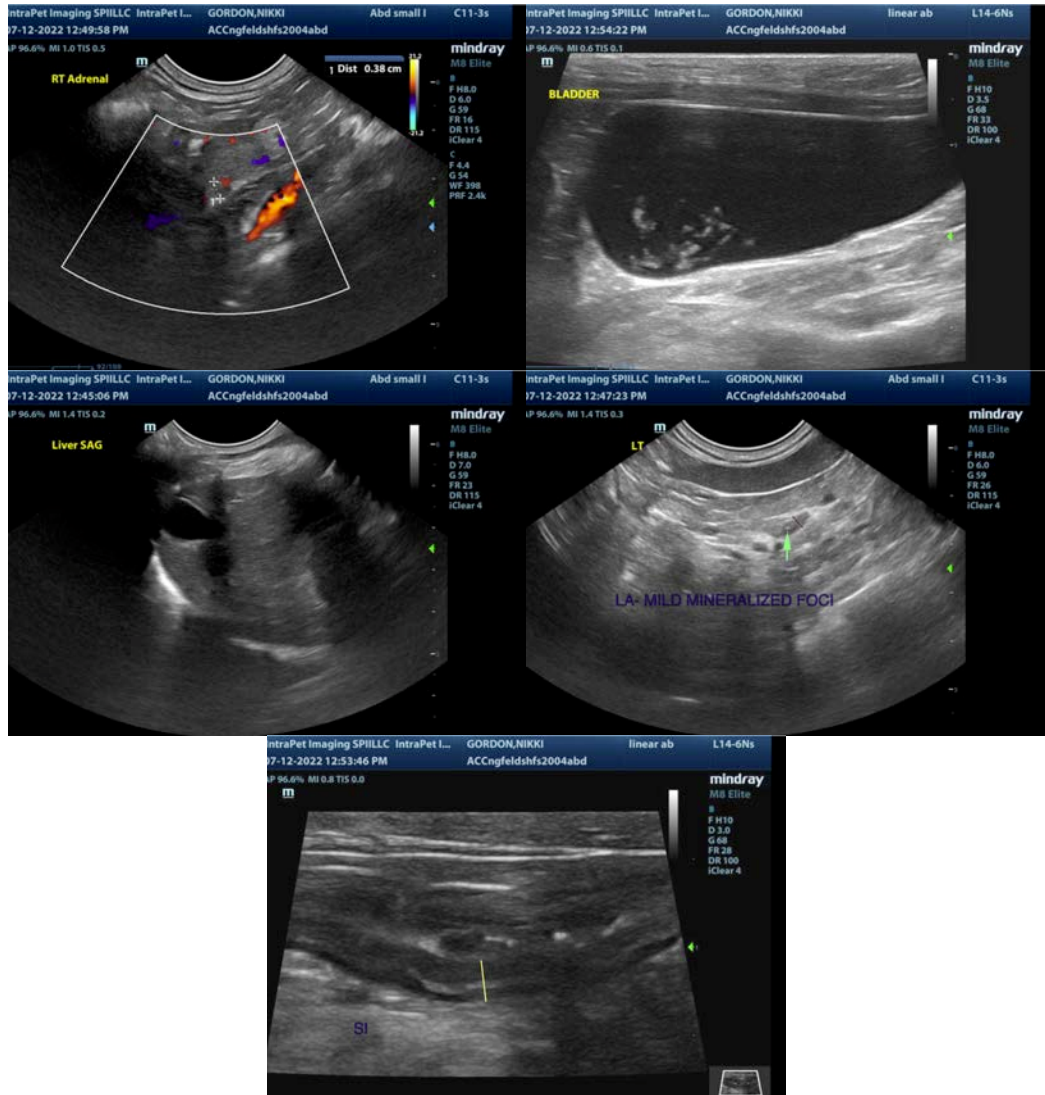
## INTERPRETATION OF THE FINDINGS & FURTHER RECOMMENDATIONS

No large focal lesions are visualized on today's scan. The pancreas is prominent and hypoechoic. Recommend a GI panel to Texas A&M with a qualitative fPLI, TLI, cobalamin and folate to further evaluate the pancreas and small intestine. Recommend treatment for pancreatitis.

Additionally, there is some fluid dilation in the stomach and small bowel. Correlate this with feeding history and abdominal radiographs. No distinct foreign material was observed, so this could be secondary to ileus or enteritis, but continued vigilance for foreign material is warranted if symptoms are not improving. If symptoms persist, it may be necessary to obtain GI biopsies for further information.

Consider three view thoracic radiographs to rule out concurrent thoracic disease/involvement.





The information and recommendations provided are based on the images presented by the referring veterinarian/sonographer. No evaluation can be communicated regarding pathology that was not visible in the image/video clips provided.

Thank you for this referral. If the clinical or image interpretation does not parallel your findings or if I can be of any further assistance please contact me.

Kathleen Sennello DVM,MS, Diplomate ACVIM (Small animal Internal Medicine)  
 kathleen.sennello@sonopath.com