

IMAGING PERFORMED BY

IntraPet.com



 **SonoPath**

Clinical Sonography & Telectology

EDUCATIONAL TELECONSULTATION SERVICES™

1-800-838-4268 info@sonopath.com SonoPath.com

DATE PRESENTING CLINICAL SIGNS

7/12/22 Lost 4 pounds/intermittent vomiting and anorexia.

PATIENT Current Medications: Doxycycline 20mg/mL 0.8mL BID for 10 days, Mirataz transdermal 1 inch to ear flap.
Lab Results: WNL except T4 low.

Franklin Styrcula Radiographs: Thickened loop of intestines.

Date of Previous IntraPet Ultrasound: No previous.

SPECIES Sedation: Not required to complete full diagnostic ultrasound.

Stat Report: Not requested.

Feline

ULTRASONOGRAPHIC EXAMINATION OF THE ABDOMEN

BREED

Urinary System

DSH

The urinary bladder is moderately distended with anechoic urine. The Bladder wall, trigone, ureteral papillae and visible urethra (to a depth of 2cm) appear normal with no evidence of wall thickening, mucosal irregularities, masses or cystic calculi.

SEX

The left kidney is small, hyperechoic and slightly irregular, measuring 3.13 cm with decreased corticomedullary distinction and pyelectasia at 0.58 cm. There is no evidence of perinephric inflammation or effusion. There is no evidence of nephroliths, infarcts or hydroureter. Renal vasculature is normal.

AGE

10/7/10

The right kidney is normal/borderline large in size 4.03 cm. Overall echogenicity is normal with adequate corticomedullary distinction and a typical 1:3 cortex:medulla ratio. There is no evidence of perinephric inflammation or effusion. There is no evidence of pyelectasia, nephroliths, infarcts or hydroureter. Renal vasculature is normal.

WEIGHT

6 lb 4 oz

INTERPRETED BY

Kathleen Sennello DVM,
MS, Diplomate ACVIM
(Small Animal Internal
Medicine)

Adrenal Glands

The left adrenal gland is normal in size measuring 0.33 cm at the caudal pole. It is observed in its normal position cranial to the left renal artery. It is normal in appearance (uniformly hypoechoic) and shape with no evidence of a mass effect.

The right adrenal gland is normal in size measuring 0.43 cm at the caudal pole. It is observed in its normal position between the cranial aspect of the right kidney and the caudal vena cava. It is normal in appearance (uniformly hypoechoic) and shape with no evidence of a mass effect.

IMAGING PERFORMED BY

Stephanie Pearce
RDMS, RVT

Spleen

The spleen is subjectively normal in size, echotexture is homogenous, and the splenic capsule is smooth with no irregularities. The blood flow through the hilus and splenic parenchyma appears normal. No focal parenchymal abnormalities are visualized.

HOSPITAL NAME

Chadwell AH

Liver

The liver is subjectively normal in size with smooth peripheral margins. The parenchyma is hyperechoic and homogenous in echotexture. The visible portions of the vasculature and biliary tract appear normal. No focal nodules or cystic lesions are observed.

REFERRING VET

Dr. Gold

The gallbladder lumen is moderately distended. The wall of the gall bladder is not thickened and has a smooth mucosal surface. Luminal contents are primarily anechoic. The cystic and common bile ducts are normal/not visible.

INVOICE

39434

Gastrointestinal

The stomach contains minimal luminal contents. It measures at a normal thickness of <0.36cm with some variability due to the presence of rugal folds. The distinction of the gastric wall layers is adequate and there is no impression of reduced peristaltic activity. No masses or focal lesions were observed.

The visualized areas of duodenum, jejunum and ileum have a uniform diameter with minimal fluid distension. Wall thickness is normal to slightly increased. Bowel loops follow a typical curvilinear path with distinct wall layering, but some areas display a prominent muscularis layer which does not display the typical 1:3 muscularis:mucosa layer ratio. Jejunum wall measured 0.27 cm. Visualized peristalsis appears appropriate. There were no focal lesions consistent with obstruction or a mass effect observed.

The ileocecal junction was visualized and exhibited normal intact wall layering and is subjectively of normal thickness. Sections of colon are visualized with formed fecal material and gas shadowing distally. There is no observed focal or generalized colon wall thickening or loss of layering.

Pancreas

The pancreas is large and hypoechoic to surrounding mesentery. There is no evidence of nodules or cystic lesions. There is evidence of regional mesenteric inflammation. Consistent with mild pancreatitis.

Free Abdomen

Evaluation of the peritoneal cavity did not reveal any evidence of effusion, or subjective lymphadenomegaly. The Medial iliac nodes appear normal and there was no evidence of a caudal aortic thrombus at the bifurcation. The omentum is of normal uniform echogenicity.

ULTRASONOGRAPHIC FINDINGS

- Small, irregular hyperechoic left kidney with mild pyelectasia, and mildly hypertrophied right kidney – most consistent with previous injury to the left kidney and compensatory in size in the right kidney.
- Hypoechoic pancreas with mild hyperechoic surrounding mesentery – The pancreatic changes are most consistent with moderate pancreatitis/pancreatic inflammation. Recommend fPLI testing and continued monitoring for improvement or possible development of a pancreatic abscess. Consider fine needle aspirate if not improving.
- Hyperechoic liver – Hepatic changes are non-specific and could be consistent with hepatic lipidosis, inflammatory/infectious disease, infiltrative neoplasia, or other hepatopathy.
- Significantly prominent muscularis layer to the small intestine – The small intestinal wall changes are most consistent with an inflammatory process (i.e., inflammatory bowel disease) with a low possibility of emerging lymphoma.

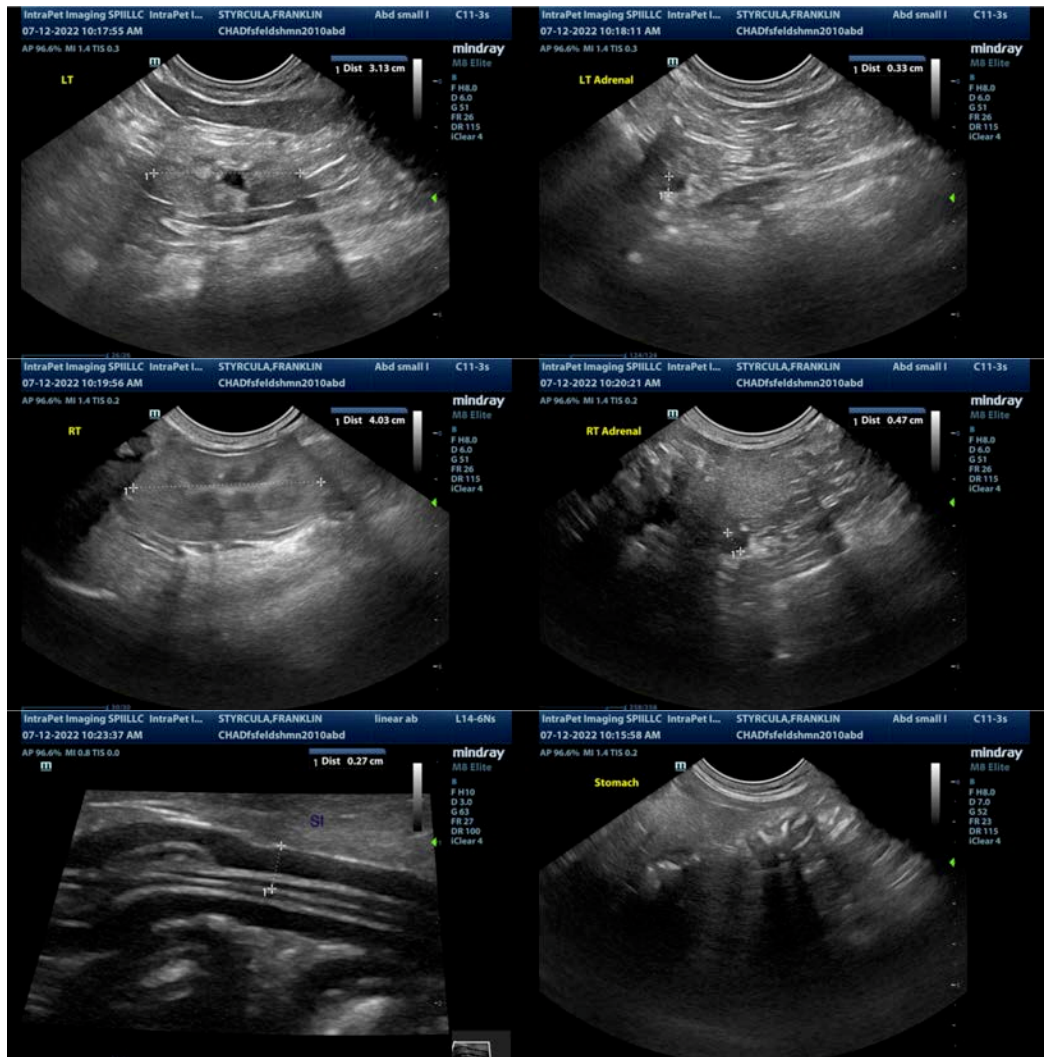
INTERPRETATION OF THE FINDINGS & FURTHER RECOMMENDATIONS

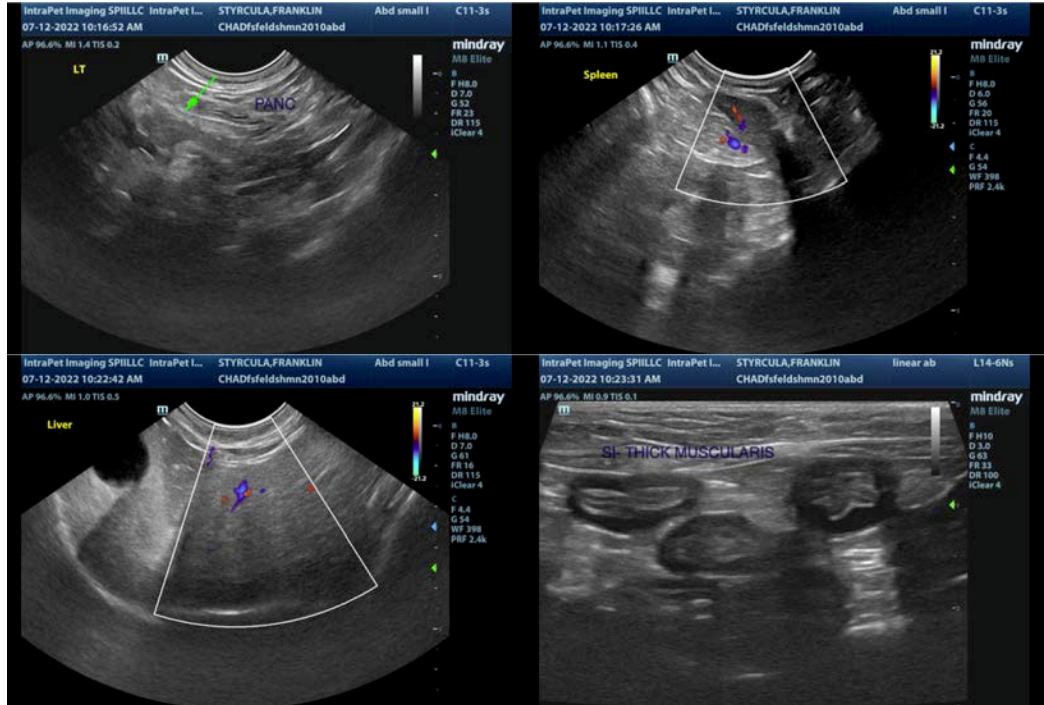
The bowel appears "ropey" with a very prominent muscularis layer. This could be consistent with chronic inflammatory disease, IBD, etc. (less likely intestinal neoplasia). Additionally, the pancreas appears hypoechoic and somewhat prominent with hyperechoic mesentery near the right limb, and the liver is hyperechoic. These changes could be consistent with Triaditis, or GI disease with secondary lipidosis, or even lymphoma. Consider the following:

- Recommend a GI panel to Texas A&M with a qualitative fPLI, TLI, cobalamin and folate to further evaluate the pancreas and small intestine.
- Recommend treatment for pancreatitis.

- Recommend a novel protein/hydrolyzed protein prescription diet.
- Recommend chronic probiotic therapy.
- Consider obtaining GI biopsies to further evaluate the thickening of the small intestine noted.

Consider three view thoracic radiographs to rule out concurrent thoracic disease/involvement.





The information and recommendations provided are based on the images presented by the referring veterinarian/sonographer. No evaluation can be communicated regarding pathology that was not visible in the image/video clips provided.

Thank you for this referral. If the clinical or image interpretation does not parallel your findings or if I can be of any further assistance please contact me.

Kathleen Sennello DVM,MS, Diplomate ACVIM (Small animal Internal Medicine)
kathleen.sennello@sonopath.com