



PATIENT

Baby Toes Taylor

SPECIES

Feline

BREED

DSH

SEX

Spayed Female

AGE

12 Years

WEIGHT

12.8 Pounds

INTERPRETED BY

Kathleen Sennello DVM,
MS, Diplomate ACVIM
(Small Animal Internal
Medicine)

**IMAGING
PERFORMED BY**

Dr. Desen Ertunc

HOSPITAL NAME

Healing Spirit

REFERRING VET

Dr. Desen Ertunc

INVOICE

39446

DATE

7/12/22

PRESENTING CLINICAL SIGNS

Mild weight loss, intermittent hyporexia despite high TT4, fT4 in normal range. Intermittent trembling. Abnormal PE/Chem/CBC/UA Results: PE- WNL. BCS 6.5/9 U/A: U.S.G.> 1.050 Inactive sediment fT4 (ED)= 3.5 (1.2-4.3) March 2022: CBC: platelets=217 (300-800) K/uL CHEM: WNL T4=5.9 (1.5-4.8) ug/dL

ULTRASONOGRAPHIC EXAMINATION OF THE ABDOMEN

Urinary System

The urinary bladder is moderately distended with mild primarily suspended echogenic debris present. The Bladder wall, trigone, ureteral papillae and visible urethra (to a depth of 2cm) appear normal with no evidence of wall thickening, mucosal irregularities, masses or calculi. Echogenic debris of this type can be associated with small crystals, cellular debris and proteinaceous debris.

The left kidney has a normal shape and size (3.98 cm). Overall echogenicity is normal with adequate corticomedullary distinction and a typical 1:3 cortex:medulla ratio. There is no evidence of perinephric inflammation or effusion. There is no evidence of pyelectasia, nephroliths, infarcts or hydroureter. Renal vasculature is normal.

The right kidney has a normal shape and size (4.3 cm). Overall echogenicity is normal with adequate corticomedullary distinction and a typical 1:3 cortex:medulla ratio. There is no evidence of perinephric inflammation or effusion. There is no evidence of pyelectasia, nephroliths, infarcts or hydroureter. Renal vasculature is normal.

Adrenal Glands

The left adrenal gland is normal in size measuring 0.35 cm at the caudal pole. It is observed in its normal position cranial to the left renal artery. It is normal in appearance (uniformly hypoechoic) and shape with no evidence of a mass effect.

The right adrenal gland is normal in size measuring 0.30 cm at the caudal pole. It is observed in its normal position between the cranial aspect of the right kidney and the caudal vena cava. It is normal in appearance (uniformly hypoechoic) and shape with no evidence of a mass effect.

Spleen

The spleen is subjectively normal in size (1.0 cm), echotexture is homogenous, and the splenic capsule is smooth with no irregularities. The blood flow through the hilus and splenic parenchyma appears normal. No focal parenchymal abnormalities are visualized.

Liver

The liver is subjectively normal in size, and echogenicity with smooth peripheral margins. The parenchyma is homogenous echotexture. The visible portions of the vasculature and biliary tract appear normal. No focal nodules or cystic lesions are observed.

The gallbladder lumen is moderately distended. The wall of the gall bladder is not thickened and has a smooth mucosal surface. Luminal contents are primarily anechoic. The bile duct is visualized as mildly dilated and tortuous, measuring at 0.43 cm. No obstruction is visualized.



PATIENT

Baby Toes Taylor

SPECIES

Feline

BREED

DSH

SEX

Spayed Female

AGE

12 Years

WEIGHT

12.8 Pounds

INTERPRETED BY

Kathleen Sennello DVM,
MS, Diplomate ACVIM
(Small Animal Internal
Medicine)

**IMAGING
PERFORMED BY**

Dr. Desen Ertunc

HOSPITAL NAME

Healing Spirit

REFERRING VET

Dr. Desen Ertunc

INVOICE

39446

DATE

7/12/22

Gastrointestinal

The stomach contains minimal luminal contents. It measures at a normal thickness of <0.36cm with some variability due to the presence of rugal folds. The distinction of the gastric wall layers is adequate and there is no impression of reduced peristaltic activity. No masses or focal lesions were observed.

The visualized areas of duodenum, jejunum and ileum have a uniform diameter with minimal fluid distension. Wall thickness is normal to slightly increased. Bowel loops follow a typical curvilinear path with distinct wall layering, but some areas display a prominent muscularis layer which does not display the typical 1:3 muscularis:mucosa layer ratio. Jejunum wall measured 0.26 cm. Duodenum wall measured 0.35 cm. Visualized peristalsis appears appropriate. There were no focal lesions consistent with obstruction or a mass effect observed.

The ileocecal junction was visualized and exhibited normal intact wall layering and is subjectively of normal thickness. Sections of colon are visualized with formed fecal material and gas shadowing distally. There is no observed focal or generalized colon wall thickening or loss of layering.

Pancreas

The area of the pancreas is normal and isoechoic to surrounding mesentery. There is no evidence of nodules or cystic lesions. There is no evidence of regional mesenteric inflammation or fluid.

Free Abdomen

Evaluation of the peritoneal cavity did not reveal any evidence of effusion, or subjective lymphadenomegaly. The Medial iliac nodes appear normal and there was no evidence of a caudal aortic thrombus at the bifurcation. The omentum is of normal uniform echogenicity.

ULTRASONOGRAPHIC FINDINGS

- Echogenic debris in the urinary bladder – The echogenic debris in the bladder lumen could be consistent with cells, crystals, and/or mucus.
- Prominent muscularis layer of the small intestine – The small intestinal wall changes are most consistent with an inflammatory process (i.e., inflammatory bowel disease) with a low possibility of emerging lymphoma.
- Prominent, mildly dilated common bile duct – Dilation of the common bile duct could be consistent with a functional obstruction (i.e. primary hepatic disease resulting in hepatocellular swelling) or with an extrahepatic bile duct obstruction (ie. choledocholith, bile duct tumor, pancreatic disease, other).

INTERPRETATION OF THE FINDINGS & FURTHER RECOMMENDATIONS

No focal mass lesions were observed on today's scan. The small intestine appears somewhat "ropey" with a prominent muscularis layer. This can be seen in some normal older cats or with some cats with inflammatory type disease. Additionally, there is some mild debris visualized in the urinary bladder, and the bile duct is mildly dilated, but no obvious obstruction is visualized.

Considerations for possible evaluation of underlying gastrointestinal disease could include:

- Consider a GI panel to Texas A&M with a qualitative fPLI, TLI, cobalamin and folate to further evaluate the pancreas and small intestine.
- Consider a hydrolyzed protein/novel protein prescription diet.



PATIENT

Baby Toes Taylor

- Consider chronic probiotic therapy.
- Recommend 3-view thoracic radiographs to look for concurrent intrathoracic disease.
- If GI signs persist despite a diet change and controlling hyperthyroidism, then consider obtaining GI biopsies.

SPECIES

Feline

BREED

DSH

SEX

Spayed Female

AGE

12 Years

WEIGHT

12.8 Pounds

INTERPRETED BY

Kathleen Sennello DVM,
MS, Diplomate ACVIM
(Small Animal Internal
Medicine)

**IMAGING
PERFORMED BY**

Dr. Desen Ertunc

HOSPITAL NAME

Healing Spirit

REFERRING VET

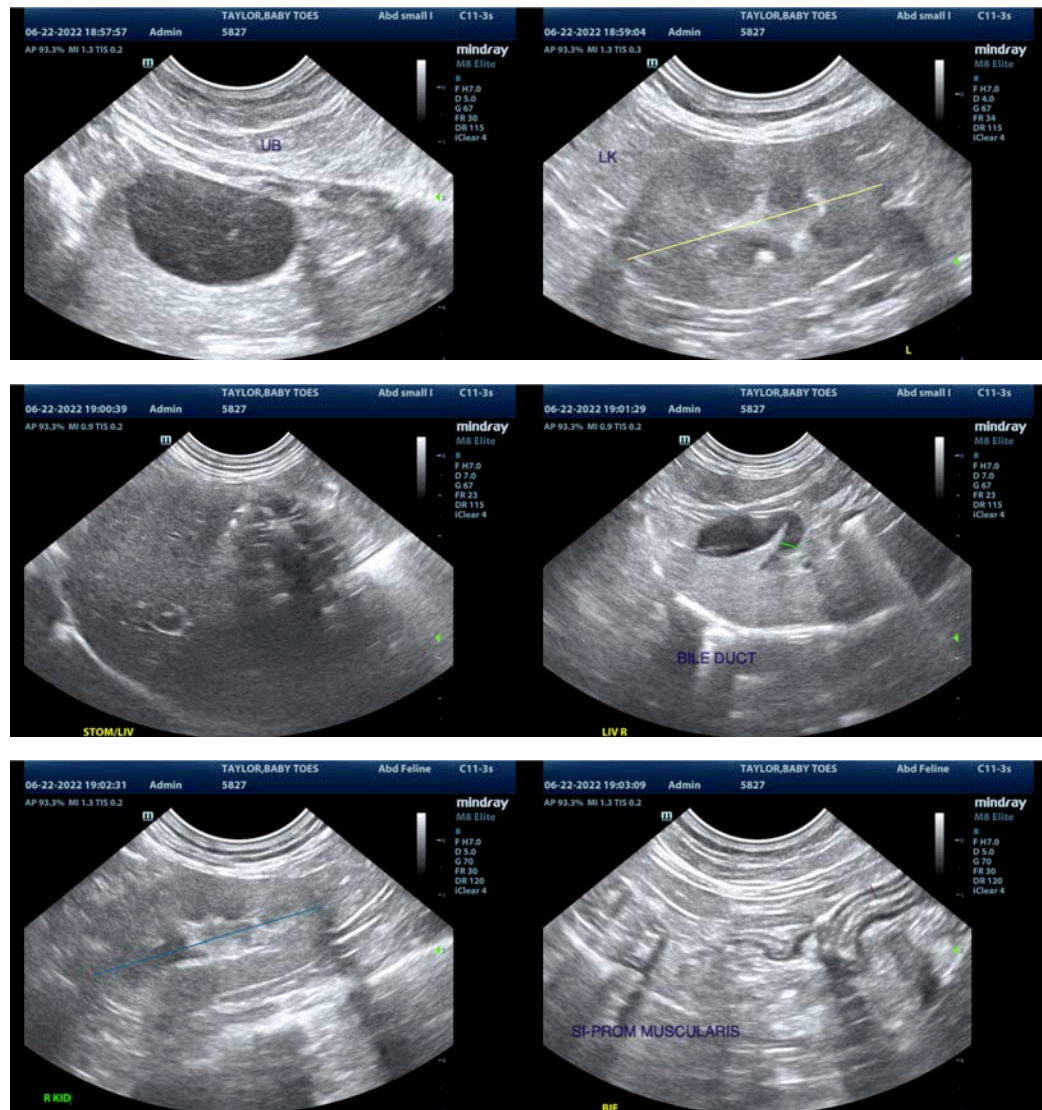
Dr. Desen Ertunc

INVOICE

39446

DATE

7/12/22





PATIENT

Baby Toes Taylor

SPECIES

Feline

BREED

DSH

SEX

Spayed Female

AGE

12 Years

WEIGHT

12.8 Pounds

INTERPRETED BY

Kathleen Sennello DVM,
MS, Diplomate ACVIM
(Small Animal Internal
Medicine)

**IMAGING
PERFORMED BY**

Dr. Desen Ertunc

HOSPITAL NAME

Healing Spirit

REFERRING VET

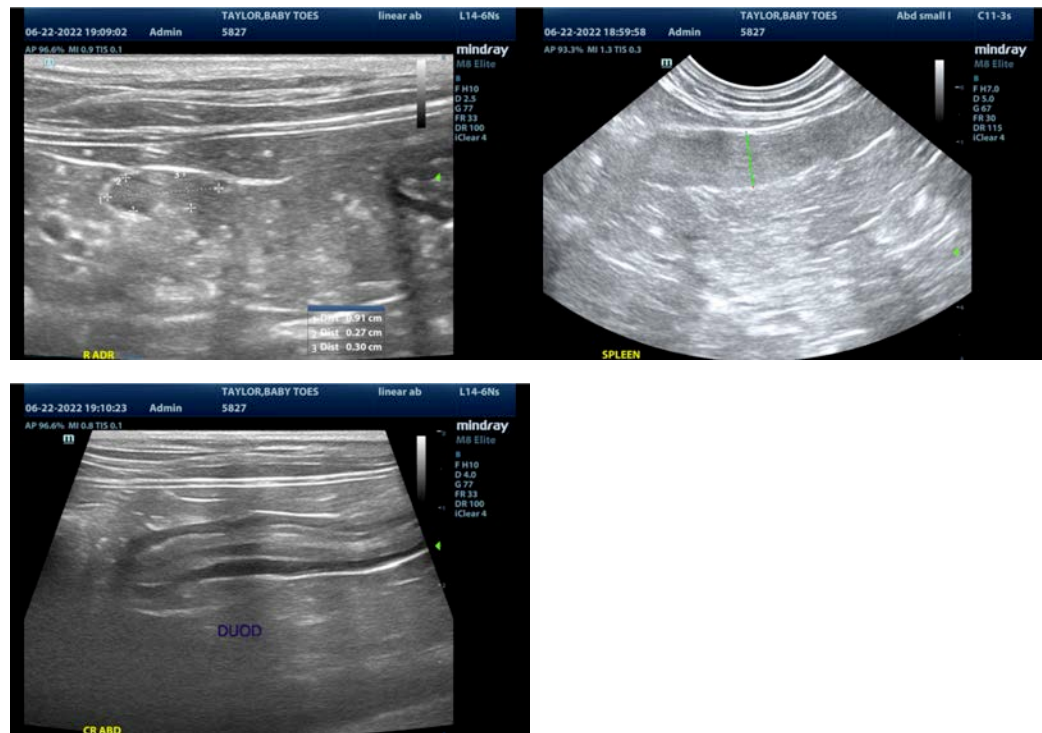
Dr. Desen Ertunc

INVOICE

39446

DATE

7/12/22



The information and recommendations provided are based on the images presented by the referring veterinarian/sonographer. No evaluation can be communicated regarding pathology that was not visible in the image/video clips provided.

Thank you for this referral. If the clinical or image interpretation does not parallel your findings or if I can be of any further assistance please contact me.

Kathleen Sennello DVM, MS, Diplomate ACVIM (Small animal Internal Medicine)

kathleen.sennello@sonopath.com