

PATIENT PRESENTING CLINICAL SIGNS

Bowser Skaggs
No sedation- Bowser was diagnosed with a Cutaneous Mast Cell Tumor on 4/8/2022. Bowser has abdominal ultrasound performed every 6 months to rule out metastatic lesions in the abdomen. Bowser was diagnosed with a grade 5/6 left sided systolic heart murmur on 12/27/2022. He gets an echocardiogram performed every 6 months to monitor for progression of heart disease. Doing well-

SPECIES

Canine

BREED

Pit Bull x Mastiff

SEX

Neutered Male

AGE

6 Years 11 Months

WEIGHT

40.37 kg

INTERPRETED BY

Kathleen Sennello DVM,
MS, Diplomate ACVIM
(Small Animal Internal
Medicine)

IMAGING PERFORMED BY

Loetitia Saint-Jacques,
LVT

HOSPITAL NAME

VCA Lakeside AH

REFERRING VET

Dr. Adam Gonzalez

INVOICE

43913

DATE

7/11/23

ULTRASONOGRAPHIC EXAMINATION OF THE ABDOMEN

Urinary System

The urinary bladder is moderately distended with anechoic urine. The Bladder wall, trigone, ureteral papillae and visible urethra (to a depth of 2cm) appear normal with no evidence of wall thickening, mucosal irregularities, masses or cystic calculi.

The prostate is normal in size (1.5 cm) and shape for this neutered male dog. The parenchyma is homogenous and the external margins are smooth. The prostatic urethra appears normal with no evidence of irregularity, invasion, mass effect or calculi.

The left kidney has a normal shape and size (7.33 cm). Overall echogenicity is normal with adequate corticomedullary distinction and a typical 1:3 cortex:medulla ratio. There is no evidence of focal perinephric inflammation or effusion. There is no evidence of pyelectasia, nephroliths, infarcts or hydroureter. Renal vasculature is normal.

The right kidney has a normal shape and size (7.54 cm) with a large cortical cyst in the caudal pole measuring 1.8 cm x 2.03 cm. Overall echogenicity is normal with adequate corticomedullary distinction and a typical 1:3 cortex:medulla ratio. There is no evidence of focal perinephric inflammation or effusion. There is no evidence of pyelectasia, nephroliths, infarcts or hydroureter. Renal vasculature is normal.

Adrenal Glands

The left adrenal gland is normal in size measuring 0.73 cm at the caudal pole. It is observed in its normal position cranial to the left renal artery. It is normal in appearance (uniformly hypoechoic) and shape with no evidence of a mass effect.

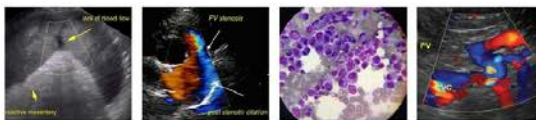
The right adrenal gland is normal in size measuring 0.65 cm at the caudal pole. It is observed in its normal position between the cranial aspect of the right kidney and the caudal vena cava. It is normal in appearance (uniformly hypoechoic) and shape with no evidence of a mass effect.

Spleen

The spleen is subjectively normal in size, echotexture is homogenous, and the splenic capsule is smooth with no irregularities. The blood flow through the hilus and splenic parenchyma appears normal. No focal parenchymal abnormalities are visualized.

Liver

The liver is subjectively normal in size, and echogenicity with smooth peripheral margins. The parenchyma is homogenous echotexture. The visible portions of the vasculature and biliary tract appear normal. No focal nodules or cystic lesions are observed.



PATIENT

Bowser Skaggs

The gallbladder lumen is moderately distended. The wall of the gall bladder is not thickened and has a smooth mucosal surface. Luminal contents are mild and primarily anechoic. The cystic and common bile ducts are normal/not visible.

SPECIES

Canine

Gastrointestinal

The stomach contains a large amount of ingesta. It measures at a normal thickness of <0.7cm with some variability due to the presence of rugal folds. The distinction of the gastric wall layers is adequate and there is no impression of reduced peristaltic activity. No masses or focal lesions were observed.

BREED

Pit Bull x Mastiff

The visualized areas of duodenum, jejunum and ileum have a relatively uniform diameter with minimal fluid distension. Wall thickness is normal. Bowel loops follow a curvilinear path with distinct wall layering maintaining the typical 1:3 muscularis:mucosa layer ratio. The duodenum measured as normal (between 0.3-0.5cm in wall thickness) and the jejunum measured as normal (between 0.2-0.47cm.)

SEX

Neutered Male

Visualized peristalsis appears appropriate. There were no focal lesions consistent with obstruction or a mass effect observed.

AGE

6 Years 11 Months

The ileocecal junction was visualized and exhibited normal intact wall layering and is subjectively of normal thickness. Sections of colon are visualized with formed fecal material and gas shadowing distally. There is no observed focal or generalized colon wall thickening or loss of layering.

WEIGHT

40.37 kg

Pancreas

The pancreas is normal and isoechoic to surrounding mesentery. There is no evidence of nodules or cystic lesions. There is no evidence of regional mesenteric inflammation or fluid.

INTERPRETED BY

Kathleen Sennello DVM,
MS, Diplomate ACVIM
(Small Animal Internal
Medicine)

Free Abdomen

Evaluation of the peritoneal cavity did not reveal any evidence of effusion. There is no evidence of a significant lymphadenopathy. The left sublumbar lymph node measures at 0.78 cm, the right at 0.48 cm. The omentum is of normal echogenicity.

IMAGING PERFORMED BY

Loetitia Saint-Jacques,
LVT

ULTRASONOGRAPHIC FINDINGS

- Renal cyst visualized in the caudal pole of the right kidney

INTERPRETATION OF THE FINDINGS & FURTHER RECOMMENDATIONS

Today's scan is relatively normal and stable from the previous scan on 1/4/23. There is no evidence of any focal lesions in the liver or spleen, and no lymphadenopathy is noted.

HOSPITAL NAME

VCA Lakeside AH

REFERRING VET

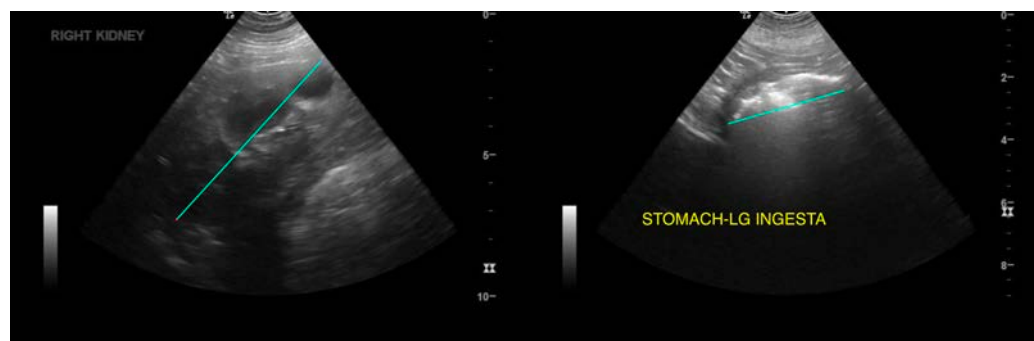
Dr. Adam Gonzalez

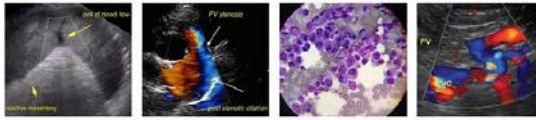
INVOICE

43913

DATE

7/11/23





PATIENT

Bowser Skaggs

SPECIES

Canine

BREED

Pit Bull x Mastiff

SEX

Neutered Male

AGE

6 Years 11 Months

WEIGHT

40.37 kg

INTERPRETED BY

Kathleen Sennello DVM,
MS, Diplomate ACVIM
(Small Animal Internal
Medicine)

IMAGING PERFORMED BY

Loetitia Saint-Jacques,
LVT

HOSPITAL NAME

VCA Lakeside AH

REFERRING VET

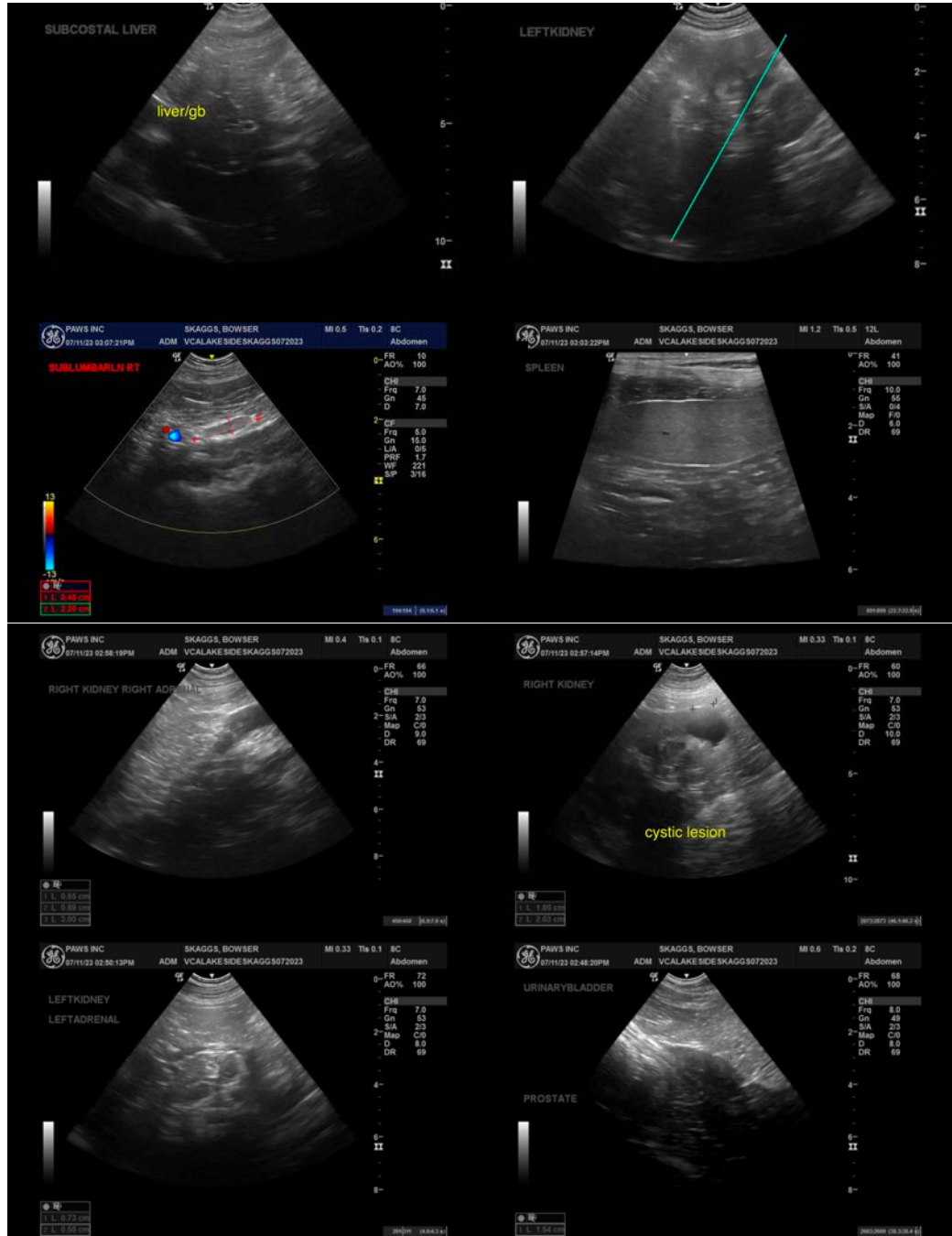
Dr. Adam Gonzalez

INVOICE

43913

DATE

7/11/23





PATIENT

Bowser Skaggs

The information and recommendations provided are based on the images presented by the referring veterinarian/sonographer. No evaluation can be communicated regarding pathology that was not visible in the image/video clips provided.

SPECIES

Canine

Thank you for this referral. If the clinical or image interpretation does not parallel your findings or if I can be of any further assistance please contact me.

BREED

Pit Bull x Mastiff

Kathleen Sennello DVM,MS, Diplomate ACVIM (Small animal Internal Medicine)

info@sonopath.com

SEX

Neutered Male

AGE

6 Years 11 Months

WEIGHT

40.37 kg

INTERPRETED BY

Kathleen Sennello DVM,
MS, Diplomate ACVIM
(Small Animal Internal
Medicine)

**IMAGING
PERFORMED BY**

Loetitia Saint-Jacques,
LVT

HOSPITAL NAME

VCA Lakeside AH

REFERRING VET

Dr. Adam Gonzalez

INVOICE

43913

DATE

7/11/23