

**DATE PRESENTING CLINICAL SIGNS**

6/9/22

Owner states that he has a history of intermittent diarrhea - will have "red, jelly-like" stool roughly every couple of months, going on about 6mo, but at least a year hx of occasional/intermittent soft stool/diarrhea and/or vomiting. O states GI issues are inconsistent, and she has been unable to link to an inciting cause. PE 4/26/22 was unremarkable, save for weight loss since Dec. (64lbs down to 58.6lbs); per o she thinks it was more pronounced, but he put some weight back on. He was not on a weight loss diet regimen.

**PATIENT**

Rocco Barsy

**SPECIES**

Canine

**BREED**

Rottweiler X

Current Medications: Intermittent Metronidazole, 10mg/kg BID x 5d (none recently); o will occasionally give Tums and/or Pepto Bismol. Will be on Trazodone 10mg/kg and Gabapentin 20mg/kg morning of.  
 Lab Results: Labwork and fecal 4/26 unremarkable.  
 Date of Previous IntraPet Ultrasound: No previous.  
 Sedation: Not required to complete full diagnostic ultrasound.  
 Stat Report: Not requested.

**ULTRASONOGRAPHIC EXAMINATION OF THE ABDOMEN****SEX**

Neutered Male

**Urinary System**

The urinary bladder is moderately distended with anechoic urine. The Bladder wall, trigone, ureteral papillae and visible urethra (to a depth of 2cm) appear normal with no evidence of wall thickening, mucosal irregularities, masses or cystic calculi.

**AGE**

3/10/14

The prostate is normal in size (1.13 cm) and shape for this neutered male dog. The parenchyma is homogenous and the external margins are smooth. The prostatic urethra appears normal with no evidence of irregularity, invasion, mass effect or calculi.

**WEIGHT**

58.6 Pounds

The left kidney has a normal shape and size (6.54 cm). Overall echogenicity is normal with adequate corticomedullary distinction and a typical 1:3 cortex:medulla ratio. There is no evidence of perinephric inflammation or effusion. There is no evidence of pyelectasia, nephroliths, infarcts or hydroureter. Renal vasculature is normal.

**INTERPRETED BY**

Kathleen Sennello DVM,  
MS, Diplomate ACVIM  
(Small Animal Internal  
Medicine)

The right kidney has a normal shape and size (6.3 cm). Overall echogenicity is normal with adequate corticomedullary distinction and a typical 1:3 cortex:medulla ratio. There is no evidence of perinephric inflammation or effusion. There is no evidence of pyelectasia, nephroliths, infarcts or hydroureter. Renal vasculature is normal.

**IMAGING PERFORMED BY**

Andi Parkinson RDMS

**Adrenal Glands**

The left adrenal gland is normal in size measuring 0.75 cm at the caudal pole. It is observed in its normal position cranial to the left renal artery. It is normal in appearance (uniformly hypoechoic) and shape with no evidence of a mass effect.

**HOSPITAL NAME**

Banfield Columbia

The right adrenal gland is normal in size measuring 0.74 cm at the caudal pole. It is observed in its normal position between the cranial aspect of the right kidney and the caudal vena cava. It is normal in appearance (uniformly hypoechoic) and shape with no evidence of a mass effect.

**REFERRING VET**

Dr. Scherping

**Spleen**

The spleen is subjectively normal in size, echotexture is homogenous, and the splenic capsule is smooth with no irregularities. The blood flow through the hilus and splenic parenchyma appears normal. No focal parenchymal abnormalities are visualized.

**INVOICE**

38580

### ***Liver***

The liver is subjectively normal in size, and echogenicity with smooth peripheral margins. The parenchyma is homogenous echotexture. The visible portions of the vasculature and biliary tract appear normal. No focal nodules or cystic lesions are observed.

The gallbladder lumen is moderately distended. The wall of the gall bladder is not thickened and has a smooth mucosal surface. Luminal contents are primarily anechoic. The cystic and common bile ducts are normal/not visible.

### ***Gastrointestinal***

The stomach is dilated with a large amount of fluid and irregular shadowing material most consistent with normal ingesta and gas. It measures at a normal thickness of <0.7cm with some variability due to the presence of rugal folds. The distinction of the gastric wall layering is adequate and there is no impression of reduced peristaltic activity. No masses or focal lesions were observed.

Some of the visualized areas of duodenum, jejunum and ileum have a relatively uniform diameter with minimal fluid distension. Many areas have moderate to significant distention with chyme/ingesta. Wall thickness largely appears normal. Bowel loops follow a curvilinear path with distinct wall layering maintaining the typical 1:3 muscularis:mucosa layer ratio. Duodenum measures as normal between 0.3-0.5 cm in wall thickness, and the jejunum measures as normal at 0.39 cm. Visualized peristalsis appears appropriate. Complete evaluation of the small bowel was hindered due to distention with shadowing chyme and ingesta. No focal mass effect was observed.

The ileocecal junction was visualized and exhibited normal intact wall layering and is subjectively of normal thickness. Sections of colon are visualized with formed fecal material and gas shadowing distally. There is no observed focal or generalized colon wall thickening or loss of layering.

### ***Pancreas***

The pancreas is normal and isoechoic to surrounding mesentery. There is no evidence of nodules or cystic lesions. There is no evidence of regional mesenteric inflammation or fluid.

### ***Free Abdomen***

Evaluation of the peritoneal cavity did not reveal any evidence of effusion, or subjective lymphadenomegaly. The Medial iliac nodes appear normal and there was no evidence of a caudal aortic thrombus at the bifurcation. The omentum is of normal uniform echogenicity.

## **ULTRASONOGRAPHIC FINDINGS**

- Moderate shadowing ingesta within the gastric lumen and fluid distention/chyme within the small intestine – Based on the history, these findings are consistent with a recent meal. Shadowing contents within the gastrointestinal tract hinders evaluation of the deeper structures and evaluation of wall layering, etc.

## **INTERPRETATION OF THE FINDINGS & FURTHER RECOMMENDATIONS**

No significant lesions were observed on today's scan. Unfortunately, there are many causes for colitis/gastroenteritis that cannot be definitively diagnosed by ultrasound alone.

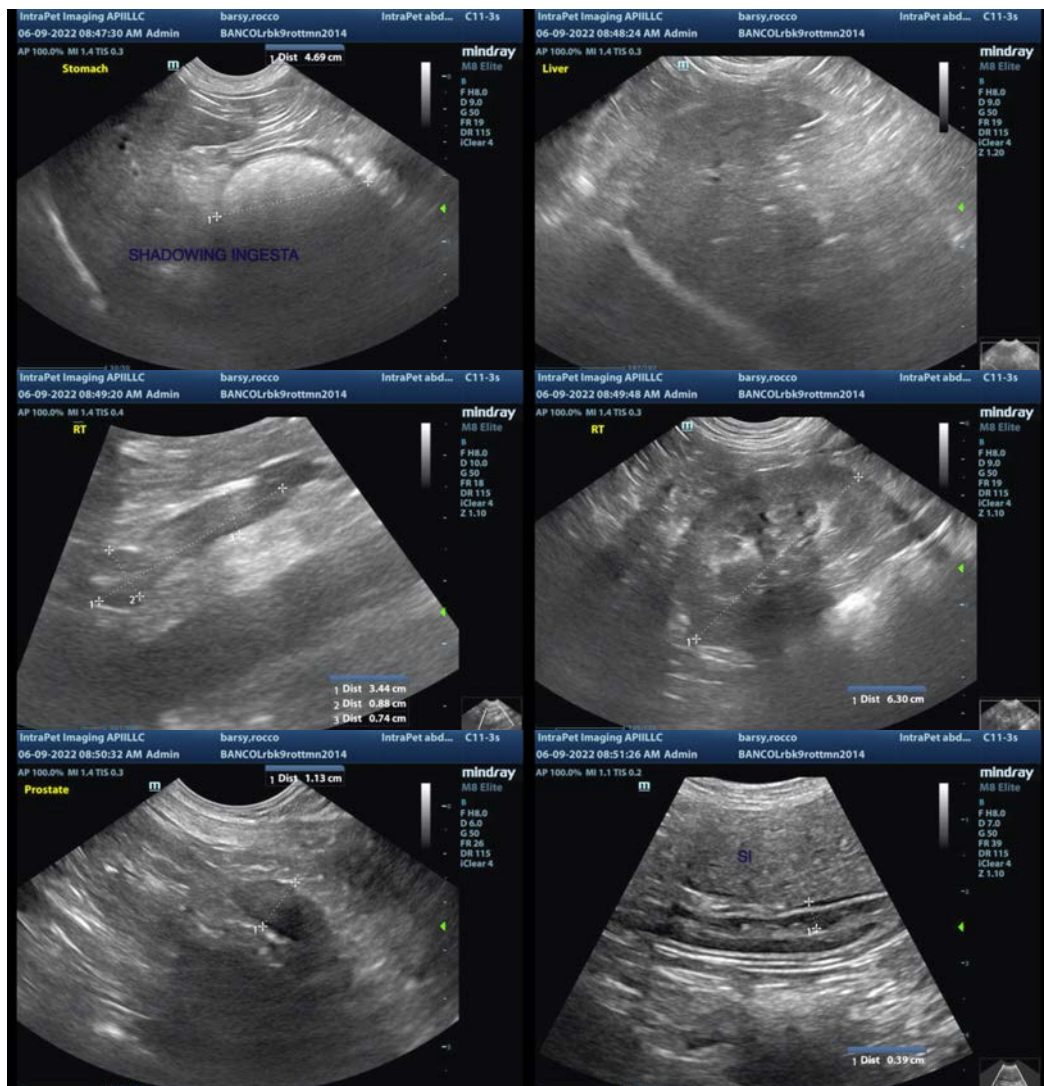
Consider metabolic causes for intermittent gastroenteritis. If baseline bloodwork is normal, consider screening for Addison's disease with a baseline cortisol.

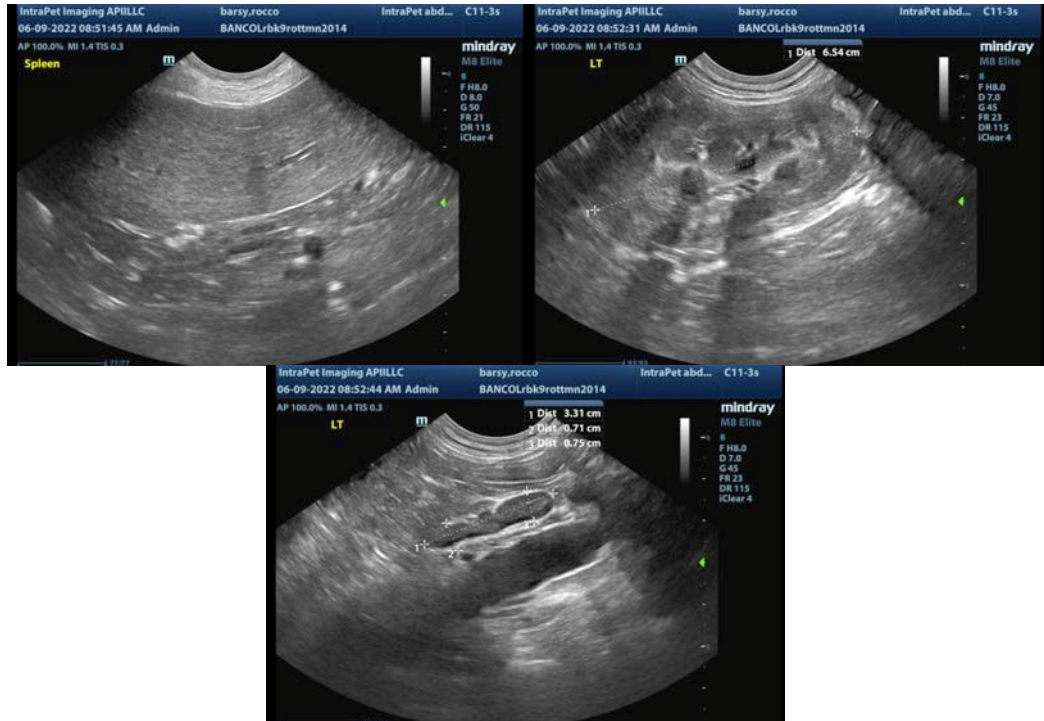If metabolic disease is thought unlikely based on test results, then consider primary gastrointestinal causes for large and small bowel diarrhea. These would include dietary intolerance/food allergy, GI parasitism,

dysbiosis, dietary indiscretion, pancreatitis, IBD, and less likely intestinal neoplasia.

- Consider a novel protein/hydrolyzed protein prescription diet.
- Consider chronic probiotic therapy.
- Recommend testing and empirical treatment for GI parasites (if not already done).
- Consider GI panel to Texas A&M for a qualitative PLI, TLI, cobalamin and folate to evaluate for dysbiosis, exocrine pancreatic insufficiency, B12 deficiency, etc.

If there is no response to dietary therapy, then considered obtaining biopsies of the large and small intestine.





The information and recommendations provided are based on the images presented by the referring veterinarian/sonographer. No evaluation can be communicated regarding pathology that was not visible in the image/video clips provided.

Thank you for this referral. If the clinical or image interpretation does not parallel your findings or if I can be of any further assistance please contact me.

Kathleen Sennello DVM,MS, Diplomate ACVIM (Small animal Internal Medicine)  
kathleen.sennello@sonopath.com