SonoPath
Clinical Sonography & Telecytology

EDUCATIONAL TELECONSULTATION SERVICES™

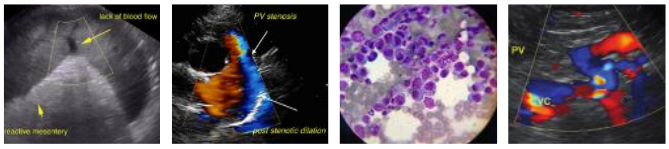

SonoPath.com™
1-800-838-4268 info@sonopath.com

PATIENT
Zoey Trevillian

SPECIES
Canine

BREED
Boston Terrier

SEX
Spayed Female

AGE
9 Years

WEIGHT
18 Pounds

INTERPRETED BY
Kathleen Sennello DVM, MS, Diplomate ACVIM (Small Animal Internal Medicine)

IMAGING PERFORMED BY
Amy Mayhew, LVT

HOSPITAL NAME
SVS Imging MI

REFERRING VET
Oxford VH

INVOICE
15951

DATE
6/9/22

PRESENTING CLINICAL SIGNS

History: Patient presented for blood work. No symptoms

Abnormal PE/Chem/CBC/UA Results: Increased ALT 3/4/22 was 143 & 5/11/22 was 137 **please see attached labs

ULTRASONOGRAPHIC EXAMINATION OF THE ABDOMEN

Urinary System

The urinary bladder is moderately distended with anechoic urine. The Bladder wall, trigone, ureteral papillae and visible urethra (to a depth of 2 cm) appear normal with no evidence of wall thickening, mucosal irregularities, masses or cystic calculi.

The left kidney has a normal shape and size (4.08 cm). Overall echogenicity is normal with adequate corticomedullary distinction and a typical 1:3 cortex:medulla ratio. There is no evidence of perinephric inflammation or effusion. There is no evidence of pyelectasia, nephroliths, infarcts or hydroureter. Renal vasculature is normal.

The right kidney has a normal shape and size (4.51 cm). Overall echogenicity is normal with adequate corticomedullary distinction and a typical 1:3 cortex:medulla ratio. There is no evidence of perinephric inflammation or effusion. There is no evidence of pyelectasia, nephroliths, infarcts or hydroureter. Renal vasculature is normal.

Adrenal Glands

The left adrenal gland is normal in size measuring 0.67cm at the caudal pole. It is observed in its normal position cranial to the left renal artery. It is normal in appearance (uniformly hypoechoic) and shape with no evidence of a mass effect.

The right adrenal gland is normal in size measuring 0.51 cm at the caudal pole. It is observed in its normal position between the cranial aspect of the right kidney and the caudal vena cava. It is normal in appearance (uniformly hypoechoic) and shape with no evidence of a mass effect.

Spleen

The spleen is subjectively normal in size, echotexture is homogenous, and the splenic capsule is smooth with no irregularities. The blood flow through the hilus and splenic parenchyma appears normal. No focal parenchymal abnormalities are visualized.

Liver

The liver is subjectively large in size, and echogenicity with smooth peripheral margins. The parenchyma is heterogenous in echotexture with subtle, indistinct focal mottling. The visible portions of the vasculature and biliary tract appear normal. No focal nodules or cystic lesions are observed

The gall bladder lumen is moderately distended. The wall of the gall bladder is not thickened and has a smooth mucosal surface. There is a moderate/large amount of non-organized echogenic debris. The cystic and common bile ducts are normal/not visible.

Gastrointestinal

The stomach contains moderate fluid. It measures at a normal thickness of <0.7 cm with some variability due to the presence of rugal folds. The distinction of the gastric wall layers is adequate and there is no impression of reduced peristaltic activity. No masses or focal lesions were observed.

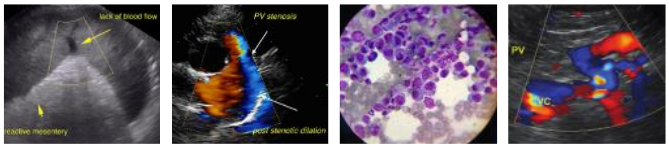

SonoPath.com™
1-800-838-4268 info@sonopath.com

PATIENT

Zoey Trevillian

SPECIES

Canine

BREED

Boston Terrier

SEX

Spayed Female

AGE

9 Years

WEIGHT

18 Pounds

INTERPRETED BY

Kathleen Sennello DVM, MS, Diplomate ACVIM (Small Animal Internal Medicine)

IMAGING PERFORMED BY

Amy Mayhew, LVT

HOSPITAL NAME

SVS Imging MI

REFERRING VET

Oxford VH

INVOICE

15951

DATE

6/9/22

The visualized areas of duodenum, jejunum and ileum have a relatively uniform diameter with minimal fluid distension. Wall thickness is normal. Bowel loops follow a curvilinear path with distinct wall layering maintaining the typical 1:3 muscularis:mucosa layer ratio. The duodenum measured as normal (between 00.49 in wall thickness) and the jejunum measured as normal (between 0.39 cm) Visualized peristalsis appears appropriate. There were no focal lesions consistent with obstruction or a mass effect observed. Mild mucosal fogging was noted in the duodenum.

The ileocecal junction was visualized and exhibited normal intact wall layering and is subjectively of normal thickness. Sections of colon are visualized with formed fecal material and gas shadowing distally. There is no observed focal or generalized colon wall thickening or loss of layering.

Pancreas

The pancreas is prominent and mildly mottled compared to the surrounding isoechoic mesentery. There is no evidence of nodules or cystic lesions. There is no evidence of regional mesenteric inflammation or fluid.

Free Abdomen

Evaluation of the peritoneal cavity did not reveal any evidence of effusion, or subjective lymphadenomegaly. The Medial iliac nodes appear normal and there was no evidence of a caudal aortic thrombus at the bifurcation. The omentum is of normal uniform echogenicity.

ULTRASONOGRAPHIC FINDINGS

Primary Findings

- Large heterogeneous liver. The diffuse hepatic changes are non-specific and could be consistent with vacuolar hepatopathy, nodular hyperplasia, inflammatory/immune-mediated disease, fibrosis, extramedullary hematopoiesis, toxic hepatopathy (e.g., copper), infiltrative neoplasia (less likely) or other hepatopathy.
- Moderate to large gallbladder debris. The significance of the aggregated gallbladder debris is unclear. This could represent an early mucocele, cholestasis, or may be secondary to fasting.
- The stomach has moderate fluid distention. Correlate with feeding and eating history. If the patient was adequately fasted, then consider such differentials as delayed gastric emptying or partial outflow tract obstruction (none observed).
- Prominent small intestine with mild duodenal mucosal fogging. The mild small intestinal wall changes may be a normal variant in this patient or could be consistent with an inflammatory process (e.g., inflammatory bowel disease).

Secondary Findings

- Mildly mottled pancreas. The pancreatic changes are most consistent with age-related parenchymal remodeling, potentially secondary to a prior inflammatory episode, early fibrosis or chronic pancreatitis.

INTERPRETATION OF THE FINDINGS & FURTHER RECOMMENDATIONS

No focal lesions are visualized associated with the liver. There is a moderate amount of adhered debris within the gallbladder. Given there is no significant elevation in ALP, this could continue to be monitored or you could consider prophylactic ursodiol. The liver enzyme elevations are relatively mild.

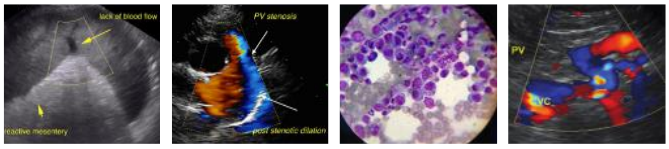

SonoPath.com™
1-800-838-4268 info@sonopath.com

PATIENT

Zoey Trevillian

SPECIES

Canine

BREED

Boston Terrier

SEX

Spayed Female

AGE

9 Years

WEIGHT

18 Pounds

INTERPRETED BY

Kathleen Sennello DVM, MS, Diplomate ACVIM (Small Animal Internal Medicine)

IMAGING PERFORMED BY

Amy Mayhew, LVT

HOSPITAL NAME

SVS Imging MI

REFERRING VET

Oxford VH

INVOICE

15951

DATE

6/9/22

These types of elevations can be due to primary liver disease or even can be associated with gastrointestinal disease. In general, these are my recommendations for further work up of a liver enzyme elevation, if desired.

- Consider close evaluation of history for possible toxic changes examine medications, diet, dietary indiscretion etc.
- Consider PCR on urine/serum for leptospirosis (if not on antibiotics)/serology if recent antibiotic history
- If not already done, consider pre and post prandial bile acids to evaluate liver function
- Consider Fine needle aspirate if round cell neoplasia is on your differentia list (25 g needle, normal coags)
- If no response to medical treatment (Denamarin, antibiotics,+/- ursodiol etc.) Consider liver biopsy with samples obtained for histopathology, culture, and copper levels.

The small intestinal changes observed are mild and of unknown significance. You could consider a GI panel (to Texas A & M) for a qualitative PLI, TLI, cobalamin and folate, to further evaluate the pancreas and small intestine. If there is additional evidence for underlying small intestinal disease, then this could be a contributing factor to the ALT elevation and things such as a novel protein/hydrolyzed protein diet, etc. may be considered.

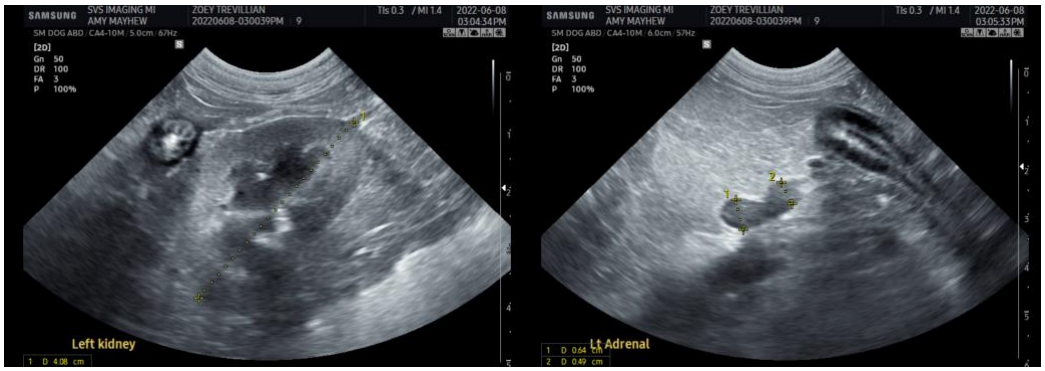

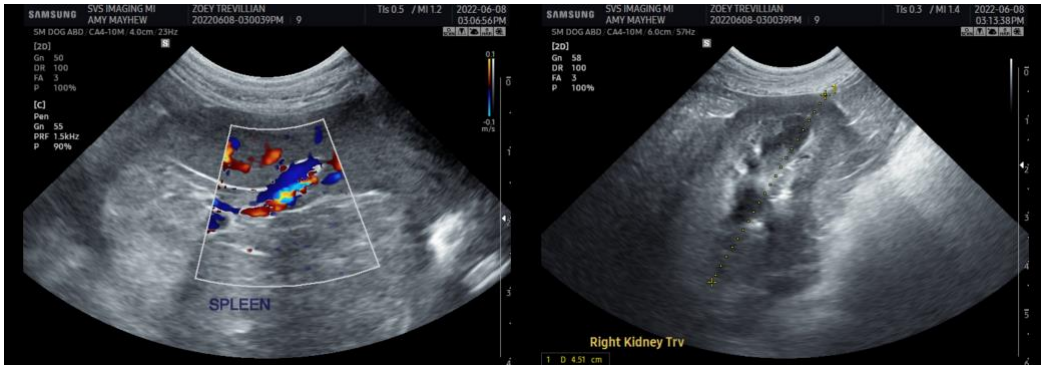

SonoPath

Clinical Sonography & Telecytology

EDUCATIONAL TELECONSULTATION SERVICES™

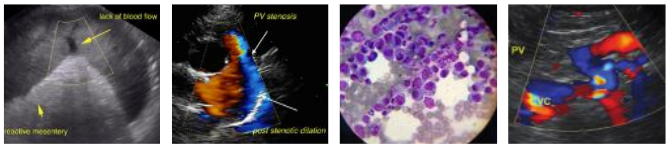

SonoPath.com™

1-800-838-4268 info@sonopath.com

PATIENT

Zoey Trevillian

SPECIES

Canine

BREED

Boston Terrier

SEX

Spayed Female

AGE

9 Years

WEIGHT

18 Pounds

INTERPRETED BY

Kathleen Sennello DVM, MS, Diplomate ACVIM (Small Animal Internal Medicine)

IMAGING PERFORMED BY

Amy Mayhew, LVT

HOSPITAL NAME

SVS Imging MI

REFERRING VET

Oxford VH

INVOICE

15951

DATE

6/9/22

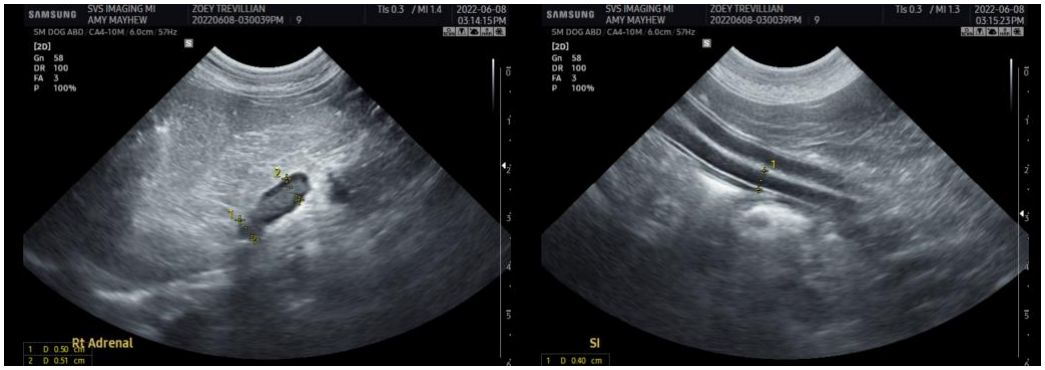

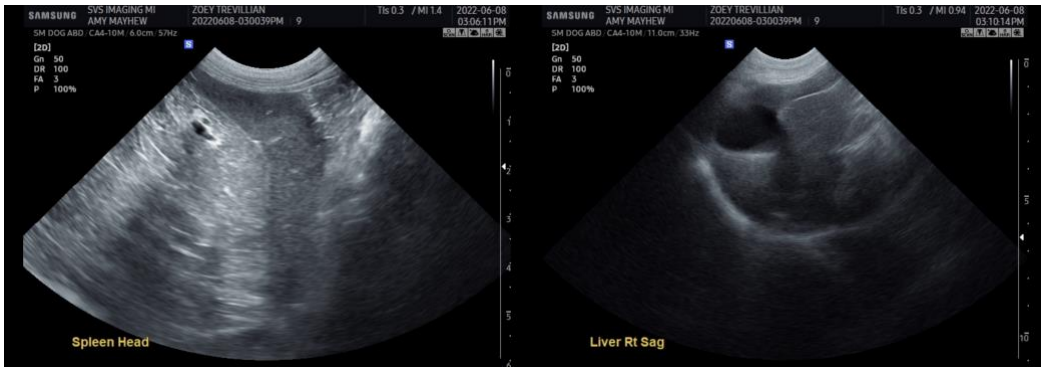

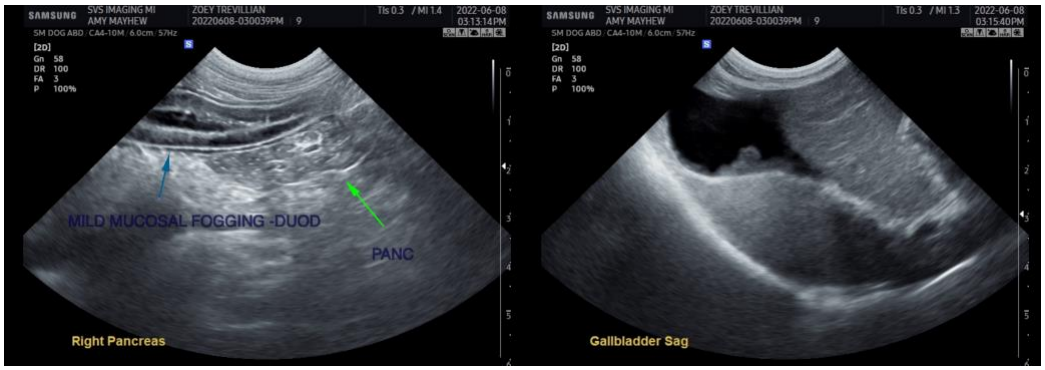

The information and recommendations provided are based on the images presented by the referring veterinarian. No evaluation can be communicated regarding pathology that was not visible in the image/video clips provided.

Thank you for this referral. If the clinical or image interpretation does not parallel your findings or if I can be of any further assistance please contact me.

Kathleen Sennello DVM,MS, Diplomate ACVIM (Small animal Internal Medicine)
kathleen.sennello@sonopath.com