SonoPath
Clinical Sonography & Telecytology

EDUCATIONAL TELECONSULTATION SERVICES™

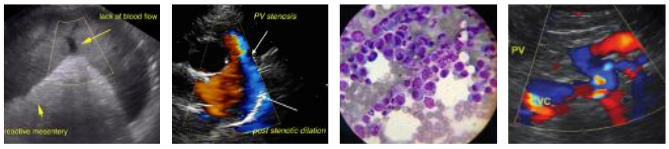

SonoPath.com™
1-800-838-4268 info@sonopath.com

PATIENT

Queenie Kaufled

SPECIES

Feline

BREED

Suberian

SEX

Spayed Female

AGE

17 Years

WEIGHT

14.2 Pounds

INTERPRETED BY

Kathleen Sennello DVM, MS, Diplomate ACVIM (Small Animal Internal Medicine)

IMAGING PERFORMED BY

Amy Mayhew, LVT

HOSPITAL NAME

SVS Imaging MI

REFERRING VET

Oxford VH

INVOICE

15954

DATE

6/8/22

PRESENTING CLINICAL SIGNS

History: Arthritis, Cardiomyopathy hypertrophic, IBD. Recent loss of appetite, dark stools.

Abnormal PE/Chem/CBC/UA Results: RBC 6.58, SDMA 18, however Creatinine normal at 1.8, low Albumin at 1.8 & Globulin 2.4, BG 113, Fructosamine 133

ULTRASONOGRAPHIC EXAMINATION OF THE ABDOMEN

Urinary System

The urinary bladder is moderately distended with anechoic urine. The Bladder wall, trigone, ureteral papillae and visible urethra (to a depth of 2 cm) appear normal with no evidence of wall thickening, mucosal irregularities, masses or cystic calculi.

The left kidney has a normal shape and size (3.3 cm). Overall echogenicity is slightly hyperechoic with poor corticomedullary distinction and a typical 1:3 cortex:medulla ratio. There is no evidence of perinephric inflammation or effusion. There is no evidence of pyelectasia, nephroliths, infarcts or hydroureter. Renal vasculature is normal.

The right kidney has a normal shape and size (3.74 cm). Overall echogenicity is slightly hyperechoic with poor corticomedullary distinction and a typical 1:3 cortex:medulla ratio. There is no evidence of perinephric inflammation or effusion. There is no evidence of pyelectasia, nephroliths, infarcts or hydroureter. Renal vasculature is normal.

Adrenal Glands

The left adrenal gland is normal in size measuring 0.37 cm at the caudal pole. It is observed in its normal position cranial to the left renal artery. It is normal in appearance (uniformly hypoechoic) and shape with no evidence of a mass effect.

The right adrenal gland is normal in size measuring 0.35 cm at the caudal pole. It is observed in its normal position between the cranial aspect of the right kidney and the caudal vena cava. It is normal in appearance (uniformly hypoechoic) and shape with no evidence of a mass effect.

Spleen

The spleen is subjectively normal in size, echotexture is homogenous, and the splenic capsule is smooth with no irregularities. The blood flow through the hilus and splenic parenchyma appears normal. No focal parenchymal abnormalities are visualized.

Liver

The liver is subjectively large in size, and echogenicity with smooth peripheral margins. The parenchyma is heterogenous in echotexture with subtle, indistinct focal mottling. The visible portions of the vasculature and biliary tract appear normal. No focal nodules or cystic lesions are observed.

The gall bladder lumen is moderately distended. The wall of the gall bladder is not thickened and has a smooth mucosal surface. Luminal contents are primarily anechoic. The cystic and common bile ducts appear somewhat prominent and tortuous, measuring at 0.26 cm.

Gastrointestinal

The stomach contains minimal luminal contents. It measures at a normal thickness of <0.36cm with some variability due to the presence of rugal folds. The distinction of the gastric wall layers is

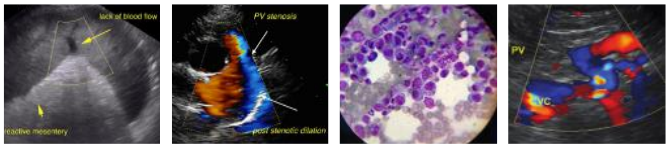

SonoPath.com™
1-800-838-4268 info@sonopath.com

PATIENT

Queenie Kaufled

SPECIES

Feline

BREED

Suberian

SEX

Spayed Female

AGE

17 Years

WEIGHT

14.2 Pounds

INTERPRETED BY

Kathleen Sennello DVM, MS, Diplomate ACVIM (Small Animal Internal Medicine)

IMAGING PERFORMED BY

Amy Mayhew, LVT

HOSPITAL NAME

SVS Imaging MI

REFERRING VET

Oxford VH

INVOICE

15954

DATE

6/8/22

adequate and there is no impression of reduced peristaltic activity. No masses or focal lesions were observed.

The visualized areas of duodenum, jejunum and ileum have a uniform diameter with minimal fluid distension. Wall thickness is normal to slightly increased. Bowel loops follow a typical curvilinear path with distinct wall layering, but some areas display a prominent muscularis layer which does not display the typical 1:3 muscularis:mucosa layer ratio. Visualized peristalsis appears appropriate.

There is a focal section of small intestine, which transitions into an area of severely thickened, hypoechoic wall with complete loss of layering. This measures approximately 1.49. cm in wall thickness and 2.87 cm in diameter and the mass effect extends for over 6.0 cm of bowel. This area of intestine is surrounded by hyperechoic mesentery.

The ileocecal junction was visualized and exhibited normal intact wall layering and is subjectively of normal thickness. Sections of colon are visualized with formed fecal material and gas shadowing distally. There is no observed focal or generalized colon wall thickening or loss of layering.

Pancreas

The pancreas is prominent and hypoechoic as compared to the surrounding isoechoic mesentery. There is no evidence of nodules or cystic lesions. There is no evidence of regional mesenteric inflammation or fluid.

Free Abdomen

There is a small amount of free abdominal fluid. There is a severe mesenteric lymphadenopathy with a lymph node visualized adjacent to the bowel mass, measuring 3.23 cm x 3.37 cm. The omentum is diffusely hyperechoic, particularly around the abnormal bowel and large lymph node.

ULTRASONOGRAPHIC FINDINGS

Primary Findings

- Focal area of small intestine with complete loss of layering and severe wall thickening. The findings are most consistent with a bowel mass. Round cell neoplasia would be of greatest concern.
- Severe mesenteric lymphadenopathy. The moderate/severe mesenteric lymphadenopathy is most concerning for a neoplastic process, although you can see significant lymphadenopathy in some cases of autoimmune/inflammatory disease, infectious disease(tick born disease-such as bartonella, fungal infections, FIP (cats)) etc. A fine needle aspirate with cytology is recommended for further evaluation.
- Heterogeneous liver. Hepatic changes are non-specific and could be consistent with inflammation/infection (cholangiohepatitis), infiltrative neoplasia, lipidosis or other hepatopathy.

Secondary Findings

- Decreased corticomedullary distinction in both kidneys. The bilateral renal findings are consistent with age-related change.

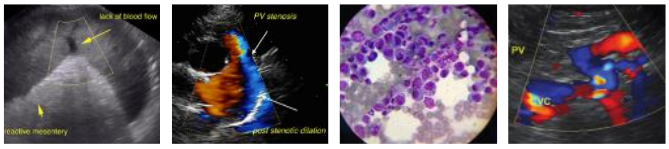

SonoPath.com™
1-800-838-4268 info@sonopath.com

PATIENT

Queenie Kaufled

SPECIES

Feline

BREED

Suberian

SEX

Spayed Female

AGE

17 Years

WEIGHT

14.2 Pounds

INTERPRETED BY

Kathleen Sennello DVM, MS, Diplomate ACVIM (Small Animal Internal Medicine)

IMAGING PERFORMED BY

Amy Mayhew, LVT

HOSPITAL NAME

SVS Imaging MI

REFERRING VET

Oxford VH

INVOICE

15954

DATE

6/8/22

- Prominent hypoechoic pancreas. The pancreatic changes are most consistent with age-related parenchymal remodeling, potentially secondary to a prior inflammatory episode, early fibrosis or chronic pancreatitis.
- Prominent bile duct. Dilation of the common bile duct could be consistent with a functional obstruction (i.e., primary hepatic disease resulting in hepatocellular swelling) or with an extrahepatic bile duct obstruction (i.e., choledocholith, bile duct tumor, pancreatic disease, other).

INTERPRETATION OF THE FINDINGS & FURTHER RECOMMENDATIONS

There is a large focal bowel mass with an associated severe mesenteric lymphadenopathy. Concern is high for round cell neoplasia or other neoplasm, although other differentials exist. I recommend a fine needle aspirate of the bowel wall and associated enlarged lymph node. I recommended three-view thoracic radiographs. If an answer cannot be obtained cytologically, I recommend exploratory surgery.

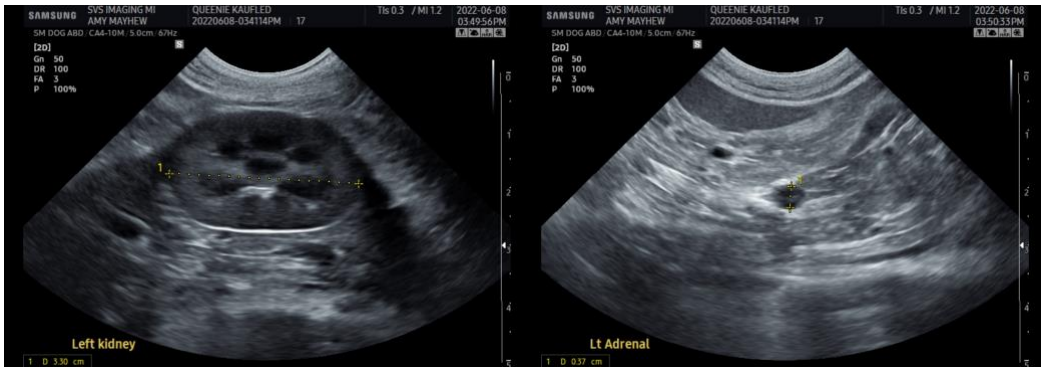

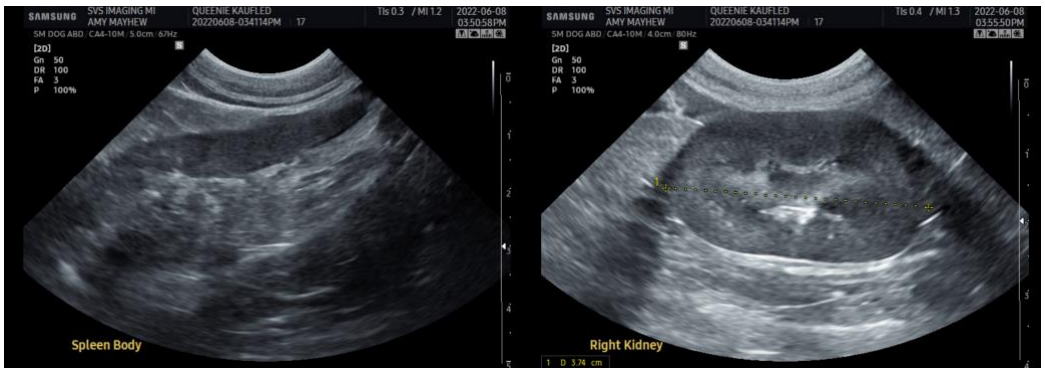

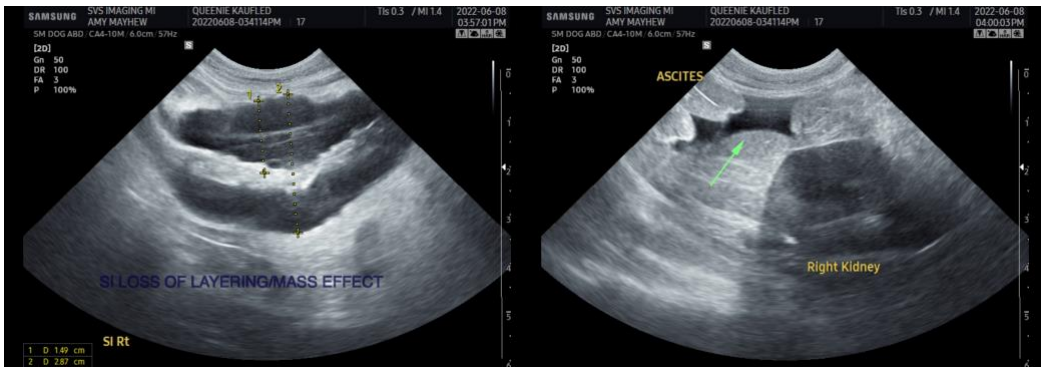

SonoPath

Clinical Sonography & Telecytology

EDUCATIONAL TELECONSULTATION SERVICES™

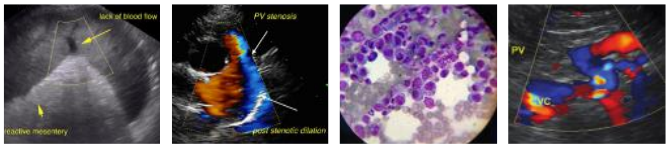

SonoPath.com™

1-800-838-4268 info@sonopath.com

PATIENT

Queenie Kaufled

SPECIES

Feline

BREED

Suberian

SEX

Spayed Female

AGE

17 Years

WEIGHT

14.2 Pounds

INTERPRETED BY

Kathleen Sennello DVM, MS, Diplomate ACVIM (Small Animal Internal Medicine)

IMAGING PERFORMED BY

Amy Mayhew, LVT

HOSPITAL NAME

SVS Imaging MI

REFERRING VET

Oxford VH

INVOICE

15954

DATE

6/8/22

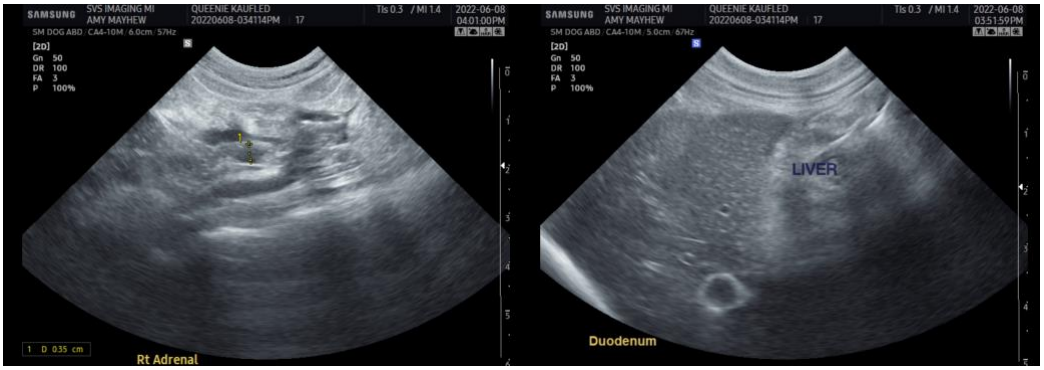

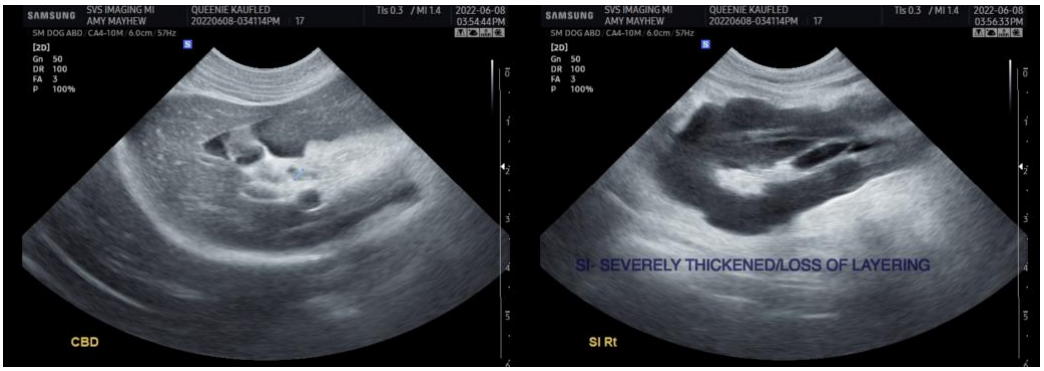

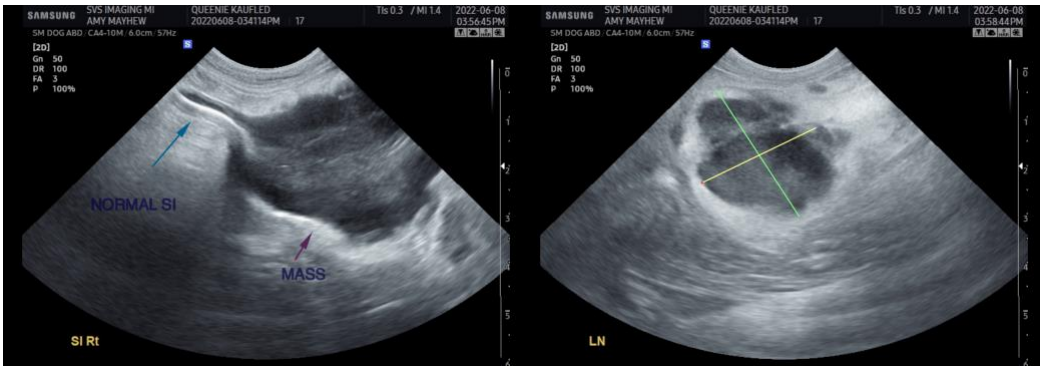

The information and recommendations provided are based on the images presented by the referring veterinarian. No evaluation can be communicated regarding pathology that was not visible in the image/video clips provided.

Thank you for this referral. If the clinical or image interpretation does not parallel your findings or if I can be of any further assistance please contact me.

Kathleen Sennello DVM,MS, Diplomate ACVIM (Small animal Internal Medicine)
kathleen.sennello@sonopath.com