



**DATE PRESENTING CLINICAL SIGNS**

6/5/26 **Patient History:** Losing weight (lost 3lbs in a year), blood in stool.

**PATIENT Current Medications:** Eats GI Biome.

Zeus Russell

**Labwork Results:** Labwork not attached, reported as all bloodwork WNL.

**Date of Previous IntraPet Ultrasound:** No previous.

**Sedation:** IM sedation required to complete full diagnostic ultrasound.

**Stat Report:** Not requested.

**SPECIES**

**Imaging Performed by:** Rachel Brillhart, RDMS.

Feline

**ULTRASONOGRAPHIC EXAMINATION OF THE ABDOMEN**

**BREED**

**Urinary System**

DSH

The urinary bladder is moderately distended with anechoic urine. The Bladder wall, trigone, ureteral papillae and visible urethra (to a depth of 2cm) appear normal with no evidence of wall thickening, mucosal irregularities, masses or cystic calculi.

**SEX**

Neutered Male

The left kidney has a normal shape and size (4.15 cm). Overall echogenicity is normal with adequate corticomedullary distinction and a typical 1:3 cortex:medulla ratio. There is no evidence of focal perinephric inflammation or effusion. There is no evidence of pyelectasia, nephroliths, infarcts or hydroureter. Renal vasculature is normal.

**AGE**

5/1/17

The right kidney has a normal shape and size (4.09 cm). Overall echogenicity is normal with adequate corticomedullary distinction and a typical 1:3 cortex:medulla ratio. There is no evidence of focal perinephric inflammation or effusion. There is no evidence of pyelectasia, nephroliths, infarcts or hydroureter. Renal vasculature is normal.

**WEIGHT**

11.6 lbs

**INTERPRETED BY**

**Adrenal Glands**

Kathleen Sennello DVM,  
MS, Diplomate ACVIM  
(Small Animal Internal  
Medicine)

The left adrenal gland is normal in size measuring 0.55 cm at the caudal pole. It is observed in its normal position cranial to the left renal artery. It is normal in appearance (uniformly hypoechoic) and shape with no evidence of a mass effect.

**HOSPITAL NAME**

Madonna Veterinary  
Clinic

The right adrenal gland is normal in size measuring 0.48 cm at the caudal pole. It is observed in its normal position between the cranial aspect of the right kidney and the caudal vena cava. It is normal in appearance (uniformly hypoechoic) and shape with no evidence of a mass effect.

**Spleen**

**REFERRING VET**

Dr. Cangro

The spleen is subjectively normal in size, echotexture is homogenous, and the splenic capsule is smooth with no irregularities. The blood flow through the hilus and splenic parenchyma appears normal. No focal parenchymal abnormalities are visualized.

**Liver**

**INVOICE**

75741

The liver is subjectively normal in size (0.90 cm), and echogenicity with smooth peripheral margins. The parenchyma is homogenous echotexture. The visible portions of the vasculature and biliary tract appear normal. No focal nodules or cystic lesions are observed.

The gall bladder lumen is moderately distended. The wall of the gall bladder is prominent and hyperechoic, measuring 0.14 cm. Luminal contents are mild and likely incidental at this time. The cystic and common bile ducts are normal/not visible.

### ***Gastrointestinal***

The stomach contains minimal luminal contents. It measures at a normal thickness of <0.36cm with some variability due to the presence of rugal folds. The distinction of the gastric wall layers is adequate and there is no impression of reduced peristaltic activity. No masses or focal lesions were observed.

The visualized areas of duodenum, jejunum and ileum have a uniform diameter with minimal fluid distension. Wall thickness is normal to slightly increased. Bowel loops follow a typical curvilinear path with distinct wall layering, but some areas display a prominent muscularis layer which does not display the typical 1:3 muscularis:mucosa layer ratio. Duodenum wall measures 0.23 cm. Jejunum wall measures 0.18 cm. Visualized peristalsis appears appropriate. There were no focal lesions consistent with obstruction or a mass effect observed.

The ileocecal junction was visualized and exhibited normal intact wall layering and is subjectively of normal thickness. Sections of colon are visualized with non-formed fecal material and gas shadowing distally. There is no observed focal or generalized colon wall thickening or loss of layering. Descending colon wall measures 0.12 cm.

### ***Pancreas***

The pancreas is hypoechoic and mottled with a prominent pancreatic duct measuring 0.16 cm. There is no evidence of nodules or cystic lesions. There is no evidence of regional mesenteric inflammation or fluid.

### ***Free Abdomen***

Evaluation of the peritoneal cavity did not reveal any evidence of effusion. There is a mesenteric lymphadenopathy with a cluster of lymph nodes at the mesenteric root. Examples measure 0.57 cm and 0.61 cm in diameter. Additionally, there is a cluster near the ileocecal junction measuring 0.39 cm and 0.49 cm. The omentum is hyperechoic around the prominent lymph nodes.

## **ULTRASONOGRAPHIC FINDINGS**

- Hypoechoic, mottled pancreas with prominent pancreatic duct – Findings are most consistent with chronic pancreatic remodeling and mild chronic pancreatitis.
- Segmental areas of mildly ropey small intestine – Findings could be consistent with mild inflammatory type change.
- Mild mesenteric lymphadenopathy – The lymph nodes have an appearance most consistent with reactive lymph nodes, although early neoplastic change cannot be ruled out.

## **INTERPRETATION OF THE FINDINGS & FURTHER RECOMMENDATIONS**

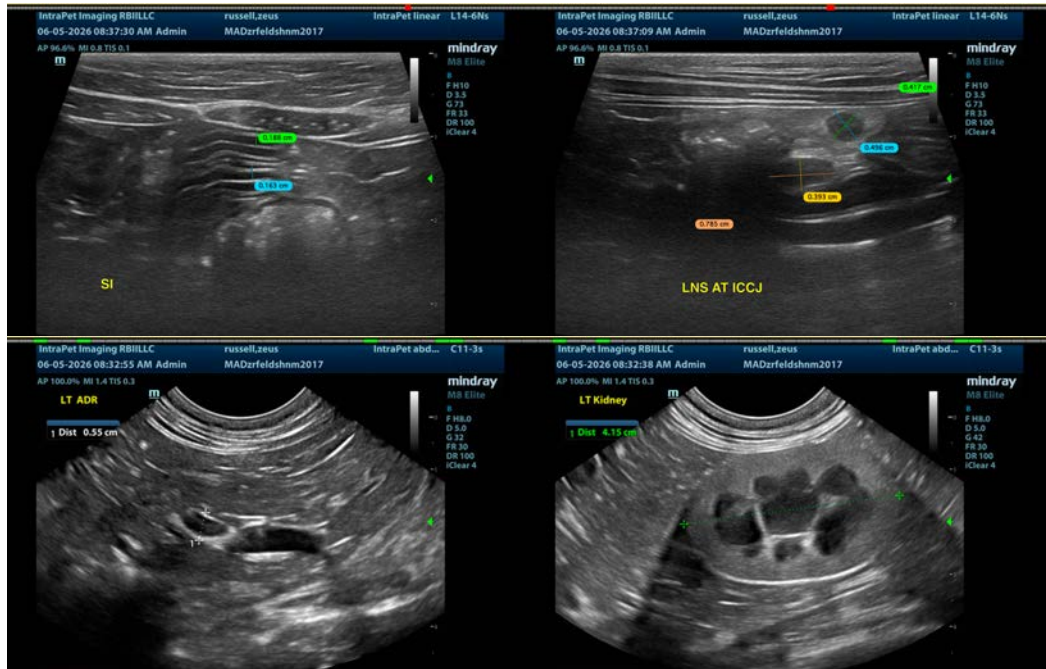
No significant focal lesions are visualized associated with the GI tract to explain the symptoms reported. There are some sections of small intestine that appear somewhat ropey, which could be consistent with mild inflammatory type change. Unfortunately, ultrasound evaluation of the colon can be somewhat insensitive due to intraluminal gas and fecal material. Concurrent mild colitis is possible.

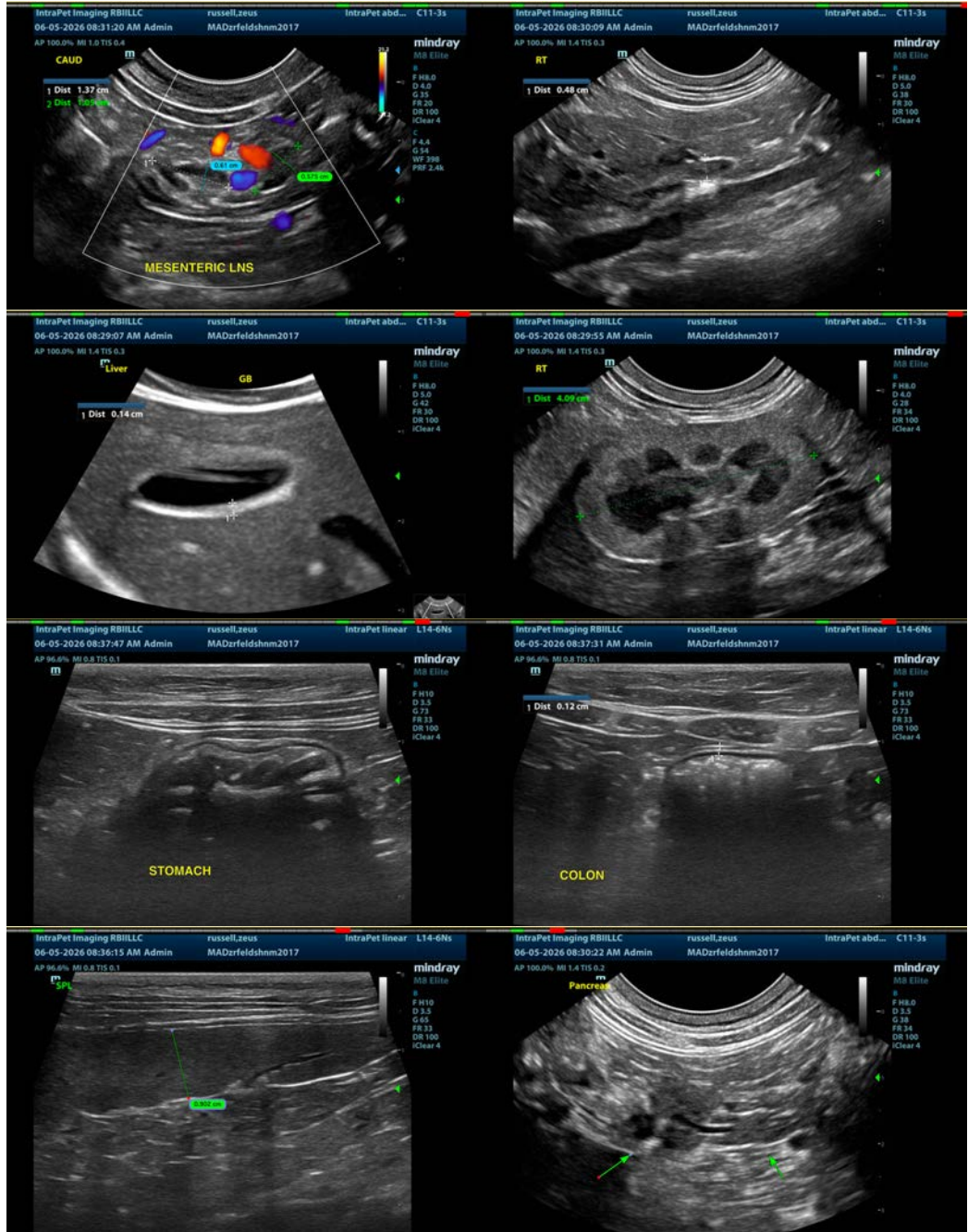
The pancreas is prominent and mottled with some mildly reactive mesentery in the region. Correlate with a PLI level. If this is significantly elevated, consider treatment for chronic pancreatitis/gastroenterocolitis, and continued monitoring. Additionally consider the following:

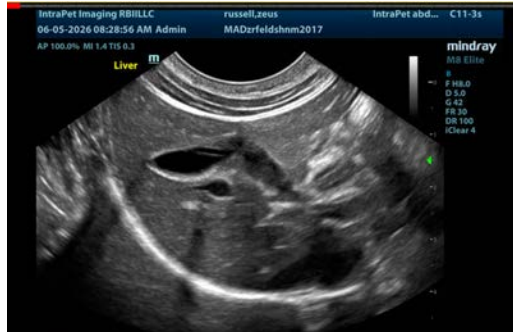- Consider a GI panel to Texas A&M for a qualitative fPLI, TLI, cobalamin and folate, looking for evidence of underlying small intestinal disease, etc.
- If small intestinal disease is strongly suspected, consider a prescription hydrolyzed protein diet (Royal Canin has a combination ultra low-fat hydrolyzed diet that is good for patients with pancreatitis).
- Recommend probiotic therapy.

If symptoms are persistent despite empirical treatment and treatment for pancreatitis, then further evaluation potentially of the GI tract may be warranted. This could involve GI biopsies +/- colonoscopy. Additionally, you could consider repeat imaging to reevaluate the lymph nodes and to for progressive enlargement or other changes.

Recommend three view thoracic radiographs to evaluate for possible concurrent thoracic disease/involvement (disregard if this has already been done).







**The information and recommendations provided are based on the images presented by the referring veterinarian/sonographer. No evaluation can be communicated regarding pathology that was not visible in the image/video clips provided.**

Thank you for this referral. If the clinical or image interpretation does not parallel your findings or if I can be of any further assistance please contact me.

Kathleen Sennello DVM,MS, Diplomate ACVIM (Small animal Internal Medicine)  
info@sonopath.com