



PATIENT

Pearl Bryant

SPECIES

Canine

BREED

Australian Cattle Dog

SEX

Spayed Female

AGE

12 Years

WEIGHT

38 lbs

INTERPRETED BY

Kathleen Sennello DVM,
 MS, Diplomate ACVIM
 (Small Animal Internal
 Medicine)

IMAGING PERFORMED BY

Kathleen Byrnes

HOSPITAL NAME

Animal Emergency
 Clinic of the High
 Country

REFERRING VET

Dr. Wolverton

INVOICE

75660

DATE

6/4/26

PRESENTING CLINICAL SIGNS

P presented for US due to vomiting, lethargy, labored breathing, elevated liver values. P will eat but then vomit afterwards. fast scan rdvm possible splenic mass. Rad report- gastroenteritis, no evidence of foreign material, aspiration pneumonia of left cranial lung lobe, no evidence of hepatic or splenic mass rec US

Abnormal PE/Chem/CBC/UA Results: ALT 249, ALKP 717

ULTRASONOGRAPHIC EXAMINATION OF THE ABDOMEN

Urinary System

The urinary bladder is moderately distended with anechoic urine. The Bladder wall, trigone, ureteral papillae and visible urethra (to a depth of 2cm) appear normal with no evidence of wall thickening, mucosal irregularities, masses or cystic calculi.

The left kidney has a normal shape and size (6.37 cm). Overall echogenicity is normal with adequate corticomedullary distinction and a typical 1:3 cortex:medulla ratio. There is no evidence of focal perinephric inflammation or effusion. There is no evidence of pyelectasia, nephroliths, infarcts or hydroureter. Renal vasculature is normal.

The right kidney has a normal shape and size (5.79 cm). Overall echogenicity is normal with adequate corticomedullary distinction and a typical 1:3 cortex:medulla ratio. There is no evidence of focal perinephric inflammation or effusion. There is no evidence of pyelectasia, nephroliths, infarcts or hydroureter. Renal vasculature is normal.

Adrenal Glands

The left adrenal gland is normal in size measuring 0.48 cm at the cranial pole and 0.60 cm at the caudal pole. It is observed in its normal position cranial to the left renal artery. It is normal in appearance (uniformly hypoechoic) and shape with no evidence of a mass effect.

The right adrenal gland is normal in size measuring 1.23 cm at the cranial pole and 0.62 cm at the caudal pole. It is observed in its normal position between the cranial aspect of the right kidney and the caudal vena cava. It is normal in appearance (uniformly hypoechoic) and shape with no evidence of a mass effect.

Spleen

The spleen is normal in size and shape. The blood flow through the hilus and splenic parenchyma appears normal. There is a hypoechoic, mixed echogenicity nodule visualized towards the caudal aspect of the spleen measuring 2.57 cm x 2.41 cm. On some views provided there is a questionable 2nd mass effect that has a similar appearance measuring 2.59 cm x 2.33 cm, either consistent with 2nd mass lesion or visualization of the same lesion from the cranial view.

Liver

The liver is large in size, and normal in echogenicity with smooth peripheral margins. The parenchyma is heterogenous in echotexture with subtle, indistinct focal mottling. The visible portions of the vasculature and biliary tract appear normal. There are occasional ill-defined hyperechoic nodules, an example of which measures 0.89 cm.



PATIENT

Pearl Bryant

SPECIES

Canine

BREED

Australian Cattle Dog

SEX

Spayed Female

AGE

12 Years

WEIGHT

38 lbs

INTERPRETED BY

Kathleen Sennello DVM,
 MS, Diplomate ACVIM
 (Small Animal Internal
 Medicine)

IMAGING PERFORMED BY

Kathleen Byrnes

HOSPITAL NAME

Animal Emergency
 Clinic of the High
 Country

REFERRING VET

Dr. Wolverton

INVOICE

75660

DATE

6/4/26

The gall bladder lumen is moderately distended. The wall of the gall bladder is not thickened and has a smooth mucosal surface. There is a moderate amount of non-organized echogenic debris. Some of the debris appears focally mineralized, possibly consistent with small choleliths. A mineralized area visualized measures 0.79 cm. The cystic and common bile ducts are normal/not visible.

Gastrointestinal

The stomach contains mild/moderate fluid and gas. It measures at a normal thickness of 0.53 cm with some variability due to the presence of rugal folds. The distinction of the gastric wall layers is adequate and there is no impression of reduced peristaltic activity. No masses or focal lesions were observed.

Most of the visualized areas of duodenum, jejunum and ileum have a relatively uniform diameter with minimal to moderate fluid and gas distension. Wall thickness is normal. Bowel loops follow a curvilinear path with distinct wall layering maintaining the typical 1:3 muscularis:mucosa layer ratio. Duodenum wall measures 0.46 cm. Jejunum wall measures 0.31 cm. Visualized peristalsis appears appropriate. No focal lesions are observed. Findings could be consistent with mild enteritis/ileus type pattern.

Sections of colon are visualized with formed fecal material and gas shadowing distally. There is no observed focal or generalized colon wall thickening or loss of layering.

Pancreas

The area of the pancreas is normal and isoechoic to surrounding mesentery. There is no evidence of nodules or cystic lesions. There is no evidence of regional mesenteric inflammation or fluid.

Free Abdomen

Evaluation of the peritoneal cavity did not reveal any evidence of effusion, or subjective lymphadenomegaly. The Medial iliac nodes appear normal and there was no evidence of a caudal aortic thrombus at the bifurcation. The omentum is of normal uniform echogenicity.

Other

The right auricle and pericardium were visualized and were unremarkable. No obvious pathology is visualized. If cardiac function evaluation is desired a full echocardiogram is warranted.

ULTRASONOGRAPHIC FINDINGS

- Mixed echogenicity hypoechoic splenic mass lesion with a questionable 2nd lesion observed. Findings could be consistent with a benign or neoplastic lesion (hemangioma, hemangiosarcoma, lymphoid hyperplasia, hematoma, etc).
- Large, heterogeneous liver with occasional ill-defined hyperechoic nodules – The diffuse hepatic changes are non-specific and could be consistent with vacuolar hepatopathy, nodular hyperplasia, inflammatory/immune-mediated disease, fibrosis, extramedullary hematopoiesis, toxic hepatopathy (e.g., copper), infiltrative neoplasia (less likely) or other hepatopathy. The nodules have a somewhat benign appearance. Recommend continued monitoring.
- Moderate gallbladder debris with occasional small mineralizations/choleliths – The significance of the aggregated gallbladder debris is unclear. This could represent an early mucocele, cholestasis, or may be secondary to fasting but seems unlikely to be causing a current issue. Recommend continued monitoring.



PATIENT

Pearl Bryant

- Mild fluid and gas distention of the stomach and some areas of the small intestine – Findings are suggestive of a gastritis/enteritis type pattern.

SPECIES

Canine

BREED

Australian Cattle Dog

SEX

Spayed Female

AGE

12 Years

WEIGHT

38 lbs

INTERPRETED BY

Kathleen Sennello DVM,
 MS, Diplomate ACVIM
 (Small Animal Internal
 Medicine)

IMAGING PERFORMED BY

Kathleen Byrnes

HOSPITAL NAME

Animal Emergency
 Clinic of the High
 Country

REFERRING VET

Dr. Wolverton

INVOICE

75660

DATE

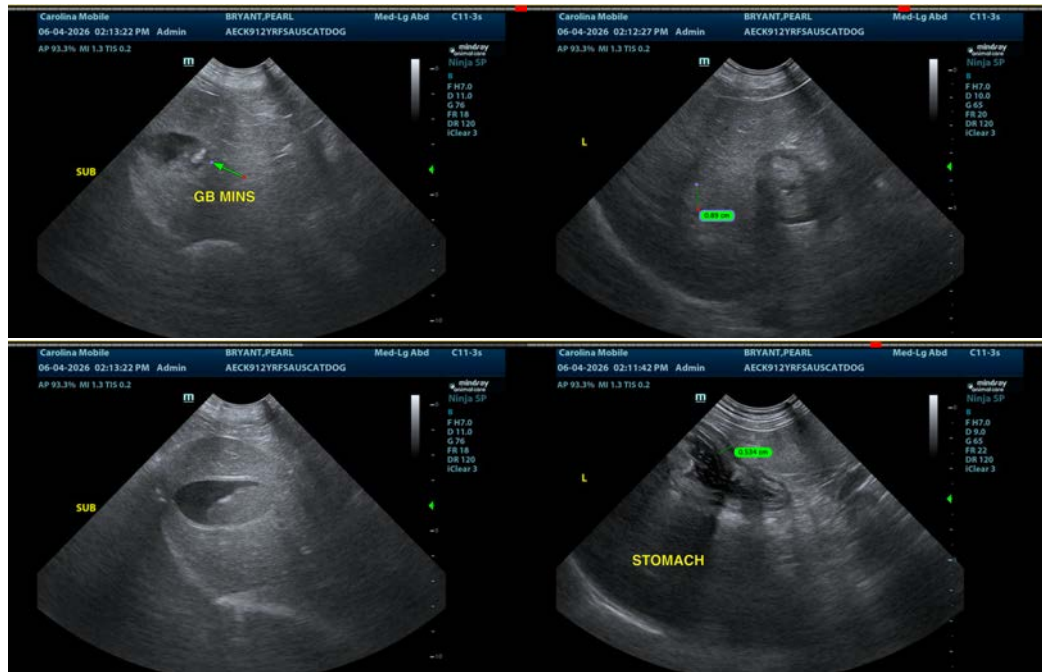
6/4/26

INTERPRETATION OF THE FINDINGS & FURTHER RECOMMENDATIONS

No focal lesions are visualized associated with the GI tract to explain the vomiting reported. There is some gas and fluid distention of the stomach and small bowel, possibly consistent with a gastroenteritis. Recommend empirical treatment for gastroenteritis and continued monitoring while treating for aspiration pneumonia. If symptoms are persistent, consider repeat imaging (radiographs +/- ultrasound), as further evaluation may be warranted. Recommend evaluation of the esophagus on the thoracic films obtained, looking for any evidence of megaesophagus, etc.

There is at least one small, hypoechoic mass effect visualized associated with the spleen. Options moving forward include continued monitoring or a fine needle aspirate.

The liver is mildly heterogeneous, possibly consistent with a vacuolar hepatopathy. Consider reevaluation of liver values. Once GI symptoms have resolved, if they are persistently elevated, further workup such as liver function testing and a fine needle aspirate may be warranted.





PATIENT

Pearl Bryant

SPECIES

Canine

BREED

Australian Cattle Dog

SEX

Spayed Female

AGE

12 Years

WEIGHT

38 lbs

INTERPRETED BY

Kathleen Sennello DVM,
 MS, Diplomate ACVIM
 (Small Animal Internal
 Medicine)

**IMAGING
 PERFORMED BY**

Kathleen Byrnes

HOSPITAL NAME

Animal Emergency
 Clinic of the High
 Country

REFERRING VET

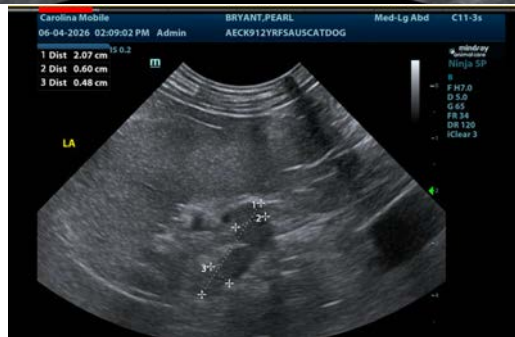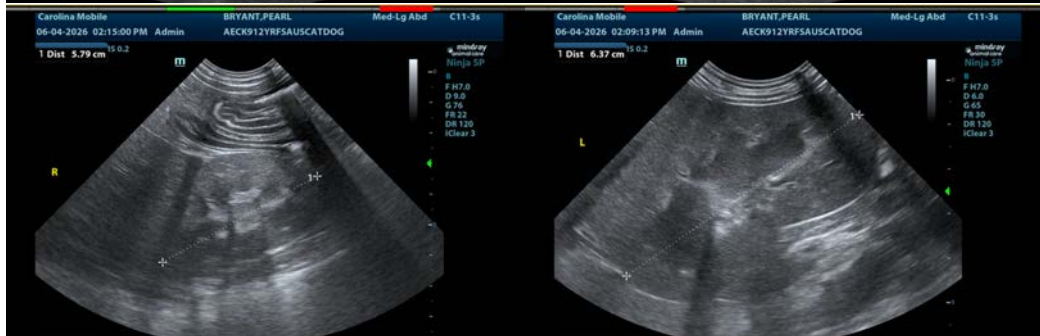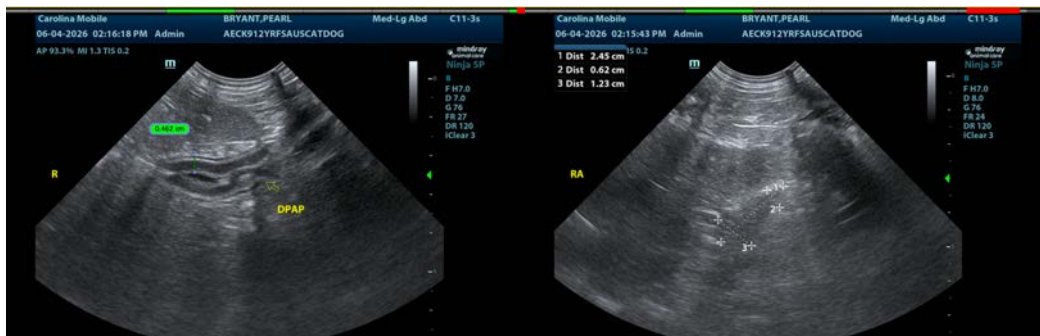
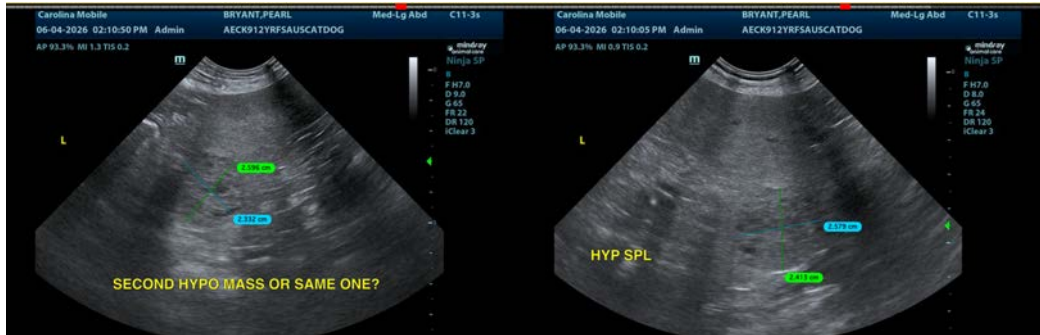
Dr. Wolverton

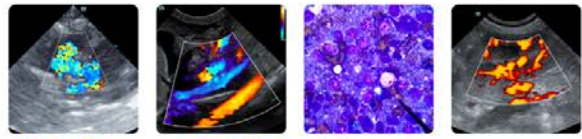
INVOICE

75660

DATE

6/4/26





PATIENT

Pearl Bryant

SPECIES

Canine

BREED

Australian Cattle Dog

SEX

Spayed Female

AGE

12 Years

WEIGHT

38 lbs

INTERPRETED BY

Kathleen Sennello DVM,
MS, Diplomate ACVIM
(Small Animal Internal
Medicine)

**IMAGING
PERFORMED BY**

Kathleen Byrnes

HOSPITAL NAME

Animal Emergency
Clinic of the High
Country

REFERRING VET

Dr. Wolverton

INVOICE

75660

DATE

6/4/26

The information and recommendations provided are based on the images presented by the referring veterinarian/sonographer. No evaluation can be communicated regarding pathology that was not visible in the image/video clips provided.

Thank you for this referral. If the clinical or image interpretation does not parallel your findings or if I can be of any further assistance please contact me.

Kathleen Sennello DVM,MS, Diplomate ACVIM (Small animal Internal Medicine)

info@sonopath.com