



PATIENT

Ema Valentina
Camacho

SPECIES

Canine

BREED

Mixed

SEX

FS

AGE

13 years

WEIGHT

17.6 lbs

INTERPRETED BY

Kathleen Sennello DVM,
MS, Diplomate ACVIM
(Small Animal Internal
Medicine)

IMAGING PERFORMED BY

Dr. Gabriel Ferrer

HOSPITAL NAME

Pulse Pet Ultrasound
Services

REFERRING VET

Dr. Mario Roman

INVOICE

12076

DATE

6/4/2026

PRESENTING CLINICAL SIGNS

Px presented as a referral for an abdominal ultrasound due to elevated hepatic enzymes and the presence of a hepatic mass. Px originally visited rDVM today due to vomiting and bloody diarrhea. Owner reports that Px has been slowly losing weight even though her appetite remains largely the same. A hepatic mass was previously observed in radiographs and an FNA was conducted. The cytology report states that the mass has characteristics of nodular hyperplasia.

On radiographs today Px had severe hepatomegaly as well as a large mass effect in the mid abdomen and a small amount of abdominal effusion. A sample of the abdominal fluid was collected and sent to rDVM for analysis. A sample of the hepatic mass was obtained today via FNA and results are currently pending.

Abnormal PE/Chem/CBC/UA Results: Bloodwork and radiographs attached below for your reference.

ULTRASONOGRAPHIC EXAMINATION OF THE ABDOMEN

Urinary System

The urinary bladder is moderately distended with anechoic urine. The Bladder wall appears mildly thickened and slightly irregular in the apical region measuring 0.26 cm. The region of the trigone, ureteral papillae and proximal urethra appear free from any mass lesions or calculi.

The left kidney has a normal shape and size (4.95 cm). Overall echogenicity is slightly hyperechoic with poor corticomedullary distinction and a typical 1:3 cortex:medulla ratio. There is no evidence of focal perinephric inflammation or effusion. There is no evidence of pyelectasia, nephroliths, infarcts or hydroureter. Renal vasculature is normal.

The right kidney has a normal shape and size (5.51 cm). Overall echogenicity is slightly hyperechoic with poor corticomedullary distinction and a typical 1:3 cortex:medulla ratio. There is no evidence of focal perinephric inflammation or effusion. There is no evidence of pyelectasia, nephroliths, infarcts or hydroureter. Renal vasculature is normal.

Adrenal Glands

The left adrenal gland is normal in size measuring 0.66 cm at the cranial pole and 0.65 cm at the caudal pole. It is observed in its normal position cranial to the left renal artery. It is normal in appearance (uniformly hypoechoic) and shape with no evidence of a mass effect.

The right adrenal gland is normal in size measuring 0.59 cm at the cranial pole and 0.55 cm at the caudal pole. It is observed in its normal position between the cranial aspect of the right kidney and the caudal vena cava. It is normal in appearance (uniformly hypoechoic) and shape with no evidence of a mass effect.

Spleen

The spleen is subjectively normal in size (1.51 cm) and the echotexture is homogenous. The splenic capsule is smooth with no visible irregularities. The blood flow through the hilus and splenic parenchyma appears normal. No focal parenchymal abnormalities are visualized.

Liver



PATIENT

Ema Valentina
Camacho

SPECIES

Canine

BREED

Mixed

SEX

FS

AGE

13 years

WEIGHT

17.6 lbs

The liver is large in size, and irregular. The parenchyma is heterogenous in echotexture with subtle, indistinct focal mottling. The visible portions of the vasculature and biliary tract appear normal. There are occasional ill-define hyper and hypoechoic nodules. Additionally, there is a very large, solid hyperechoic, mixed echogenicity mass effect visualized associated with the mid caudal region of the liver measuring greater than 6.2 cm x 8.75 cm.

The gall bladder lumen is moderately distended. The wall of the gall bladder is not thickened and has a smooth mucosal surface. There is a moderate amount of non-organized echogenic debris. The cystic and common bile ducts are normal/not visible.

Gastrointestinal

The stomach contains minimal luminal contents. It measures at a normal thickness of <0.7cm with some variability due to the presence of rugal folds. The distinction of the gastric wall layers is adequate and there is no impression of reduced peristaltic activity. No masses or focal lesions were observed.

The visualized areas of duodenum, jejunum and ileum have a relatively uniform diameter with minimal fluid distension. Wall thickness is normal. Bowel loops follow a curvilinear path with distinct wall layering maintaining the typical 1:3 muscularis:mucosa layer ratio. The duodenum measured as normal (0.46 cm in wall thickness) and the jejunum measured as normal (0.43 cm.) Visualized peristalsis appears appropriate. There were no focal lesions consistent with obstruction or a mass effect observed.

Sections of colon are visualized with formed fecal material and gas shadowing distally. There is no observed focal or generalized colon wall thickening or loss of layering.

Pancreas

The pancreas is visible/mildly mottled in the right limb. There is no evidence of nodules or cystic lesions. There is no evidence of regional mesenteric inflammation or fluid.

Free Abdomen

Evaluation of the peritoneal cavity revealed a moderate amount of echogenic free fluid. There is no significant lymphadenopathy. The omentum is normal uniform echogenicity.

ULTRASONOGRAPHIC FINDINGS

- Mildly thickened/irregular urinary bladder wall. The bladder mucosal changes could be consistent with cystitis or artifactual due to lack of adequate luminal distension. Bladder neoplasia cannot be ruled out but is considered unlikely in this patient.
- Mild age-related changes visualized associated with both kidneys.
- Large, mixed echogenicity, hyperechoic mass effect visualized associated with the liver. Findings are most consistent with a primary hepatic mass lesion such as an adenoma/carcinoma. Other differentials are possible.
- Moderate gallbladder debris. The significance of the aggregated gallbladder debris is unclear. This could represent an early mucocele, cholestasis, or may be secondary to fasting but seems unlikely to be causing a current issue. Recommend continued monitoring.

INTERPRETED BY

Kathleen Sennello DVM,
MS, Diplomate ACVIM
(Small Animal Internal
Medicine)

IMAGING PERFORMED BY

Dr. Gabriel Ferrer

HOSPITAL NAME

Pulse Pet Ultrasound
Services

REFERRING VET

Dr. Mario Roman

INVOICE

12076

DATE

6/4/2026



PATIENT

Ema Valentina
Camacho

SPECIES

Canine

BREED

Mixed

SEX

FS

AGE

13 years

WEIGHT

17.6 lbs

INTERPRETED BY

Kathleen Sennello DVM,
MS, Diplomate ACVIM
(Small Animal Internal
Medicine)

IMAGING PERFORMED BY

Dr. Gabriel Ferrer

HOSPITAL NAME

Pulse Pet Ultrasound
Services

REFERRING VET

Dr. Mario Roman

INVOICE

12076

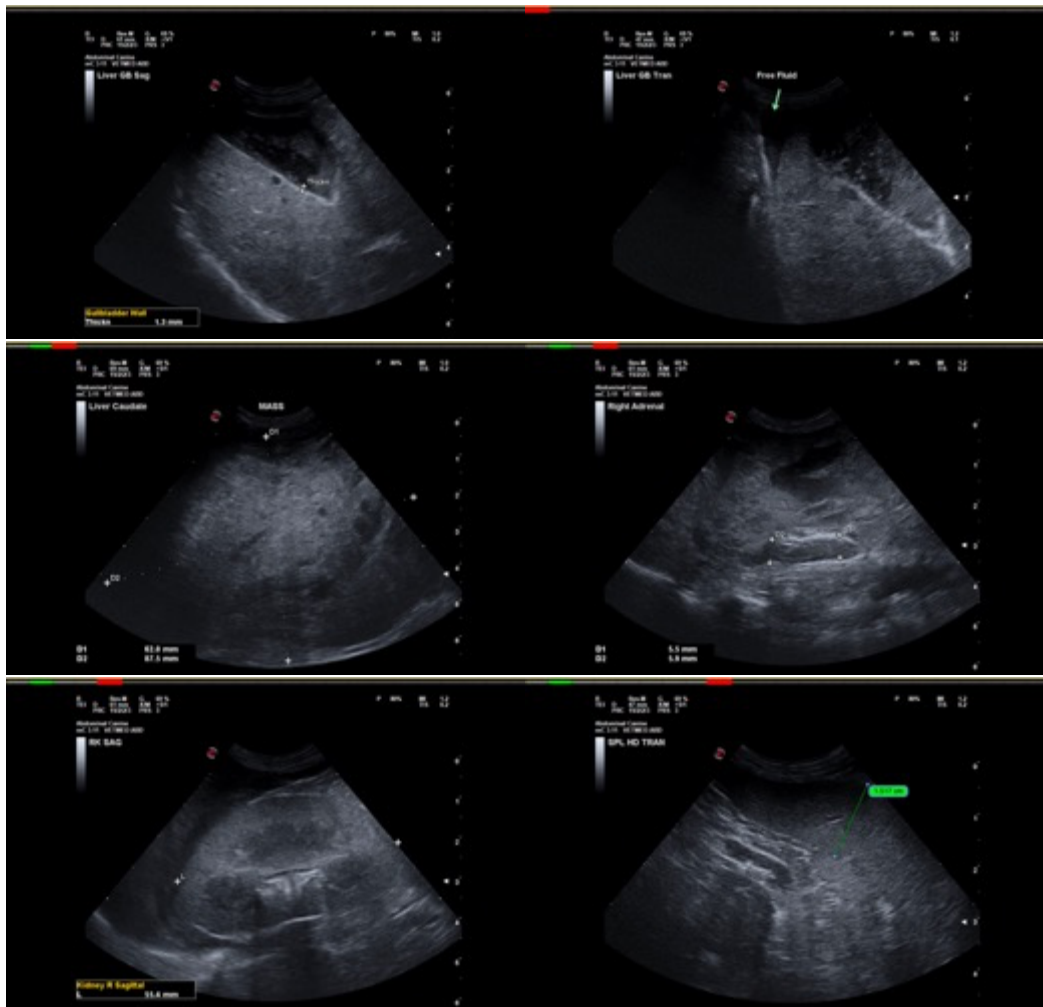
DATE

6/4/2026

INTERPRETATION OF THE FINDINGS & FURTHER RECOMMENDATIONS

There is a large solid mass effect visualized associated with the liver, most consistent with progression of the previously described liver mass lesion. These are often asymptomatic until they get very large and either cause discomfort due to a mass effect, rupture, or cause issues with pressure on other organs. It is uncertain if this mass lesion is associated with the acute vomiting and diarrhea reported as this could represent an acute hemorrhagic diarrhea episode or similar, but I suspect the chronic weight loss is related. Additionally, there is some echogenic free fluid reported to be blood in the history. A source of this hemorrhage is not readily visualized but is a concern. Recommend symptomatic treatment for acute hemorrhagic diarrhea syndrome, and if at all possible, advanced imaging (contrast CT scan) to further evaluate the mass lesion, look for any metastatic lesions, or unseen gastrointestinal lesions which could be contributing to the bleeding reported. Additionally, recommend evaluation of coagulation parameters.

Consider three view thoracic radiographs to rule out concurrent thoracic disease/involvement.





PATIENT

Ema Valentina Camacho

SPECIES

Canine

BREED

Mixed

SEX

FS

AGE

13 years

WEIGHT

17.6 lbs

INTERPRETED BY

Kathleen Sennello DVM,
MS, Diplomate ACVIM
(Small Animal Internal
Medicine)

IMAGING PERFORMED BY

Dr. Gabriel Ferrer

HOSPITAL NAME

Pulse Pet Ultrasound
Services

REFERRING VET

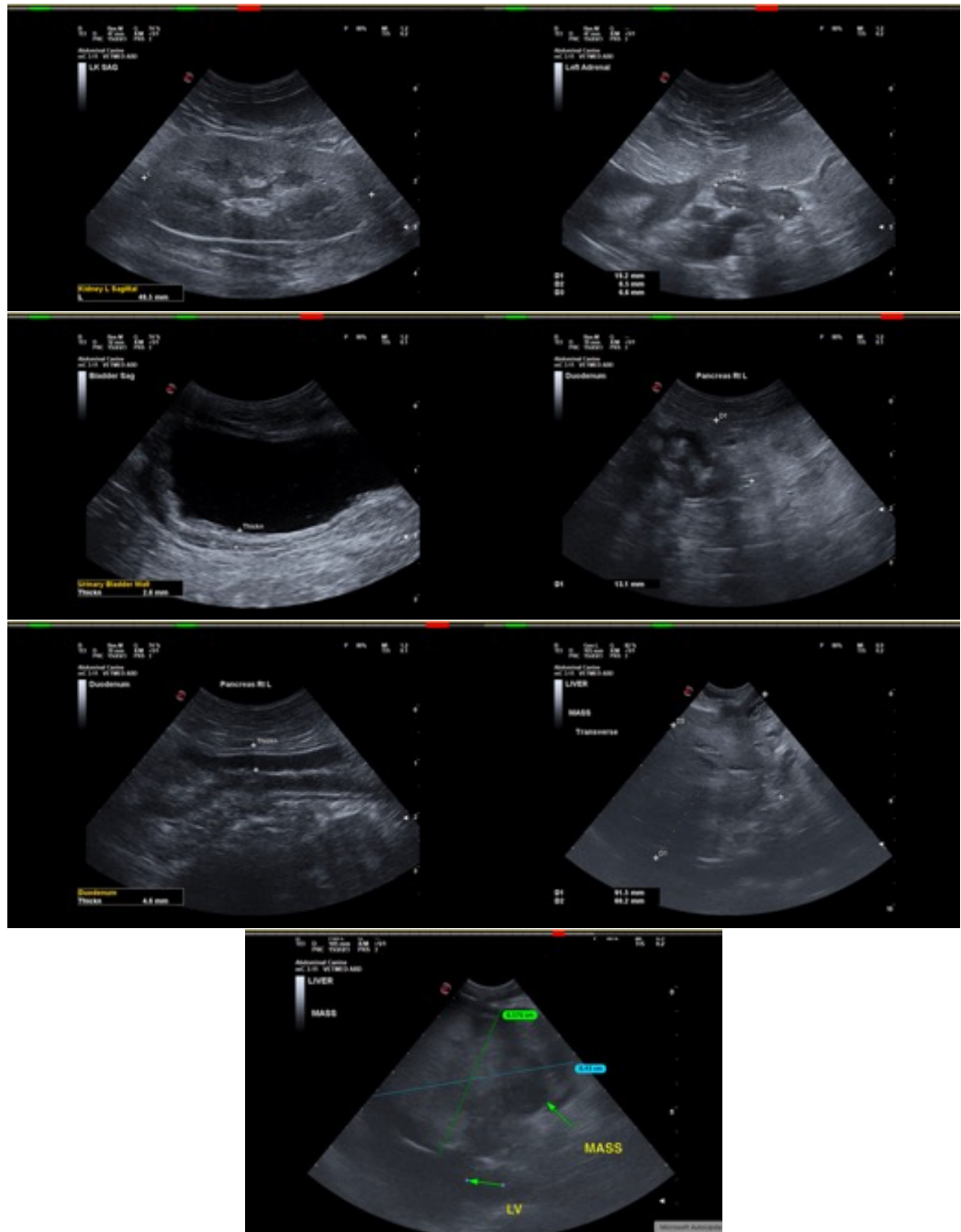
Dr. Mario Roman

INVOICE

12076

DATE

6/4/2026



The information and recommendations provided are based on the images presented by the referring veterinarian/sonographer. No evaluation can be communicated regarding pathology that was not visible in the image/video clips provided.

Thank you for this referral. If the clinical or image interpretation does not parallel your findings or if I can be of any further assistance please contact me.



PATIENT

Kathleen Sennello DVM,MS, Diplomate ACVIM (Small animal Internal Medicine)

Ema Valentina
Camacho

info@sonopath.com

SPECIES

Canine

BREED

Mixed

SEX

FS

AGE

13 years

WEIGHT

17.6 lbs

INTERPRETED BY

Kathleen Sennello DVM,
MS, Diplomate ACVIM
(Small Animal Internal
Medicine)

IMAGING PERFORMED BY

Dr. Gabriel Ferrer

HOSPITAL NAME

Pulse Pet Ultrasound
Services

REFERRING VET

Dr. Mario Roman

INVOICE

12076

DATE

6/4/2026