



PATIENT

Ellie Blundell

SPECIES

Canine

BREED

Collie x

SEX

Spayed Female

AGE

5 Years

WEIGHT

34.2 kg

INTERPRETED BY

Kathleen Sennello DVM,
MS, Diplomate ACVIM
(Small Animal Internal
Medicine)

IMAGING PERFORMED BY

Dr. Iacovides

HOSPITAL NAME

Tuxedo Animal
Hospital

REFERRING VET

Dr. Valencia

INVOICE

75709

DATE

6/4/26

PRESENTING CLINICAL SIGNS

Presented 4/14/26 for hyporexia and increased thirst and urination. Workup revealed significant ALT elevations that have persisted. Dog is clinically much better (eating and active) but ALT remains very high still. Current meds: Zentonil 400 - 2 tabs SID since April 14th 2026

Abnormal PE/Chem/CBC/UA Results:4/14/26: CBC-wnl UA: usg 1.002 wbc5/hpf CHEM: ALT 2139 u/l (10-125) ALP 553 u/l (23-212) 4dx negative Recheck chem: ALT 2334 u/l (5/28/26); 1989 u/l (4/28/26) ALP 666 u/l (5/28/26) 521 u/l (4/28/26)

ULTRASONOGRAPHIC EXAMINATION OF THE ABDOMEN

Urinary System

The urinary bladder is moderately distended with anechoic urine. The Bladder wall, trigone, ureteral papillae and visible urethra (to a depth of 2cm) appear normal with no evidence of wall thickening, mucosal irregularities, masses or cystic calculi.

The left kidney has a normal shape and size (6.82 cm). Overall echogenicity is normal with adequate corticomedullary distinction and a typical 1:3 cortex:medulla ratio. There is no evidence of focal perinephric inflammation or effusion. There is no evidence of pyelectasia, nephroliths, infarcts or hydroureter. Renal vasculature is normal.

The right kidney has a normal shape and size (6.88 cm). Overall echogenicity is normal with adequate corticomedullary distinction and a typical 1:3 cortex:medulla ratio. There is no evidence of focal perinephric inflammation or effusion. There is no evidence of pyelectasia, nephroliths, infarcts or hydroureter. Renal vasculature is normal.

Adrenal Glands

The left adrenal gland is normal in size measuring 0.49 cm at the cranial pole and 0.56 cm at the caudal pole. It is observed in its normal position cranial to the left renal artery. It is normal in appearance (uniformly hypoechoic) and shape with no evidence of a mass effect.

The region of the right adrenal (between right cranial kidney and vena cava) is unremarkable, but the adrenal is not distinctly visualized. No evidence of a mass effect is visualized.

Spleen

The spleen is subjectively normal in size (2.02 cm), echotexture is homogenous, and the splenic capsule is smooth with no irregularities. The blood flow through the hilus and splenic parenchyma appears normal. No focal parenchymal abnormalities are visualized.

Liver

The liver is subjectively normal in size, and echogenicity with smooth peripheral margins. The parenchyma is mildly heterogenous in echotexture with subtle, indistinct focal mottling. The visible portions of the vasculature and biliary tract appear normal. No focal nodules or cystic lesions are observed.



PATIENT

Ellie Blundell

The gall bladder lumen is moderately distended. The wall of the gall bladder is not thickened and has a smooth mucosal surface. Luminal contents are mild and likely incidental at this time. The cystic and common bile ducts are normal/not visible.

SPECIES

Canine

Gastrointestinal

The stomach contains minimal luminal contents. It measures at a normal thickness of <0.7cm with some variability due to the presence of rugal folds. The distinction of the gastric wall layers is adequate and there is no impression of reduced peristaltic activity. No masses or focal lesions were observed.

BREED

Collie x

The visualized areas of duodenum, jejunum and ileum have a relatively uniform diameter with minimal fluid distension. Wall thickness is normal. Bowel loops follow a curvilinear path with distinct wall layering maintaining the typical 1:3 muscularis:mucosa layer ratio. Duodenum wall measures 0.41 cm. Jejunum wall measures 0.35 cm. Visualized peristalsis appears appropriate. There were no focal lesions consistent with obstruction or a mass effect observed.

SEX

Spayed Female

AGE

5 Years

Sections of colon are visualized with non-formed fecal material and gas shadowing distally. There is no observed focal or generalized colon wall thickening or loss of layering.

Pancreas

WEIGHT

34.2 kg

The pancreas is normal and isoechoic to surrounding mesentery. There is no evidence of nodules or cystic lesions. There is no evidence of regional mesenteric inflammation or fluid.

Free Abdomen

INTERPRETED BY

Kathleen Sennello DVM,
MS, Diplomate ACVIM
(Small Animal Internal
Medicine)

Evaluation of the peritoneal cavity did not reveal any evidence of effusion, or subjective lymphadenomegaly. The Medial iliac nodes appear normal and there was no evidence of a caudal aortic thrombus at the bifurcation. The omentum is of normal uniform echogenicity.

ULTRASONOGRAPHIC FINDINGS

- Mildly heterogeneous liver – The diffuse hepatic changes are non-specific and could be consistent with vacuolar hepatopathy, nodular hyperplasia, inflammatory/immune-mediated disease, fibrosis, extramedullary hematopoiesis, toxic hepatopathy (e.g., copper), infiltrative neoplasia (less likely) or other hepatopathy.

IMAGING PERFORMED BY

Dr. Iacovides

INTERPRETATION OF THE FINDINGS & FURTHER RECOMMENDATIONS

HOSPITAL NAME

Tuxedo Animal
Hospital

No focal lesions are visualized associated with the liver or the gallbladder to explain the liver enzyme elevations reported. Subjectively, the liver appears mildly heterogeneous. This is a non-specific finding. Consider further evaluation of the suspected hepatopathy with the following:

REFERRING VET

Dr. Valencia

- Recommend pre- and post-prandial bile acids to assess liver function.
- Consider screening for Leptospirosis.
- Consider a fine needle aspirate of the liver (provided coagulation parameters are normal).

INVOICE

75709

Recommend empirical treatment for acute liver injury while waiting test results with a course of Denamarin, antibiotics, Ursodiol and supportive care. If there is no response to this treatment and diagnostics are not helpful, ultimately biopsies of the liver with samples for histopathology, culture and copper levels may be warranted.

DATE

6/4/26



PATIENT

Ellie Blundell

SPECIES

Canine

BREED

Collie x

SEX

Spayed Female

AGE

5 Years

WEIGHT

34.2 kg

INTERPRETED BY

Kathleen Sennello DVM,
MS, Diplomate ACVIM
(Small Animal Internal
Medicine)

IMAGING PERFORMED BY

Dr. Iacovides

HOSPITAL NAME

Tuxedo Animal
Hospital

REFERRING VET

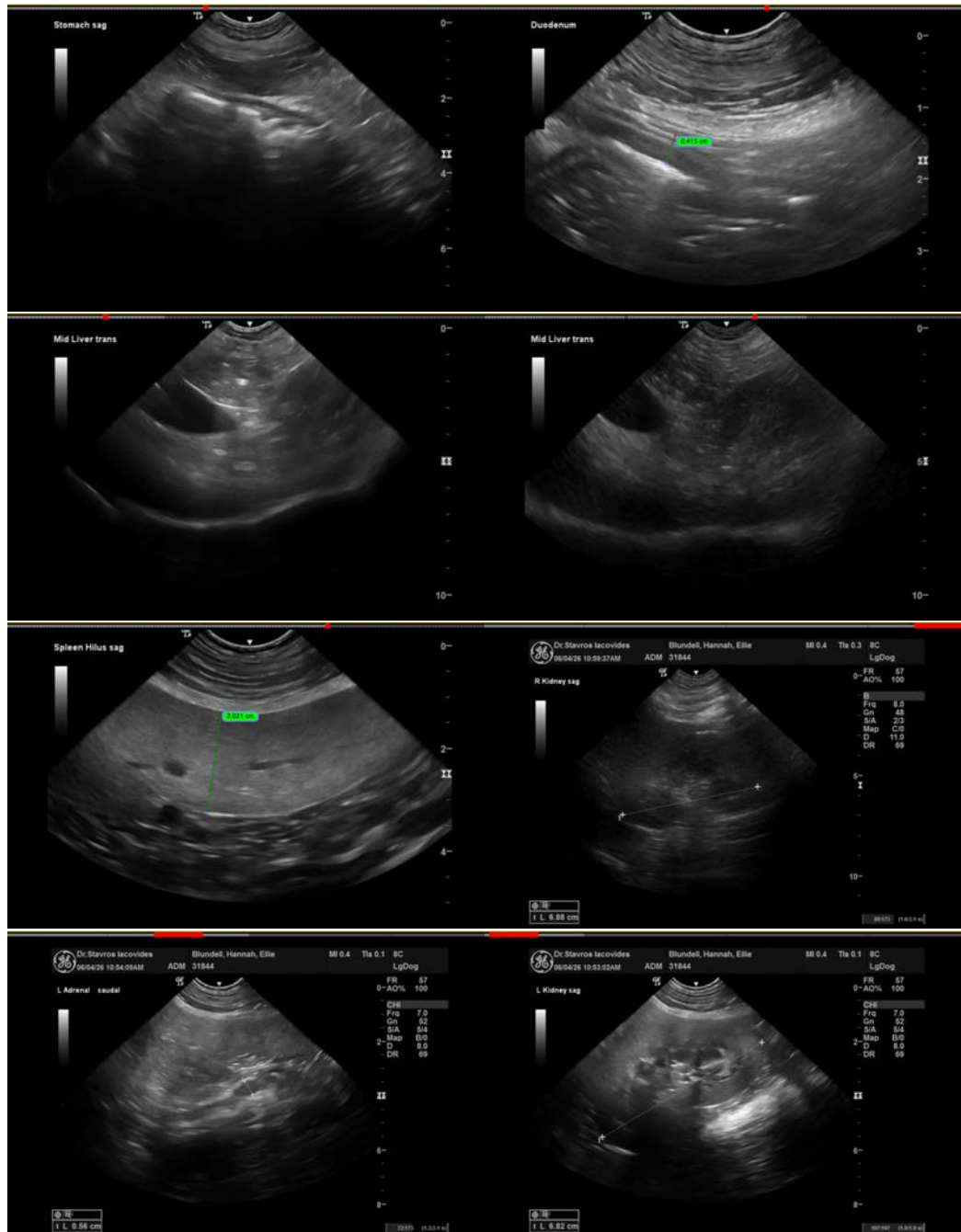
Dr. Valencia

INVOICE

75709

DATE

6/4/26





PATIENT

Ellie Blundell

SPECIES

Canine

BREED

Collie x

SEX

Spayed Female

AGE

5 Years

WEIGHT

34.2 kg

INTERPRETED BY

Kathleen Sennello DVM,
MS, Diplomate ACVIM
(Small Animal Internal
Medicine)

IMAGING PERFORMED BY

Dr. Iacovides

HOSPITAL NAME

Tuxedo Animal
Hospital

REFERRING VET

Dr. Valencia

INVOICE

75709

DATE

6/4/26

The information and recommendations provided are based on the images presented by the referring veterinarian/sonographer. No evaluation can be communicated regarding pathology that was not visible in the image/video clips provided.

Thank you for this referral. If the clinical or image interpretation does not parallel your findings or if I can be of any further assistance please contact me.

Kathleen Sennello DVM,MS, Diplomate ACVIM (Small animal Internal Medicine)

info@sonopath.com