



PATIENT

Daira Massanet

SPECIES

Canine

BREED

Miniature Schnauzer

SEX

Spayed Female

AGE

9 Years

WEIGHT

21.6 lbs

INTERPRETED BY

Kathleen Sennello DVM,
MS, Diplomate ACVIM
(Small Animal Internal
Medicine)

IMAGING PERFORMED BY

Gabriel Ferrer, DVM

HOSPITAL NAME

Pulse: Pet Ultrasound

REFERRING VET

Dr. Richard Gonzalez

INVOICE

75683

DATE

6/4/26

PRESENTING CLINICAL SIGNS

Px presented as a referral for a double study (echocardiogram and abdominal ultrasound) due to a suspected syncope and a possible mass being observed in radiographs. Px originally visited rDVM due to having experienced a possible syncope, rDVM reports a newly auscultated Grade V - VI / VI heart murmur. Radiographs were then performed and a mass-like soft tissue opacity noted within the right cranial to mid abdomen. Cardiomegaly was also observed in the radiographs performed by rDVM. Px is currently on Vetmedin 2.5mg BID.

Abnormal PE/Chem/CBC/UA Results: Radiographs attached below for your reference.

ULTRASONOGRAPHIC EXAMINATION OF THE ABDOMEN

Urinary System

The urinary bladder is moderately distended with anechoic urine. The Bladder wall, trigone, ureteral papillae and visible urethra (to a depth of 2cm) appear normal with no evidence of wall thickening, mucosal irregularities, masses or cystic calculi.

The left kidney has a normal shape and size (4.68 cm). Overall echogenicity is normal with adequate corticomedullary distinction and a typical 1:3 cortex:medulla ratio. There is no evidence of focal perinephric inflammation or effusion. There is no evidence of pyelectasia, nephroliths, infarcts or hydroureter. Renal vasculature is normal.

The right kidney has a normal shape and size (0.54 cm). Overall echogenicity is normal with adequate corticomedullary distinction and a typical 1:3 cortex:medulla ratio. There is no evidence of focal perinephric inflammation or effusion. There is no evidence of pyelectasia, nephroliths, infarcts or hydroureter. Renal vasculature is normal.

Adrenal Glands

The left adrenal gland is normal in size measuring 0.49 cm at the cranial pole and 0.52 cm at the caudal pole. It is observed in its normal position cranial to the left renal artery. It is normal in appearance (uniformly hypoechoic) and shape with no evidence of a mass effect.

The right adrenal gland is normal in size measuring 0.42 cm at the cranial pole and 0.44 cm at the caudal pole. It is observed in its normal position between the cranial aspect of the right kidney and the caudal vena cava. It is normal in appearance (uniformly hypoechoic) and shape with no evidence of a mass effect.

Spleen

The spleen is subjectively normal in size (1.6 cm), echotexture is homogenous, and the splenic capsule is smooth with no irregularities. The blood flow through the hilus and splenic parenchyma appears normal. No focal parenchymal abnormalities are visualized.

Liver

The liver is subjectively large in size, and normal in echogenicity with smooth peripheral margins. The parenchyma is mildly heterogenous in echotexture with subtle, indistinct focal mottling. The visible portions of the vasculature and biliary tract appear normal. There is a hypoechoic nodule visualized in the mid left caudal region of the liver measuring 1.09 cm x 1.52 cm.



PATIENT

Daira Massanet

The gall bladder lumen is moderately distended. The wall of the gall bladder is not thickened and has a smooth mucosal surface. Luminal contents are mild and likely incidental at this time. The cystic and common bile ducts are normal/not visible.

SPECIES

Canine

Gastrointestinal

The stomach contains minimal luminal contents. It measures at a normal thickness of 0.32 cm with some variability due to the presence of rugal folds. The distinction of the gastric wall layers is adequate and there is no impression of reduced peristaltic activity. No masses or focal lesions were observed.

BREED

Miniature Schnauzer

The visualized areas of duodenum, jejunum and ileum have a relatively uniform diameter with minimal fluid distension. Wall thickness is normal. Bowel loops follow a curvilinear path with distinct wall layering maintaining the typical 1:3 muscularis:mucosa layer ratio. Duodenum wall measures 0.34 cm. Jejunum wall measures 0.38 cm. Visualized peristalsis appears appropriate. There were no focal lesions consistent with obstruction or a mass effect observed.

SEX

Spayed Female

AGE

9 Years

Sections of colon are visualized with formed fecal material and gas shadowing distally. There is no observed focal or generalized colon wall thickening or loss of layering.

WEIGHT

21.6 lbs

Pancreas

The pancreas is normal and isoechoic to surrounding mesentery. There is no evidence of nodules or cystic lesions. There is no evidence of regional mesenteric inflammation or fluid.

INTERPRETED BY

Kathleen Sennello DVM,
MS, Diplomate ACVIM
(Small Animal Internal
Medicine)

Free Abdomen

Evaluation of the peritoneal cavity did not reveal any evidence of effusion. There is no evidence of a diffuse lymphadenopathy. The right iliac lymph node is prominent, measuring at 0.57 cm.

IMAGING PERFORMED BY

Gabriel Ferrer, DVM

ULTRASONOGRAPHIC FINDINGS

- Subjectively large, mildly heterogeneous liver with a hypoechoic nodule – The diffuse hepatic changes are non-specific and could be consistent with vacuolar hepatopathy, nodular hyperplasia, inflammatory/immune-mediated disease, fibrosis, extramedullary hematopoiesis, toxic hepatopathy (e.g., copper), infiltrative neoplasia (less likely) or other hepatopathy. The hypoechoic nodule visualized has somewhat of a benign appearance, although an early neoplastic lesion cannot be ruled out.

HOSPITAL NAME

Pulse: Pet Ultrasound

INTERPRETATION OF THE FINDINGS & FURTHER RECOMMENDATIONS

The liver is subjectively mildly heterogeneous and large. Correlate with current liver values. There is a small hypoechoic nodule visualized in the liver, which at this time has somewhat of a benign appearance, but continued monitoring is warranted. No evidence of a large mass effect is visualized on today's exam. Radiographic changes could be a result of summation artifact or similar.

REFERRING VET

Dr. Richard Gonzalez

INVOICE

75683

DATE

6/4/26



PATIENT

Daira Massanet

SPECIES

Canine

BREED

Miniature Schnauzer

SEX

Spayed Female

AGE

9 Years

WEIGHT

21.6 lbs

INTERPRETED BY

Kathleen Sennello DVM,
MS, Diplomate ACVIM
(Small Animal Internal
Medicine)

**IMAGING
PERFORMED BY**

Gabriel Ferrer, DVM

HOSPITAL NAME

Pulse: Pet Ultrasound

REFERRING VET

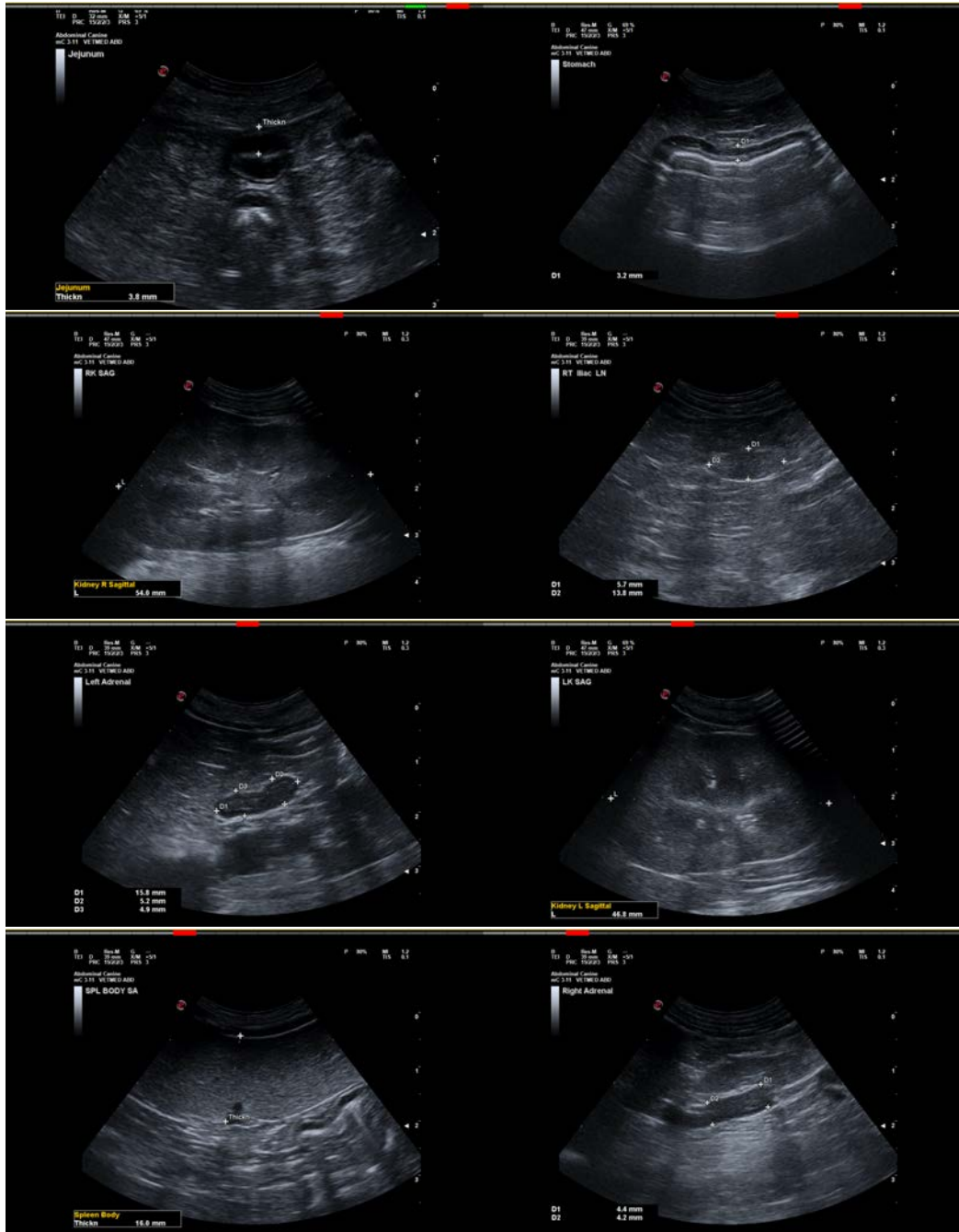
Dr. Richard Gonzalez

INVOICE

75683

DATE

6/4/26





PATIENT

Daira Massanet

SPECIES

Canine

BREED

Miniature Schnauzer

SEX

Spayed Female

AGE

9 Years

WEIGHT

21.6 lbs

INTERPRETED BY

Kathleen Sennello DVM,
MS, Diplomate ACVIM
(Small Animal Internal
Medicine)

IMAGING PERFORMED BY

Gabriel Ferrer, DVM

HOSPITAL NAME

Pulse: Pet Ultrasound

REFERRING VET

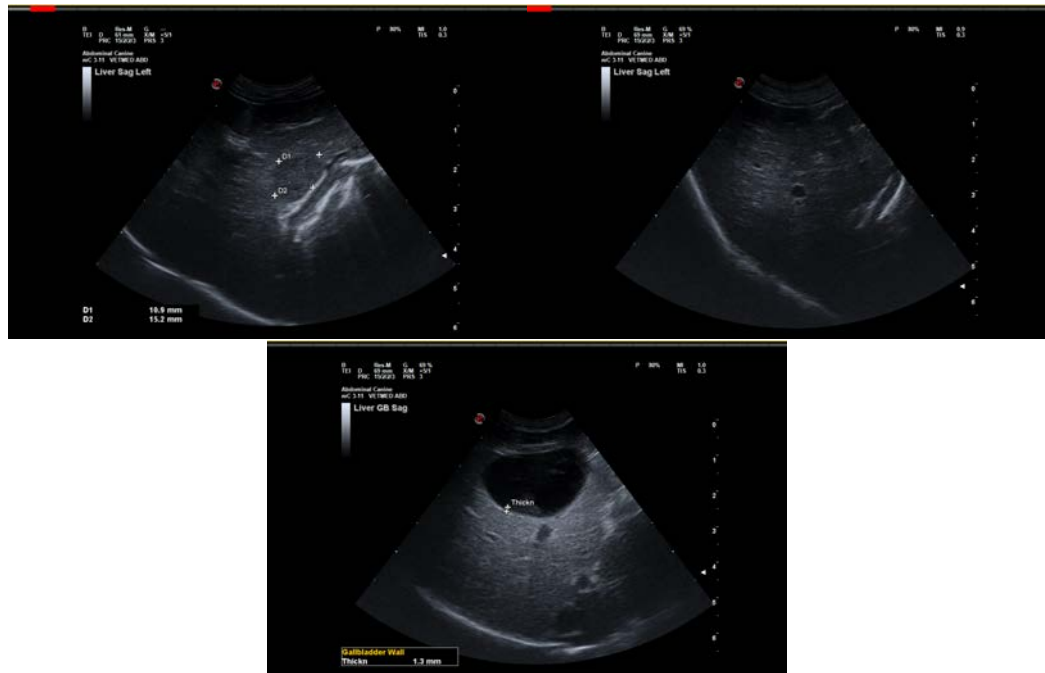
Dr. Richard Gonzalez

INVOICE

75683

DATE

6/4/26



The information and recommendations provided are based on the images presented by the referring veterinarian/sonographer. No evaluation can be communicated regarding pathology that was not visible in the image/video clips provided.

Thank you for this referral. If the clinical or image interpretation does not parallel your findings or if I can be of any further assistance please contact me.

Kathleen Sennello DVM,MS, Diplomate ACVIM (Small animal Internal Medicine)

info@sonopath.com