

**DATE PRESENTING CLINICAL SIGNS**

6/30/23 ADR for about 6 weeks; decreased appetite and energy level, weight loss, slightly increased respiratory effort at times, lameness associated with back legs and muscle atrophy along spine. Mildly anemic on blood work.

PATIENT

Murphy McAdam

Current Medications: Rimadyl 75mg - 1 PO BID for approximately 4 weeks

Lab Results: Slightly elevated ALKP; mild anemia, leukocytosis

Date of Previous IntraPet Ultrasound: No previous.

SPECIES

Canine

Sedation: Not required to complete full diagnostic ultrasound.

Stat Report: STAT requested.

Imaging Performed By: Rachel Brillhart, RDMS.

BREED

Golden Retriever

ULTRASONOGRAPHIC EXAMINATION OF THE ABDOMEN**SEX**

Neutered Male

Urinary System

The urinary bladder is moderately distended with anechoic urine. The Bladder wall, trigone, ureteral papillae and visible urethra (to a depth of 2cm) appear normal with no evidence of wall thickening, mucosal irregularities, masses or cystic calculi.

AGE

1/6/14

The visualized areas of prostate and surrounding tissue appear normal. Unfortunately, the prostate is not fully visualized likely due to its intrapelvic location. Correlate with rectal exam findings.

WEIGHT

76.4 Pounds

The left kidney has a normal shape and size (7.66 cm). Overall echogenicity is normal with adequate corticomedullary distinction and a typical 1:3 cortex:medulla ratio. There is no evidence of focal perinephric inflammation or effusion. There is no evidence of pyelectasia, nephroliths, infarcts or hydroureter. Renal vasculature is normal.

INTERPRETED BY

Kathleen Sennello DVM,
MS, Diplomate ACVIM
(Small Animal Internal
Medicine)

The right kidney has a normal shape and size (7.2 cm). Overall echogenicity is normal with adequate corticomedullary distinction and a typical 1:3 cortex:medulla ratio. There is no evidence of focal perinephric inflammation or effusion. There is no evidence of pyelectasia, nephroliths, infarcts or hydroureter. Renal vasculature is normal.

HOSPITAL NAME

Banfield Timonium

Adrenal Glands

The left adrenal gland is normal in size measuring 0.94 cm at the caudal pole. It is observed in its normal position cranial to the left renal artery. It is normal in appearance (uniformly hypoechoic) and shape with no evidence of a mass effect.

REFERRING VET

Dr. Borrison

The right adrenal gland is normal in size measuring 0.92 cm at the caudal pole. It is observed in its normal position between the cranial aspect of the right kidney and the caudal vena cava. It is normal in appearance (uniformly hypoechoic) and shape with no evidence of a mass effect.

INVOICE

43608

Spleen

The spleen is subjectively normal in size, echotexture is homogenous, and the splenic capsule is smooth with no irregularities. The blood flow through the hilus and splenic parenchyma appears normal. No focal parenchymal abnormalities are visualized.

Liver

The liver is subjectively normal in size, and echogenicity with smooth peripheral margins. The parenchyma is homogenous echotexture. The visible portions of the vasculature and biliary tract appear normal. There is a small hyperechoic nodule visualized within the parenchyma measuring 0.94 cm.

The gallbladder lumen is moderately distended. The wall of the gall bladder is not thickened and has a smooth mucosal surface. Luminal contents are mild and primarily anechoic. The cystic and common bile ducts are normal/not visible.

Gastrointestinal

The stomach contains minimal luminal contents. It measures at a normal thickness of <0.7cm with some variability due to the presence of rugal folds. The distinction of the gastric wall layers is adequate and there is no impression of reduced peristaltic activity. No masses or focal lesions were observed.

The visualized areas of duodenum, jejunum and ileum have a relatively uniform diameter with minimal fluid distension. Wall thickness is normal. Bowel loops follow a curvilinear path with distinct wall layering maintaining the typical 1:3 muscularis:mucosa layer ratio. The duodenum measured as normal (between 0.3-0.5cm in wall thickness) and the jejunum measured as normal (between 0.2-0.47cm.) Visualized peristalsis appears appropriate. There were no focal lesions consistent with obstruction or a mass effect observed.

The ileocecal junction was visualized and exhibited normal intact wall layering and is subjectively of normal thickness. Sections of colon are visualized with formed fecal material and gas shadowing distally. There is no observed focal or generalized colon wall thickening or loss of layering.

Pancreas

The pancreas is prominent and mottled compared to the surrounding isoechoic mesentery. There is no evidence of nodules or cystic lesions. There is no evidence of regional mesenteric inflammation or fluid.

Free Abdomen

Evaluation of the peritoneal cavity did not reveal any evidence of effusion, or subjective lymphadenomegaly. The Medial iliac nodes appear normal and there was no evidence of a caudal aortic thrombus at the bifurcation. The omentum is of normal uniform echogenicity.

Other

The right auricle and pericardium were visualized and were unremarkable. No obvious pathology is visualized. If cardiac function evaluation is desired a full echocardiogram is warranted.

There is no evidence of significant pleural effusion. There is a large, irregular, hypoechoic, heterogeneous mass effect visualized in the left side of the thorax measuring 12.1 cm x 14.84 cm.

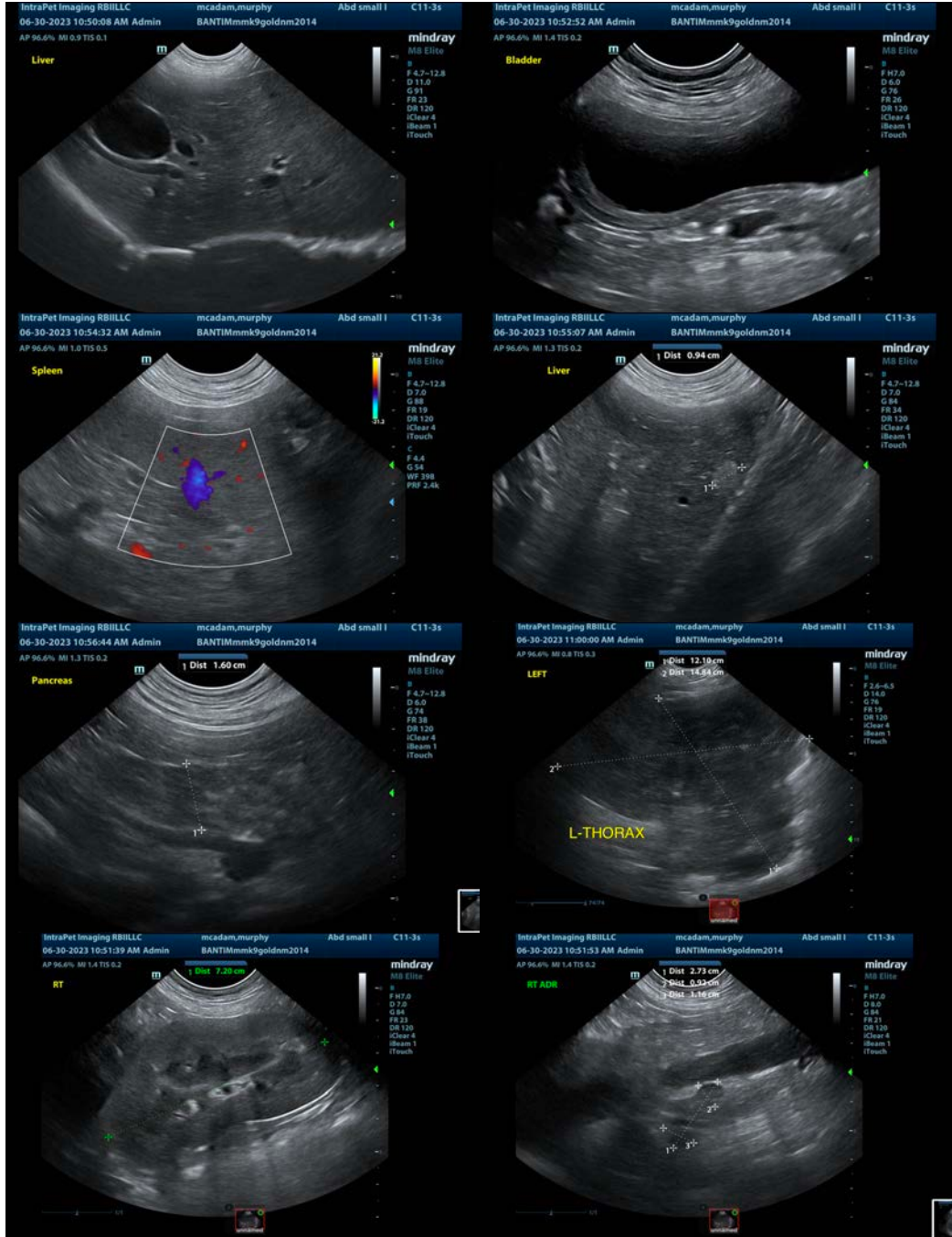
ULTRASONOGRAPHIC FINDINGS

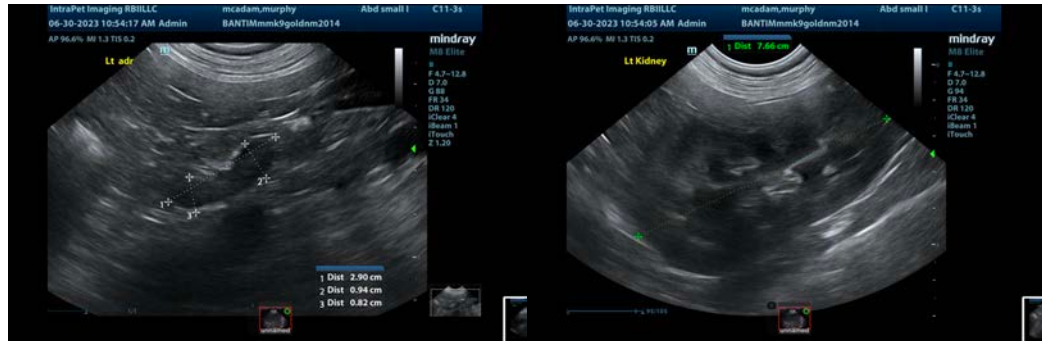
- Prominent, mottled pancreas – The pancreatic changes are most consistent with age-related parenchymal remodeling, potentially secondary to a prior inflammatory episode, early fibrosis or chronic pancreatitis.
- Small hyperechoic hepatic nodule – The appearance of this nodule trends towards a benign process. Recommend continued monitoring.
- Large left-sided thoracic mass – Recommend a contrast CT scan.

INTERPRETATION OF THE FINDINGS & FURTHER RECOMMENDATIONS

The changes observed in the abdomen are mild and likely incidental at this time.

A large, irregular, hypoechoic, heterogeneous mass effect is visualized in the left thorax. Recommend a contrast CT scan for further evaluation and possible sampling.





The information and recommendations provided are based on the images presented by the referring veterinarian/sonographer. No evaluation can be communicated regarding pathology that was not visible in the image/video clips provided.

Thank you for this referral. If the clinical or image interpretation does not parallel your findings or if I can be of any further assistance please contact me.

Kathleen Sennello DVM,MS, Diplomate ACVIM (Small animal Internal Medicine)
info@sonopath.com