

PATIENT

Molly Bair

SPECIES

Canine

BREED

Labrador

SEX

Spayed Female

AGE

10 Years

WEIGHT

85 lbs

INTERPRETED BY

Kathleen Sennello DVM,
MS, Diplomate ACVIM
(Small Animal Internal
Medicine)

IMAGING PERFORMED BY

Nikki Kollman, RVT

HOSPITAL NAME

Airpark Animal
Hospital

REFERRING VET

Dr. Superczynski

INVOICE

75634

DATE

6/3/26

PRESENTING CLINICAL SIGNS

Mild elevation of ALT on routine screening. Pet has a history of diarrhea which is currently controlled. No known toxins, GI symptoms. Current medications: Dasaquin daily, occasional use of carprofen for OA. Maintaining wt. BAR

Abnormal PE/Chem/CBC/UA Results: Slowly progressive ALT 162 May 2026, 124 in May 2025. Rest of CBC and Chem within normal range. 4dx and fecal neg

ULTRASONOGRAPHIC EXAMINATION OF THE ABDOMEN

Urinary System

The urinary bladder is moderately distended with anechoic urine. The apical wall of the urinary bladder appears mildly thickened and irregular, measuring at 0.51 cm. The trigone, ureteral papillae and visible urethra (to a depth of 2cm) appear normal with no evidence of wall thickening, mucosal irregularities, masses or cystic calculi.

The left kidney has a normal shape and size (6.08 cm). Overall echogenicity is normal with adequate corticomedullary distinction and a typical 1:3 cortex:medulla ratio. There is no evidence of focal perinephric inflammation or effusion. There is no evidence of pyelectasia, nephroliths, infarcts or hydronephrosis. Renal vasculature is normal.

The right kidney has a normal shape and size (6.94 cm). Overall echogenicity is normal with adequate corticomedullary distinction and a typical 1:3 cortex:medulla ratio. There is no evidence of focal perinephric inflammation or effusion. There is no evidence of pyelectasia, nephroliths, infarcts or hydronephrosis. Renal vasculature is normal.

Adrenal Glands

The left adrenal gland is normal in size measuring 0.91 cm at the cranial pole and 0.64 cm at the caudal pole. It is observed in its normal position cranial to the left renal artery. It is normal in appearance (uniformly hypoechoic) and shape with no evidence of a mass effect.

The right adrenal gland is normal in size measuring 0.77 cm at the caudal pole. It is observed in its normal position between the cranial aspect of the right kidney and the caudal vena cava. It is normal in appearance (uniformly hypoechoic) and shape with no evidence of a mass effect.

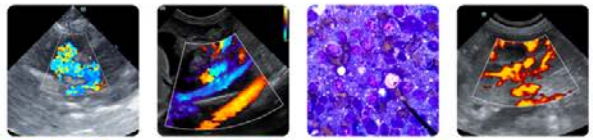
Spleen

The spleen is subjectively normal in size (2.02 cm), echotexture is homogenous, and the splenic capsule is smooth with no irregularities. The blood flow through the hilus and splenic parenchyma appears normal. No focal parenchymal abnormalities are visualized.

Liver

The liver is normal/borderline small and heterogeneous. The visible portions of the vasculature and biliary tract appear normal. No focal nodules or cystic lesions are observed.

The gall bladder lumen is moderately distended. The wall of the gall bladder is not thickened and has a smooth mucosal surface. Luminal contents are mild and likely incidental at this time. The cystic and common bile ducts are normal/not visible.



PATIENT

Molly Bair

SPECIES

Canine

BREED

Labrador

SEX

Spayed Female

AGE

10 Years

WEIGHT

85 lbs

INTERPRETED BY

Kathleen Sennello DVM,
MS, Diplomate ACVIM
(Small Animal Internal
Medicine)

IMAGING PERFORMED BY

Nikki Kollman, RVT

HOSPITAL NAME

Airpark Animal
Hospital

REFERRING VET

Dr. Superczynski

INVOICE

75634

DATE

6/3/26

Gastrointestinal

The stomach contains minimal luminal contents. It measures at a normal thickness of <0.7cm with some variability due to the presence of rugal folds. The distinction of the gastric wall layers is adequate and there is no impression of reduced peristaltic activity. No masses or focal lesions were observed.

The visualized areas of duodenum, jejunum and ileum have a relatively uniform diameter with minimal fluid distension. Wall thickness is normal. Bowel loops follow a curvilinear path with distinct wall layering maintaining the typical 1:3 muscularis:mucosa layer ratio. Duodenum wall measures 0.32 cm. Jejunum wall measures 0.30 cm. Visualized peristalsis appears appropriate. There were no focal lesions consistent with obstruction or a mass effect observed.

Sections of colon are visualized with formed fecal material and gas shadowing distally. There is no observed focal or generalized colon wall thickening or loss of layering.

Pancreas

The area of the pancreas is normal and isoechoic to surrounding mesentery. There is no evidence of nodules or cystic lesions. There is no evidence of regional mesenteric inflammation or fluid.

Free Abdomen

Evaluation of the peritoneal cavity did not reveal any evidence of effusion, or subjective lymphadenomegaly. The Medial iliac nodes appear normal and there was no evidence of a caudal aortic thrombus at the bifurcation. The omentum is of normal uniform echogenicity.

ULTRASONOGRAPHIC FINDINGS


- Mildly thickened/irregular apical wall of the urinary bladder – The bladder mucosal changes could be consistent with cystitis or artifactual due to lack of adequate luminal distension. Bladder neoplasia cannot be ruled out but is considered unlikely in this patient.
- Heterogeneous liver – The diffuse hepatic changes are non-specific and could be consistent with vacuolar hepatopathy, nodular hyperplasia, inflammatory/immune-mediated disease, fibrosis, extramedullary hematopoiesis, toxic hepatopathy (e.g., copper), infiltrative neoplasia (less likely) or other hepatopathy.

INTERPRETATION OF THE FINDINGS & FURTHER RECOMMENDATIONS

No well defined focal lesions are visualized associated with the liver. Subjectively the parenchyma appears slightly irregular and heterogeneous. This is a non-specific finding. No significant changes are visualized associated with the gallbladder/biliary tract.

Consider pre- and post-prandial bile acids to assess liver function. If liver function is normal, options are to continued monitoring with Denamarin and/or pursue further with potential additional testing such as:

- Consider screening for Leptospirosis if clinically appropriate.
- Consider a fine needle aspirate for cytologic evaluation (primarily evaluates for round cell neoplasia, some infectious causes of hepatitis, etc.).



PATIENT

Molly Bair

SPECIES

Canine

BREED

Labrador

SEX

Spayed Female

AGE

10 Years

WEIGHT

85 lbs

INTERPRETED BY

Kathleen Sennello DVM,
MS, Diplomate ACVIM
(Small Animal Internal
Medicine)

**IMAGING
PERFORMED BY**

Nikki Kollman, RVT

HOSPITAL NAME

Airpark Animal
Hospital

REFERRING VET

Dr. Superczynski

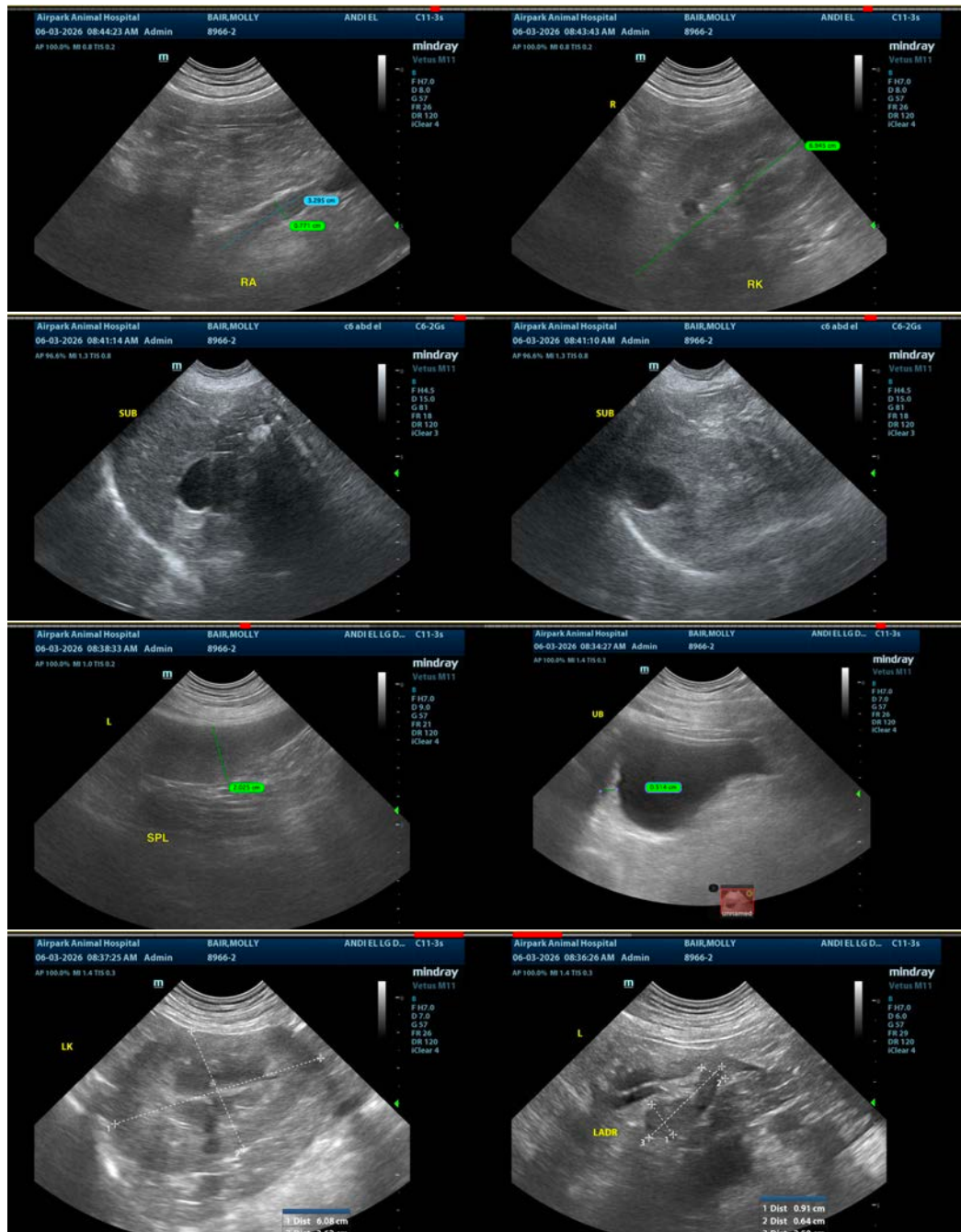
INVOICE

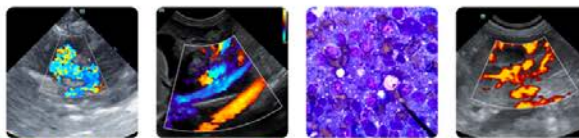
75634

DATE

6/3/26

If liver enzyme elevations are persistent/progressive and/or liver function is abnormal, ultimately biopsies of the liver may be necessary with samples for histopathology, culture and copper levels. Additionally, repeat imaging could be considered in the future, looking for progression of the lesions observed on today's scan or the development of new lesions.





PATIENT

Molly Bair

SPECIES

Canine

BREED

Labrador

SEX

Spayed Female

AGE

10 Years

WEIGHT

85 lbs

INTERPRETED BY

Kathleen Sennello DVM,
MS, Diplomate ACVIM
(Small Animal Internal
Medicine)

IMAGING PERFORMED BY

Nikki Kollman, RVT

HOSPITAL NAME

Airpark Animal
Hospital

REFERRING VET

Dr. Superczynski

INVOICE

75634

DATE

6/3/26

The information and recommendations provided are based on the images presented by the referring veterinarian/sonographer. No evaluation can be communicated regarding pathology that was not visible in the image/video clips provided.

Thank you for this referral. If the clinical or image interpretation does not parallel your findings or if I can be of any further assistance please contact me.

Kathleen Sennello DVM,MS, Diplomate ACVIM (Small animal Internal Medicine)

info@sonopath.com