

**DATE PRESENTING CLINICAL SIGNS**

6/3/22

Intermittent bouts of GI upset, vomiting, diarrhea with frank blood and also suspected melena started 2 months ago. Screening BW unremarkable. x-rays unremarkable. Pet does have some abdominal pain in cranial abdomen on most recent exam 6/1 and rectal exam showed frank blood. Was started on Metronidazole on 5/26 and improved then went back down hill.

PATIENT

Luna Frost

SPECIES

Canine

BREED

Great Pyrenees X

Current Medications: metronidazole 500 mg - 1 po BID since 5/26
omeprazole 20 mg - 1 SID for next 5 days, Carafate 1 g - 1 BID for 3 days, gabapentin 300 mg - 1 BID for 5 days, cerenia inj given 6/1
Lab Results: 4/1/22 CBC/Chem - TP - 5.1, glob 1.7, mild monocytosis 1.19 and basophilia 0.11 rest wnl.
6/1/22 snap CPL normal.
Date of Previous IntraPet Ultrasound: No previous.
Sedation: Not required to complete full diagnostic ultrasound.
Stat Report: Not requested.

SEX

Spayed Female

AGE

4/14/21

WEIGHT

73 Pounds

ULTRASONOGRAPHIC EXAMINATION OF THE ABDOMEN**Urinary System**

The urinary bladder is moderately distended with anechoic urine. The Bladder wall, trigone, ureteral papillae and visible urethra (to a depth of 2cm) appear normal with no evidence of wall thickening, mucosal irregularities, masses or cystic calculi.

The left kidney has a normal shape and size (6.41 cm). Overall echogenicity is normal with adequate corticomedullary distinction and a typical 1:3 cortex:medulla ratio. There is no evidence of perinephric inflammation or effusion. There is no evidence of pyelectasia, nephroliths, infarcts or hydroureter. Renal vasculature is normal.

The right kidney has a normal shape and size (5.56 cm). Overall echogenicity is normal with adequate corticomedullary distinction and a typical 1:3 cortex:medulla ratio. There is no evidence of perinephric inflammation or effusion. There is no evidence of pyelectasia, nephroliths, infarcts or hydroureter. Renal vasculature is normal.

Adrenal Glands

The left adrenal gland is normal in size measuring 0.57 cm at the caudal pole. It is observed in its normal position cranial to the left renal artery. It is normal in appearance (uniformly hypoechoic) and shape with no evidence of a mass effect.

The right adrenal gland is normal in size measuring 0.68 cm at the caudal pole. It is observed in its normal position between the cranial aspect of the right kidney and the caudal vena cava. It is normal in appearance (uniformly hypoechoic) and shape with no evidence of a mass effect.

Spleen

The spleen is subjectively normal in size, echotexture is homogenous, and the splenic capsule is smooth with no irregularities. The blood flow through the hilus and splenic parenchyma appears normal. No focal parenchymal abnormalities are visualized.

Liver

The liver is subjectively normal in size, and echogenicity with smooth peripheral margins. The parenchyma is homogenous echotexture. The visible portions of the vasculature and biliary tract appear normal. No focal nodules or cystic lesions are observed.

INTERPRETED BY

Kathleen Sennello DVM,
MS, Diplomate ACVIM
(Small Animal Internal
Medicine)

IMAGING PERFORMED BY

Rachel Brilhart RDMS

HOSPITAL NAME

Greenbrier Vet Clinic

REFERRING VET

Dr. Boccanfuso

INVOICE

38418

The gallbladder lumen is moderately distended. The wall of the gall bladder is not thickened and has a smooth mucosal surface. Luminal contents are primarily anechoic. The cystic and common bile ducts are normal/not visible.

Gastrointestinal

The stomach contains minimal luminal contents. It measures at a normal thickness of <0.7cm with some variability due to the presence of rugal folds. The distinction of the gastric wall layers is adequate and there is no impression of reduced peristaltic activity. On some images, there is prominence to the pyloric region of the stomach. The wall measures as slightly thickened up to 1.2 cm with some possible reduced distinction of wall layering. There is no evidence of an obstruction.

The visualized areas of duodenum, jejunum and ileum have a relatively uniform diameter with minimal fluid distension. Wall thickness is normal. Bowel loops follow a curvilinear path with distinct wall layering maintaining the typical 1:3 muscularis:mucosa layer ratio. The duodenum measured as normal (between 0.3-0.5cm in wall thickness) and the jejunum measured as normal (between 0.2-0.47cm.) Visualized peristalsis appears appropriate. There were no focal lesions consistent with obstruction or a mass effect observed.

The ileocecal junction was visualized and exhibited normal intact wall layering and is subjectively of normal thickness. Sections of colon are visualized with formed fecal material and gas shadowing distally. There is no observed focal or generalized colon wall thickening or loss of layering.

Pancreas

The pancreas is normal and isoechoic to surrounding mesentery. There is no evidence of nodules or cystic lesions. There is no evidence of regional mesenteric inflammation or fluid.

Free Abdomen

Evaluation of the peritoneal cavity did not reveal any evidence of effusion, or subjective lymphadenomegaly. The Medial iliac nodes appear normal and there was no evidence of a caudal aortic thrombus at the bifurcation. The omentum is of normal uniform echogenicity.

ULTRASONOGRAPHIC FINDINGS

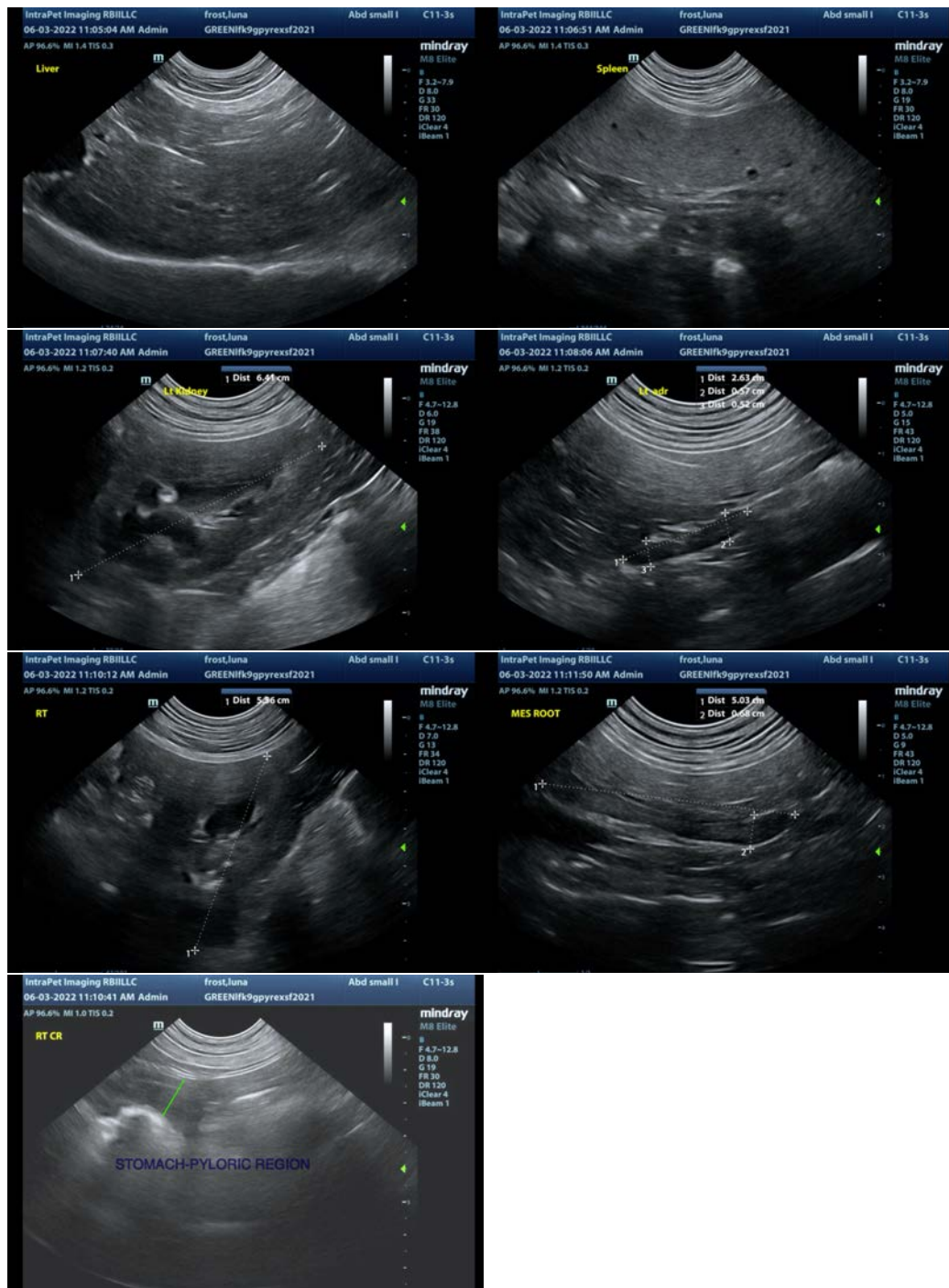
- Prominent, possibly thickened/irregular pyloric region of the stomach – This is subjective and can be consistent with inflammation, edema, infiltrative neoplasia, imaging artifact due to rugal folds, etc. Additionally, this is a giant breed dog, so wall thickness may be naturally increased.

INTERPRETATION OF THE FINDINGS & FURTHER RECOMMENDATIONS

Today's scan appears relatively normal. On some views, the pyloric region of the stomach appears slightly thickened and irregular. This can be difficult to assess, as the thickening can be consistent with rugal folds, imaging artifact, etc., but given the history, further evaluation could be considered.

- Consider metabolic causes for vomiting and diarrhea.
- Consider screening for Addison's disease +/- liver function testing.
- If metabolic disease is thought unlikely, consider primary gastrointestinal disease such as good allergy/dietary intolerance, GI parasitism, dysbiosis, pancreatitis (not visualized on today's scan, but could still be present), and much less likely intestinal neoplasia.
- Consider a novel protein/hydrolyzed protein prescription diet, chronic probiotic therapy, and a GI panel to Texas A&M for a qualitative PLI, TLI, cobalamin and folate to further evaluate the pancreas and small intestine.

- If symptoms persist and are not responding to your symptomatic therapy, diet change, etc., then consider obtaining GI biopsies. Endoscopic evaluation is excellent for looking at the mucosa of the esophagus and stomach for erosions, etc., but in a giant breed dog, it will have limited utility in obtaining biopsies of the small intestine, so base sampling method on your clinical findings.
- Consider three view thoracic radiographs to rule out concurrent thoracic disease/involvement.



The information and recommendations provided are based on the images presented by the referring veterinarian/sonographer. No evaluation can be communicated regarding pathology that was not visible in the image/video clips provided.

Thank you for this referral. If the clinical or image interpretation does not parallel your findings or if I can be of any further assistance please contact me.

Kathleen Sennello DVM,MS, Diplomate ACVIM (Small animal Internal Medicine)
kathleen.sennello@sonopath.com