

**DATE PRESENTING CLINICAL SIGNS**

6/29/23

Diarrhea start around 1 week ago, needed to wake up in the middle of the night to go out 2 days ago not eating and vomiting - has continued until today Not a typical eater of things, known to rip up his stuffed toy but typically owner is there to throw it away Potentially ton eat food outside on a walk Roommate told owner today that he potentially got into rat poison - called poison hotline noted that it wasn't at a toxic level, 855-764-7661, #3643492 Presented to Urgent Vet Care: - Has continued to have vomiting and diarrhea - Presented to them yesterday for vomiting and hyporexia - patient was noted to get into mouse poison last week, owner noted he did call PPH and was not at a toxic level - Bw: Neu 13.83 (H), Mono 1.22 (H), Na 142 (L), K 3.2 (L), Cl 102 (L) - Pcv/ts: 60/8.2 - Tx: SQ fluids, Buprenorphine inj 6p, Cerenia inj 6p

**PATIENT**

Finn Stringer

**SPECIES**

Canine

**BREED**

Pit Bull X

**SEX**

Neutered Male

**AGE**

6/27/19

**WEIGHT**

58.6 Pounds

**INTERPRETED BY**

Kathleen Sennello DVM,  
MS, Diplomate ACVIM  
(Small Animal Internal  
Medicine)

**HOSPITAL NAME**

Animal Emergency  
Hospital

**REFERRING VET**

Dr. Nacke-Horney

**INVOICE**

43593

Current Medications: Metronidazole, Ondansetron, Metoclopramide, Protonix.

Lab Results: See attached.

Date of Previous IntraPet Ultrasound: No previous.

Sedation: Not required to complete full diagnostic ultrasound.

Stat Report: Declined.

Imaging Performed By: Rachel Brillhart, RDMS.

**ULTRASONOGRAPHIC EXAMINATION OF THE ABDOMEN****Urinary System**

The urinary bladder is moderately distended with anechoic urine. The Bladder wall, trigone, ureteral papillae and visible urethra (to a depth of 2cm) appear normal with no evidence of wall thickening, mucosal irregularities, masses or cystic calculi.

The prostate is borderline large for this neutered male dog (1.5 cm in height in the sagittal view). The parenchyma is homogenous and the external margins are smooth. The prostatic urethra appears normal with no evidence of irregularity, invasion, mass effect or calculi.

The left kidney has a normal shape and size (6.58 cm). Overall echogenicity is normal with adequate corticomedullary distinction and a typical 1:3 cortex:medulla ratio. There is no evidence of focal perinephric inflammation or effusion. There is no evidence of pyelectasia, nephroliths, infarcts or hydroureter. Renal vasculature is normal.

The right kidney has a normal shape and size (6.86 cm). Overall echogenicity is normal with adequate corticomedullary distinction and a typical 1:3 cortex:medulla ratio. There is no evidence of focal perinephric inflammation or effusion. There is no evidence of pyelectasia, nephroliths, infarcts or hydroureter. Renal vasculature is normal.

**Adrenal Glands**

The left adrenal gland is normal in size measuring 0.78 cm at the caudal pole. It is observed in its normal position cranial to the left renal artery. It is normal in appearance (uniformly hypoechoic) and shape with no evidence of a mass effect.

The right adrenal gland is normal in size measuring 0.88 cm at the caudal pole. It is observed in its normal position between the cranial aspect of the right kidney and the caudal vena cava. It is normal in appearance (uniformly hypoechoic) and shape with no evidence of a mass effect.

**Spleen**

The spleen is subjectively normal in size, echotexture is homogenous, and the splenic capsule is smooth with no irregularities. The blood flow through the hilus and splenic parenchyma appears normal. No focal parenchymal abnormalities are visualized.

### **Liver**

The liver is subjectively normal in size, and echogenicity with smooth peripheral margins. The parenchyma is heterogenous in echotexture with subtle, indistinct focal mottling. The visible portions of the vasculature and biliary tract appear normal. No focal nodules or cystic lesions are observed.

The gallbladder lumen is moderately distended. The wall of the gall bladder is not thickened and has a smooth mucosal surface. Luminal contents are mild and primarily anechoic. The cystic and common bile ducts are normal/not visible.

### **Gastrointestinal**

The stomach contains a large amount of fluid. It measures at a normal thickness of <0.7cm with some variability due to the presence of rugal folds. The distinction of the gastric wall layers is adequate and there is no impression of reduced peristaltic activity. No masses or focal lesions were observed.

The visualized areas of jejunum and ileum have a relatively uniform diameter with minimal fluid distension. Wall thickness is normal. Bowel loops follow a curvilinear path with distinct wall layering maintaining the typical 1:3 muscularis:mucosa layer ratio. Jejunum wall measures 0.37 cm. Visualized peristalsis appears appropriate. The proximal bowel appears prominent and fluid distended with a wall measuring 0.57 cm with intact wall layering. There is a focal area of shadowing material visualized within the bowel, measuring >2.5 cm, most consistent with a foreign body.

The ileocecal junction was visualized and exhibited normal intact wall layering and is subjectively of normal thickness. Sections of colon are visualized with formed fecal material and gas shadowing distally. There is no observed focal or generalized colon wall thickening or loss of layering.

### **Pancreas**

The pancreas is prominent and mottled compared to the surrounding isoechoic mesentery. There is no evidence of nodules or cystic lesions. There is no evidence of regional mesenteric inflammation or fluid.

### **Free Abdomen**

There is a small amount of free abdominal fluid. Occasional prominent lymph nodes noted. One mesenteric lymph node visualized measuring 0.86 cm. The omentum is hyperechoic around the intraluminal foreign material.

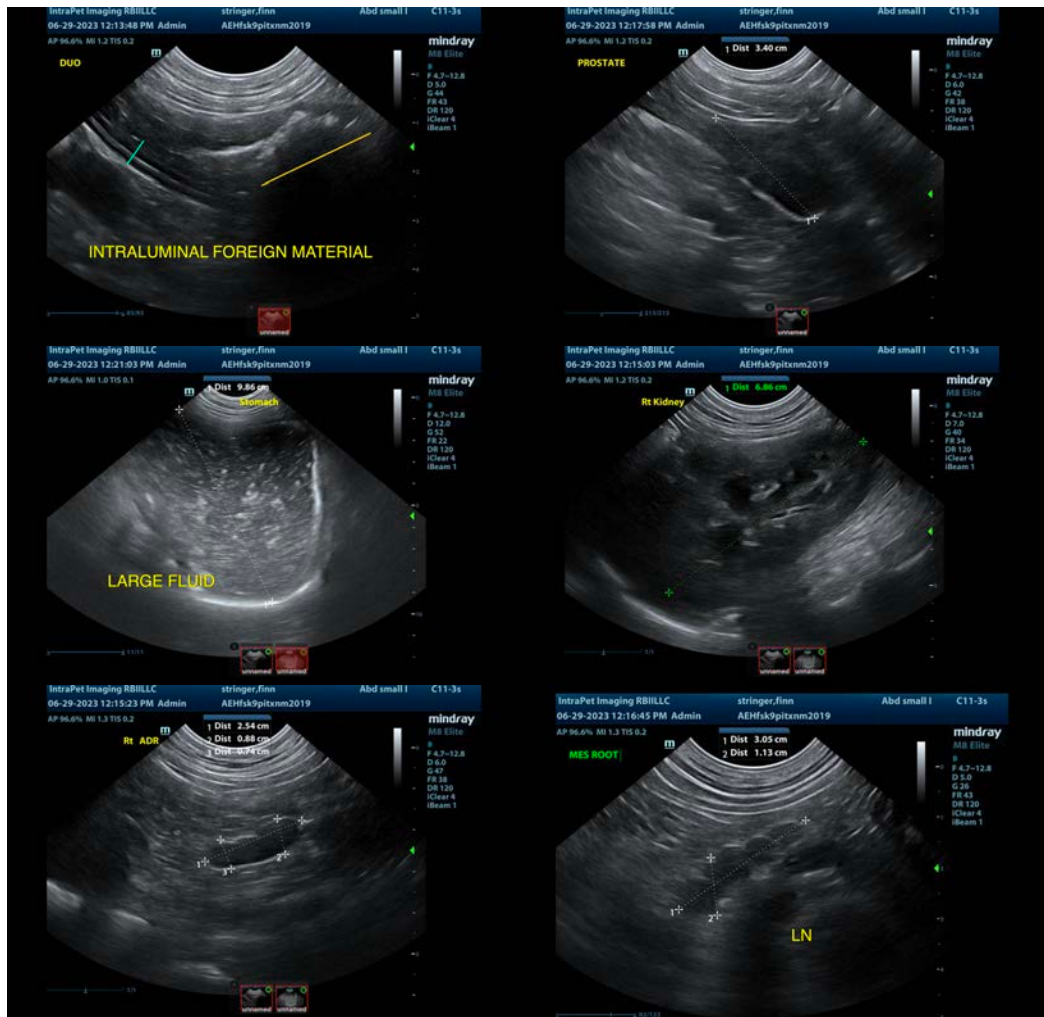
## **ULTRASONOGRAPHIC FINDINGS**

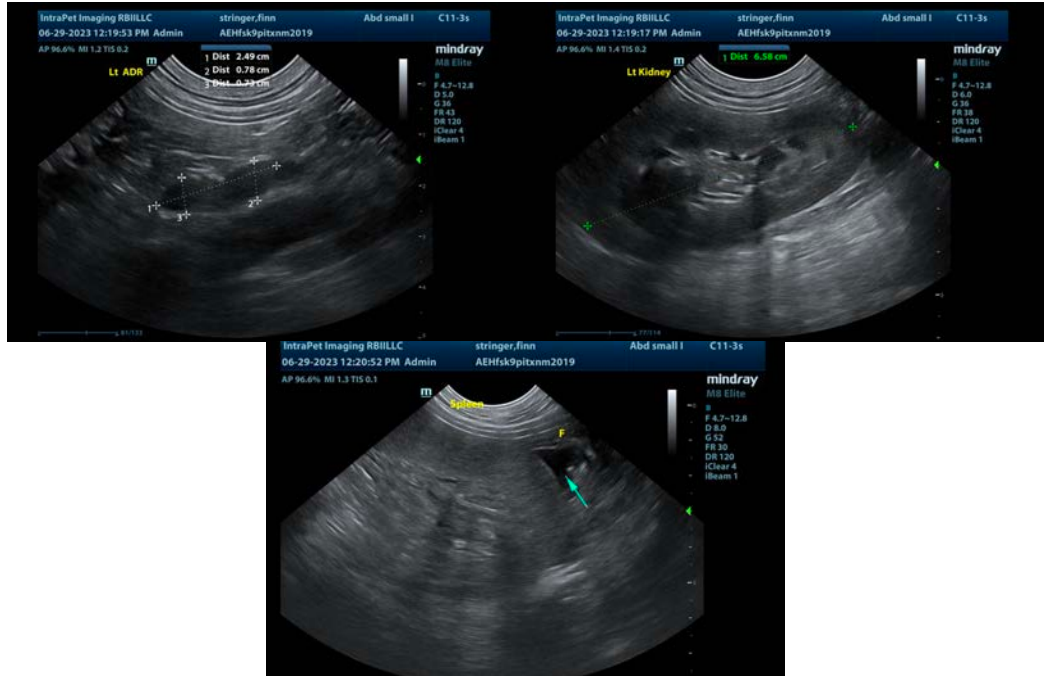
- Focal shadowing material visualized within a dilated loop of bowel – Findings are most consistent with a foreign body visualized within what appears to be the duodenum.
- Severely fluid distended stomach – Findings are most consistent with a high GI obstruction.
- Heterogeneous liver – The diffuse hepatic changes are non-specific and could be consistent with vacuolar hepatopathy, nodular hyperplasia, inflammatory/immune-mediated disease, fibrosis, extramedullary hematopoiesis, toxic hepatopathy (e.g., copper), infiltrative neoplasia (less likely) or other hepatopathy. The significance of this unclear with no significant liver enzyme elevations.
- Borderline large prostate – The prostate appears large but has a relatively normal appearance. If this pet was neutered after puberty, this could be within normal limits. If neutered prior to puberty, consider a fine needle aspirate, as prostatic neoplasia cannot be ruled out.

## INTERPRETATION OF THE FINDINGS & FURTHER RECOMMENDATIONS

The stomach is severely fluid distended and there is a section of bowel most consistent with proximal duodenum with intraluminal shadowing material most consistent with a foreign body obstruction. Correlate these findings with abdominal radiographs. If clinically appropriate, consider surgical evaluation for possible foreign body. If this is not possible, consider continued medical treatment in hopes that foreign material can pass with close monitoring and serial imaging (radiographs +/- ultrasound). Consider a recheck ultrasound in 12-24 hours.

There is a small amount of free abdominal fluid and a prominent mesenteric lymph node. This is likely secondary to focal inflammation and peritonitis secondary to the foreign body. The prostate appears somewhat large for a neutered dog of this size. If the patient was neutered prior to puberty, consider a fine needle aspirate of the prostate to rule out prostatic neoplasia.





The information and recommendations provided are based on the images presented by the referring veterinarian/sonographer. No evaluation can be communicated regarding pathology that was not visible in the image/video clips provided.

Thank you for this referral. If the clinical or image interpretation does not parallel your findings or if I can be of any further assistance please contact me.

Kathleen Sennello DVM,MS, Diplomate ACVIM (Small animal Internal Medicine)  
info@sonopath.com