

**DATE PRESENTING CLINICAL SIGNS**

6/29/23

Started vomiting yesterday AM - other dog in the household was also vomiting, puppy that pulled down bag of gummy candy - organic candy, patient didn't appear to have eaten any of it 3p yesterday: started vomiting bile and blood - was 3-4x. Only fed small meal with chicken in it - did eat the chicken - did vomit some of this up this AM Around 1p today was bright red - 4-5 spots around the floor Owner got back on Friday so she was boarded for 6 days - unsure if she got something different there Caught 2 days - pulled piece of molding off and was chewing on the wall Typically put everything up if dogs are left alone No medications or known health condition.

**PATIENT**

Cookie Litteral

**SPECIES**

Canine

**BREED**

Cockapoo

**SEX**

Spayed Female

**AGE**

3/1/18

**WEIGHT**

32 Pounds

**INTERPRETED BY**

Kathleen Sennello DVM,  
MS, Diplomate ACVIM  
(Small Animal Internal  
Medicine)

**HOSPITAL NAME**

Animal Emergency  
Hospital

**REFERRING VET**

Dr. Nacke-Horney

**INVOICE**

43592

Current Medications: Sucralfate, Unasyn, Protonix, Cerenia.  
Lab Results: Mild to moderate increased LE's.  
Radiographs: Mild hepatomegaly.  
Date of Previous IntraPet Ultrasound: No previous.  
Sedation: Not required to complete full diagnostic ultrasound.  
Stat Report: Not requested.  
Imaging Performed By: Rachel Brillhart, RDMS.

**ULTRASONOGRAPHIC EXAMINATION OF THE ABDOMEN****Urinary System**

The urinary bladder is moderately distended with anechoic urine. The Bladder wall, trigone, ureteral papillae and visible urethra (to a depth of 2cm) appear normal with no evidence of wall thickening, mucosal irregularities, masses or cystic calculi.

The left kidney has a normal shape and size 5.24 cm). Overall echogenicity is normal with adequate corticomedullary distinction and a typical 1:3 cortex:medulla ratio. There is no evidence of focal perinephric inflammation or effusion. There is no evidence of pyelectasia, nephroliths, infarcts or hydroureter. Renal vasculature is normal.

The right kidney has a normal shape and size (5.07 cm). Overall echogenicity is normal with adequate corticomedullary distinction and a typical 1:3 cortex:medulla ratio. There is no evidence of focal perinephric inflammation or effusion. There is no evidence of pyelectasia, nephroliths, infarcts or hydroureter. Renal vasculature is normal.

**Adrenal Glands**

The left adrenal gland is normal in size measuring 0.60 cm at the caudal pole. It is observed in its normal position cranial to the left renal artery. It is normal in appearance (uniformly hypoechoic) and shape with no evidence of a mass effect.

The right adrenal gland is normal in size measuring 0.57 cm at the caudal pole. It is observed in its normal position between the cranial aspect of the right kidney and the caudal vena cava. It is normal in appearance (uniformly hypoechoic) and shape with no evidence of a mass effect.

**Spleen**

The spleen is subjectively normal in size, echotexture is homogenous, and the splenic capsule is smooth with no irregularities. The blood flow through the hilus and splenic parenchyma appears normal. No focal parenchymal abnormalities are visualized.

**Liver**

The liver is subjectively normal in size, and echogenicity with smooth peripheral margins. The parenchyma is homogenous echotexture. The visible portions of the vasculature and biliary tract appear normal. No focal nodules or cystic lesions are observed.

The gallbladder lumen is moderately distended. The wall of the gall bladder is not thickened and has a smooth mucosal surface. Luminal contents are mild and primarily anechoic. The cystic and common bile ducts are normal/not visible.

### ***Gastrointestinal***

The stomach contains minimal luminal contents. It measures at a normal thickness of <0.7cm with some variability due to the presence of rugal folds. The distinction of the gastric wall layers is adequate and there is no impression of reduced peristaltic activity. No masses or focal lesions were observed.

The visualized areas of duodenum, jejunum and ileum have a relatively uniform diameter with minimal fluid distension. Wall thickness is normal. Bowel loops follow a curvilinear path with distinct wall layering maintaining the typical 1:3 muscularis:mucosa layer ratio. Duodenum wall measures 0.39 cm. Jejunum wall measures 0.32 cm. Visualized peristalsis appears appropriate. There were no focal lesions consistent with obstruction or a mass effect observed.

The ileocecal junction was visualized and exhibited normal intact wall layering and is subjectively of normal thickness. Sections of colon are visualized with formed fecal material and gas shadowing distally. There is no observed focal or generalized colon wall thickening or loss of layering.

### ***Pancreas***

The pancreas is prominent and mottled compared to the surrounding isoechoic mesentery. There is no evidence of nodules or cystic lesions. There is no evidence of regional mesenteric inflammation or fluid.

### ***Free Abdomen***

Evaluation of the peritoneal cavity did not reveal any evidence of effusion, or subjective lymphadenomegaly. The Medial iliac nodes appear normal and there was no evidence of a caudal aortic thrombus at the bifurcation. The omentum is of normal uniform echogenicity.

## **ULTRASONOGRAPHIC FINDINGS**

- Mildly mottled pancreas – The pancreatic changes are most consistent with age-related parenchymal remodeling, potentially secondary to a prior inflammatory episode, early fibrosis or chronic pancreatitis.

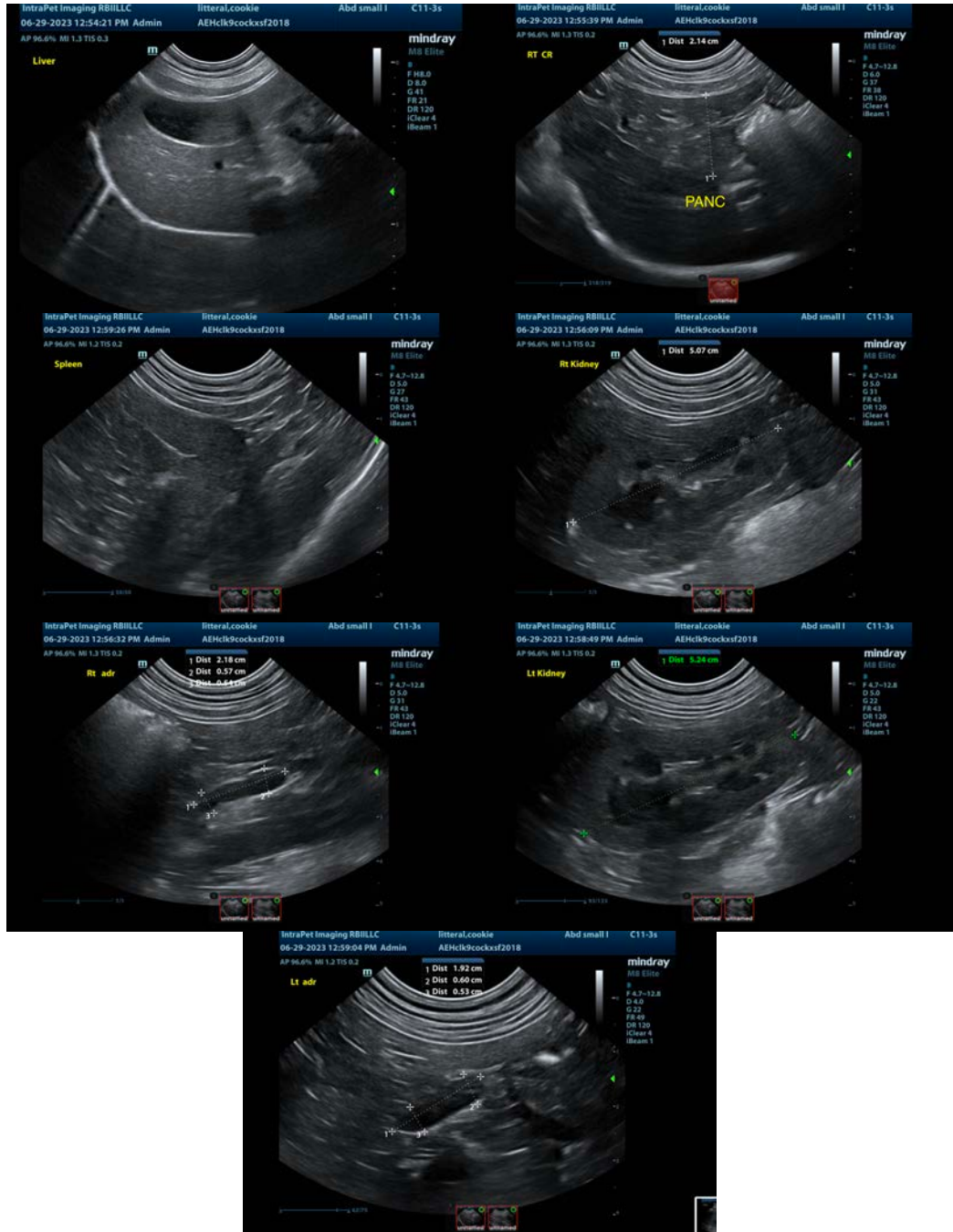
## **INTERPRETATION OF THE FINDINGS & FURTHER RECOMMENDATIONS**

No focal lesions are visualized associated with the liver to explain the liver enzyme elevations reported. Additionally, no focal lesions are visualized associated with the gastrointestinal tract to explain the acute vomiting. The pancreas appears slightly prominent, but there is minimal surrounding inflammation. These changes could be consistent with mild active inflammation or previous episodes of inflammation.

Unfortunately, there are many causes for acute vomiting and liver enzyme elevations that cannot be definitively diagnosed by ultrasound alone.

Consider such differentials as food allergy/dietary intolerance, GI parasitism, acute pancreatitis, dietary indiscretion, non-specific gastroenteritis, ingested foreign material, IBD and less likely neoplasia, etc....

Given the concurrent liver enzyme elevation, dietary indiscretion would have to be a primary differential. Recommend treatment for acute gastroenteritis/acute liver injury with IV fluids, anti-nausea medications, antibiotics if indicated, etc. If the patient is not improving, consider serial imaging (radiographs +/- ultrasound) and lab work to try and determine the next step.



The information and recommendations provided are based on the images presented by the referring veterinarian/sonographer. No evaluation can be communicated regarding pathology that was not visible in the image/video clips provided.

Thank you for this referral. If the clinical or image interpretation does not parallel your findings or if I can be of any further assistance please contact me.

Kathleen Sennello DVM,MS, Diplomate ACVIM (Small animal Internal Medicine)  
 info@sonopath.com