



PATIENT

Addie French

SPECIES

Canine

BREED

Terrier X

SEX

Spayed Female

AGE

6 Years

WEIGHT

72.6

INTERPRETED BY

Kathleen Sennello DVM,
MS, Diplomate ACVIM
(Small Animal Internal
Medicine)

**IMAGING
PERFORMED BY**

Dr. Sheldon

HOSPITAL NAME

Advanced PetCare of
Oakland

REFERRING VET

Dr. Sheldon

INVOICE

43615

DATE

6/30/23

PRESENTING CLINICAL SIGNS

cbc/t4 nsf, chems HI alb 4.1(historically above normal limits), HI alp 525(trending up normal last 2020 at 105, but then 253, 316 last year)

ULTRASONOGRAPHIC EXAMINATION OF THE ABDOMEN

Urinary System

The urinary bladder is moderately distended with anechoic urine. The Bladder wall, trigone, ureteral papillae and visible urethra (to a depth of 2cm) appear normal with no evidence of wall thickening, mucosal irregularities, or masses. In the dependent portion of the urinary bladder, there is a large amount of hyperechoic shadowing debris, most consistent with sandy debris/small stones. These are mobile and are initially visualized sitting with the trigone with some of the sandy debris extending into the urethra.

The left kidney has a normal shape and size (6.32 cm). Overall echogenicity is normal with adequate corticomedullary distinction and a typical 1:3 cortex:medulla ratio. There is no evidence of focal perinephric inflammation or effusion. There is no evidence of pyelectasia, nephroliths, infarcts or hydroureter. Renal vasculature is normal.

The right kidney has a normal shape and size (7.07 cm). Overall echogenicity is normal with adequate corticomedullary distinction and a typical 1:3 cortex:medulla ratio. There is no evidence of focal perinephric inflammation or effusion. There is no evidence of pyelectasia, nephroliths, infarcts or hydroureter. Renal vasculature is normal.

Adrenal Glands

The left adrenal gland is normal in size measuring 0.48 cm at the caudal pole. It is observed in its normal position cranial to the left renal artery. It is normal in appearance (uniformly hypoechoic) and shape with no evidence of a mass effect.

The region of the right adrenal (between right cranial kidney and vena cava) is unremarkable, but the adrenal is not distinctly visualized. No evidence of a mass effect is visualized.

Spleen

The spleen is subjectively normal in size, echotexture is homogenous, and the splenic capsule is smooth with no irregularities. The blood flow through the hilus and splenic parenchyma appears normal. No focal parenchymal abnormalities are visualized.

Liver

The liver is subjectively normal in size, and echogenicity with smooth peripheral margins. The parenchyma is homogenous echotexture. The visible portions of the vasculature and biliary tract appear normal. No focal nodules or cystic lesions are observed.

The gallbladder lumen is moderately distended. The wall of the gall bladder is not thickened and has a smooth mucosal surface. Luminal contents are mild and primarily anechoic. The cystic and common bile ducts are normal/not visible.



PATIENT *Gastrointestinal*

Addie French
The stomach contains minimal luminal contents. It measures at a normal thickness of <0.7cm with some variability due to the presence of rugal folds. The distinction of the gastric wall layers is adequate and there is no impression of reduced peristaltic activity. No masses or focal lesions were observed.

SPECIES

Canine

The visualized areas of duodenum, jejunum and ileum have a relatively uniform diameter with minimal fluid distension. Wall thickness is normal. Bowel loops follow a curvilinear path with distinct wall layering maintaining the typical 1:3 muscularis:mucosa layer ratio. Duodenum wall measures 0.60 cm. Jejunum wall measures 0.44 cm. Visualized peristalsis appears appropriate. There were no focal lesions consistent with obstruction or a mass effect observed.

BREED

Terrier X

SEX

Spayed Female

The ileocecal junction was visualized and exhibited normal intact wall layering and is subjectively of normal thickness. Sections of colon are visualized with formed fecal material and gas shadowing distally. There is no observed focal or generalized colon wall thickening or loss of layering.

AGE

6 Years

Pancreas

The pancreas is normal and isoechoic to surrounding mesentery. There is no evidence of nodules or cystic lesions. There is no evidence of regional mesenteric inflammation or fluid.

WEIGHT

72.6

Free Abdomen

Evaluation of the peritoneal cavity did not reveal any evidence of effusion, or subjective lymphadenomegaly. The Medial iliac nodes appear normal and there was no evidence of a caudal aortic thrombus at the bifurcation. The omentum is of normal uniform echogenicity.

INTERPRETED BY

Kathleen Sennello DVM,
MS, Diplomate ACVIM
(Small Animal Internal
Medicine)

ULTRASONOGRAPHIC FINDINGS

- Dependent sandy debris/small stones visualized in the urinary bladder - Correlate with abdominal radiographs, urinalysis and culture.

IMAGING PERFORMED BY

Dr. Sheldon

INTERPRETATION OF THE FINDINGS & FURTHER RECOMMENDATIONS

No significant abnormalities are visualized associated with the liver to explain the elevation in ALP reported. Additionally, the gallbladder and biliary tract appears normal. Consider the following recommendations for potential further evaluation of a primary ALP elevation:

HOSPITAL NAME

Advanced PetCare of
Oakland

- Induction phenomena are the most common cause for an elevation in ALP. These are systemic illnesses that 'turn on' the liver enzyme. Causes of this include Cushing's disease, dental disease, arthritis, and numerous others. In many cases the exact cause is unclear but as long as ultrasound and bile acids tests are normal most patients do not have progressive changes in their liver. While liver biopsy is not routinely performed, vacuolar hepatopathy, is noted on most biopsies. This is often non-progressive but in rare cases can be more severe and lead to liver failure.

REFERRING VET

Dr. Sheldon

- If signs of cushings disease are present recommend endocrine function testing to evaluate for cushings disease.

INVOICE

43615

- Consider fine needle aspirate to rule out round cell neoplasia -if this is a concern.

DATE

6/30/23

- If a cause for the ALP elevation is not identified: I recommend recheck general blood work every 6 months, ultrasound once per year, and bile acids test every 1-2 years based on other results. If the ALP continues to climb a biopsy could be considered.

- Consider long term use of denamarin, and monitoring for the signs of cushings developing.



PATIENT

Addie French

SPECIES

Canine

BREED

Terrier X

SEX

Spayed Female

AGE

6 Years

WEIGHT

72.6

INTERPRETED BY

Kathleen Sennello DVM,
MS, Diplomate ACVIM
(Small Animal Internal
Medicine)

**IMAGING
PERFORMED BY**

Dr. Sheldon

HOSPITAL NAME

Advanced PetCare of
Oakland

REFERRING VET

Dr. Sheldon

INVOICE

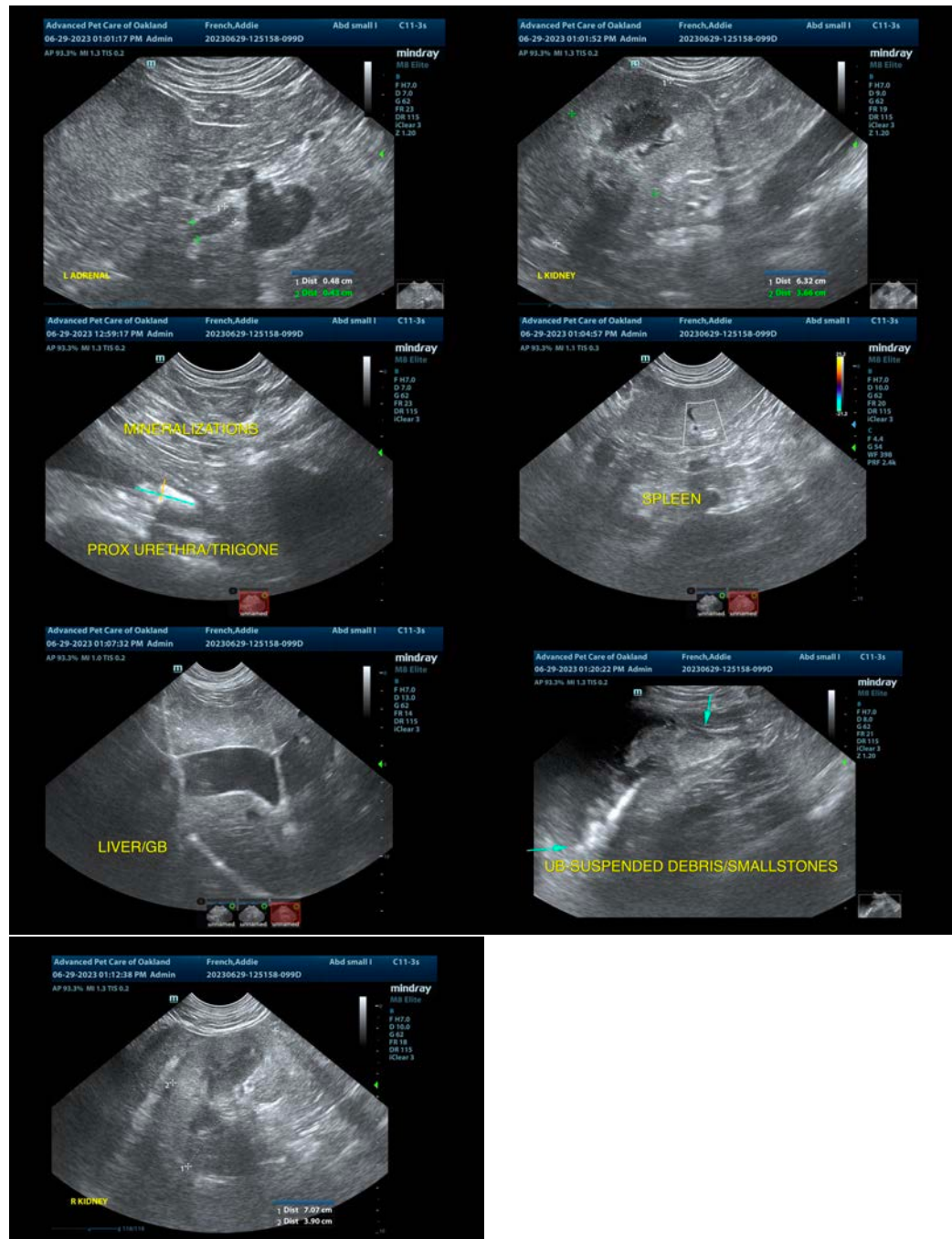
43615

DATE

6/30/23

- A primary vacuolar hepatopathy can be breed related and is seen in Scottish Terriers, Schnauzers, Cocker spaniels etc..

There is a large amount of sandy debris/small stones in the dependent portion of the urinary bladder. I suspect much of this is small enough to pass, and some of this mineralized debris is visualized within the proximal urethra. Recommend a urinalysis on a voided urine sample and a urine culture with continued monitoring for progression of the mineralization or clinical signs.





PATIENT

Addie French

The information and recommendations provided are based on the images presented by the referring veterinarian/sonographer. No evaluation can be communicated regarding pathology that was not visible in the image/video clips provided.

SPECIES

Canine

Thank you for this referral. If the clinical or image interpretation does not parallel your findings or if I can be of any further assistance please contact me.

BREED

Terrier X

Kathleen Sennello DVM,MS, Diplomate ACVIM (Small animal Internal Medicine)

info@sonopath.com

SEX

Spayed Female

AGE

6 Years

WEIGHT

72.6

INTERPRETED BY

Kathleen Sennello DVM,
MS, Diplomate ACVIM
(Small Animal Internal
Medicine)

**IMAGING
PERFORMED BY**

Dr. Sheldon

HOSPITAL NAME

Advanced PetCare of
Oakland

REFERRING VET

Dr. Sheldon

INVOICE

43615

DATE

6/30/23