



Portable Animal Wellness Sonography, Inc.

IMAGING PERFORMED BY

[pawsonography@gmail.com](mailto:pawsonography@gmail.com) 530-786-8340

## PATIENT

Mayhem Hertsens

## SPECIES

Canine

## BREED

Chihuahua

## SEX

Spayed Female

## AGE

14 Years

## WEIGHT

9.9 Pounds

## INTERPRETED BY

Kathleen Sennello DVM,  
MS, Diplomate ACVIM  
(Small Animal Internal  
Medicine)

## IMAGING BY

Loetitia Saint-Jacques,  
I VT

## HOSPITAL NAME

Alpine AH

## REFERRING VET

Dr. Lindsay Sjloin

## INVOICE

39097

## DATE

6/29/22

## PRESENTING CLINICAL SIGNS

Hyporexia according to the owner. Increasing anxiety in the car  
Physical exam findings: Stable weight. BARH. Moderate calculus. Many teeth missing from previous extractions. Abdomen soft and nonpainful  
Abnormal CBC values: mild thrombocytosis  
Abnormal Chemistry Values: mild ALT elevation. Worsening from last year  
Abnormal UA Values: WNL. Well concentrated  
Radiograph Findings(email radiographs if available): N/A  
Reason for Ultrasound: Evaluate for cause of hyporexia and mild ALT elevation (hepatic vs extra hepatic)

## ULTRASONOGRAPHIC EXAMINATION OF THE ABDOMEN

### Urinary System

The urinary bladder is moderately distended with anechoic urine. The Bladder wall, trigone, ureteral papillae and visible urethra (to a depth of 2cm) appear normal with no evidence of wall thickening, mucosal irregularities, masses or cystic calculi.

The left kidney has a normal shape and size (3.4 cm). Overall echogenicity is slightly hyperechoic with poor corticomedullary distinction and a typical 1:3 cortex:medulla ratio. There is no evidence of perinephric inflammation or effusion. There is no evidence of pyelectasia, nephroliths, infarcts or hydroureter. Renal vasculature is normal.

The right kidney has a normal shape and size (3.81 cm). Overall echogenicity is slightly hyperechoic with poor corticomedullary distinction and a typical 1:3 cortex:medulla ratio. There is no evidence of perinephric inflammation or effusion. There is no evidence of pyelectasia, nephroliths, infarcts or hydroureter. Renal vasculature is normal.

### Adrenal Glands

The left adrenal gland is normal in size measuring 0.65 cm at the caudal pole. It is observed in its normal position cranial to the left renal artery. It is normal in appearance (uniformly hypoechoic) and shape with no evidence of a mass effect.

The right adrenal gland is normal in size measuring 0.58 cm at the caudal pole. It is observed in its normal position between the cranial aspect of the right kidney and the caudal vena cava. It is normal in appearance (uniformly hypoechoic) and shape with no evidence of a mass effect.

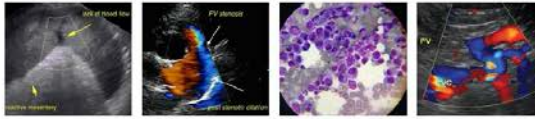
### Spleen

The spleen is subjectively normal in size, echotexture is homogenous, and the splenic capsule is smooth with no irregularities. The blood flow through the hilus and splenic parenchyma appears normal. There is an ill-defined, hypoechoic intraparenchymal nodule visualized measuring 0.90 cm x 1.3 cm.

### Liver

The liver is subjectively normal in size, and echogenicity with smooth peripheral margins. The parenchyma is mildly heterogenous in echotexture with subtle, indistinct focal mottling. The visible portions of the vasculature and biliary tract appear normal. There is a hyperechoic ill-defined nodule in the right caudate lobe visualized measuring 0.86 cm x 0.74 cm.

The gall bladder lumen is significantly distended. Some areas of the wall appear mildly thickened with adherent debris. There is a large amount of primarily non-organized echogenic debris. There



## PATIENT

Mayhem Hertsens

is no evidence of bile duct dilation. These changes can be consistent with an early gall bladder mucocele.

## SPECIES

Canine

### **Gastrointestinal**

The stomach contains mild to moderate fluid. It measures at a normal thickness of <0.7cm with some variability due to the presence of rugal folds. The distinction of the gastric wall layers is adequate and there is no impression of reduced peristaltic activity. No masses or focal lesions were observed.

## BREED

Chihuahua

The visualized areas of duodenum, jejunum and ileum have a relatively uniform diameter with minimal fluid distension. Wall thickness is normal. Bowel loops follow a curvilinear path with distinct wall layering maintaining the typical 1:3 muscularis:mucosa layer ratio. Jejunum wall measured 0.25 cm. Visualized peristalsis appears appropriate. There were no focal lesions consistent with obstruction or a mass effect observed.

## SEX

Spayed Female

The ileocecal junction was visualized and exhibited normal intact wall layering and is subjectively of normal thickness. Sections of colon are visualized with formed fecal material and gas shadowing distally. There is no observed focal or generalized colon wall thickening or loss of layering.

## AGE

14 Years

### **Pancreas**

The pancreas is prominent and mottled compared to the surrounding isoechoic mesentery. There is no evidence of nodules or cystic lesions. There is no evidence of regional mesenteric inflammation or fluid.

## WEIGHT

9.9 Pounds

### **Free Abdomen**

Evaluation of the peritoneal cavity did not reveal any evidence of effusion, or subjective lymphadenomegaly. Relatively normal lymph nodes are visualized measuring 0.29 cm and 0.37 cm. The omentum is of normal uniform echogenicity.

## INTERPRETED BY

Kathleen Sennello DVM,  
MS, Diplomate ACVIM  
(Small Animal Internal  
Medicine)

### **Other**

A brief view of the heart was submitted. No significant pericardial effusion was seen.

## PRIMARY FINDINGS

### IMAGING BY

Loetitia Saint-Jacques,  
I/VT

- Ill-defined hypoechoic nodule in the spleen – There is a non-cavitated, hypoechoic splenic nodule visualized. Differentials include lymphoid hyperplasia, extramedullary hematopoiesis, infiltrative neoplasia, inflammation, other. Cytology or histopathology would be necessary to get a definitive diagnosis.

### HOSPITAL NAME

Alpine AH

- Prominent, mottled pancreas – The pancreatic changes are most consistent with mild pancreatitis or a recent episode of pancreatic inflammation.

### REFERRING VET

Dr. Lindsay Sjloin

- Mildly heterogeneous liver with a hyperechoic nodule in the caudate lobe – The diffuse hepatic changes are non-specific and could be consistent with vacuolar hepatopathy, nodular hyperplasia, inflammatory/immune-mediated disease, fibrosis, extramedullary hematopoiesis, toxic hepatopathy (e.g., copper), infiltrative neoplasia (less likely) or other hepatopathy.

## INVOICE

39097

## DATE

6/29/22



**PATIENT**

Mayhem Hertsens

- Moderate gallbladder debris - The significance of the aggregated gallbladder sludge is unclear. This could represent an early mucocele, cholestasis, or may be secondary to fasting.

**SPECIES**

Canine

**SECONDARY FINDINGS**

**BREED**

Chihuahua

- Decreased corticomedullary distinction in both kidneys – The bilateral renal findings are consistent with age-related change.
- Mild fluid distention of the gastric lumen – correlate with eating/drinking history. If the patient was adequately fasted, consider such differentials as delayed gastric, gastric foreign material, etc.

**SEX**

Spayed Female

**INTERPRETATION OF THE FINDINGS & FURTHER RECOMMENDATIONS**

**AGE**

14 Years

An obvious cause for the decrease in appetite in elevation in ALT is not readily explained by today's scan. The liver is mildly heterogeneous, and there is an ill-defined, hyperechoic nodule visualized in the right side. Subjectively, this nodule trends towards a more benign appearance. You could look into this further by performing a liver function test and a fine needle aspirate of the liver.

**WEIGHT**

9.9 Pounds

The gallbladder has a moderate amount of debris, but no surrounding inflammation, and the gallbladder wall appears relatively normal. Recommend continued monitoring of the gallbladder +/- chronic Ursodiol therapy.

**INTERPRETED BY**

Kathleen Sennello DVM,  
MS, Diplomate ACVIM  
(Small Animal Internal  
Medicine)

There is an ill-defined hypoechoic nodule in the spleen. This does not deform the splenic capsule. Options moving forward include continued monitoring or a fine needle aspirate of the spleen.

**IMAGING BY**

Loetitia Saint-Jacques,  
I/VT

No focal lesions were observed regarding the gastrointestinal tract. Unfortunately, you can still have significant gastrointestinal disease and a relatively normal ultrasonographic appearance to the GI tract. If gastrointestinal disease is suspected, then consider a GI panel to Texas A&M for a qualitative PLI, TLI, cobalamin and folate to further evaluate the pancreas and small intestine. Consider a novel protein/hydrolyzed protein prescription, and correlate the mild gastric dilation with abdominal radiographs, as some types of foreign material are difficult to identify based on ultrasound alone.

**HOSPITAL NAME**

Alpine AH

The spleen is prominent and mottled. At this time, I would recommend symptomatic treatment for pancreatitis while awaiting a qualitative PLI level.

**REFERRING VET**

Dr. Lindsay Sjloin

**INVOICE**

39097

**DATE**

6/29/22



Portable Animal Wellness Sonography, Inc.

IMAGING PERFORMED BY  
pawsonography@gmail.com 530-786-8340

**PATIENT**

Mayhem Hertsens

**SPECIES**

Canine

**BREED**

Chihuahua

**SEX**

Spayed Female

**AGE**

14 Years

**WEIGHT**

9.9 Pounds

**INTERPRETED BY**

Kathleen Sennello DVM,  
MS, Diplomate ACVIM  
(Small Animal Internal  
Medicine)

**IMAGING BY**

Loetitia Saint-Jacques,  
I VT

**HOSPITAL NAME**

Alpine AH

**REFERRING VET**

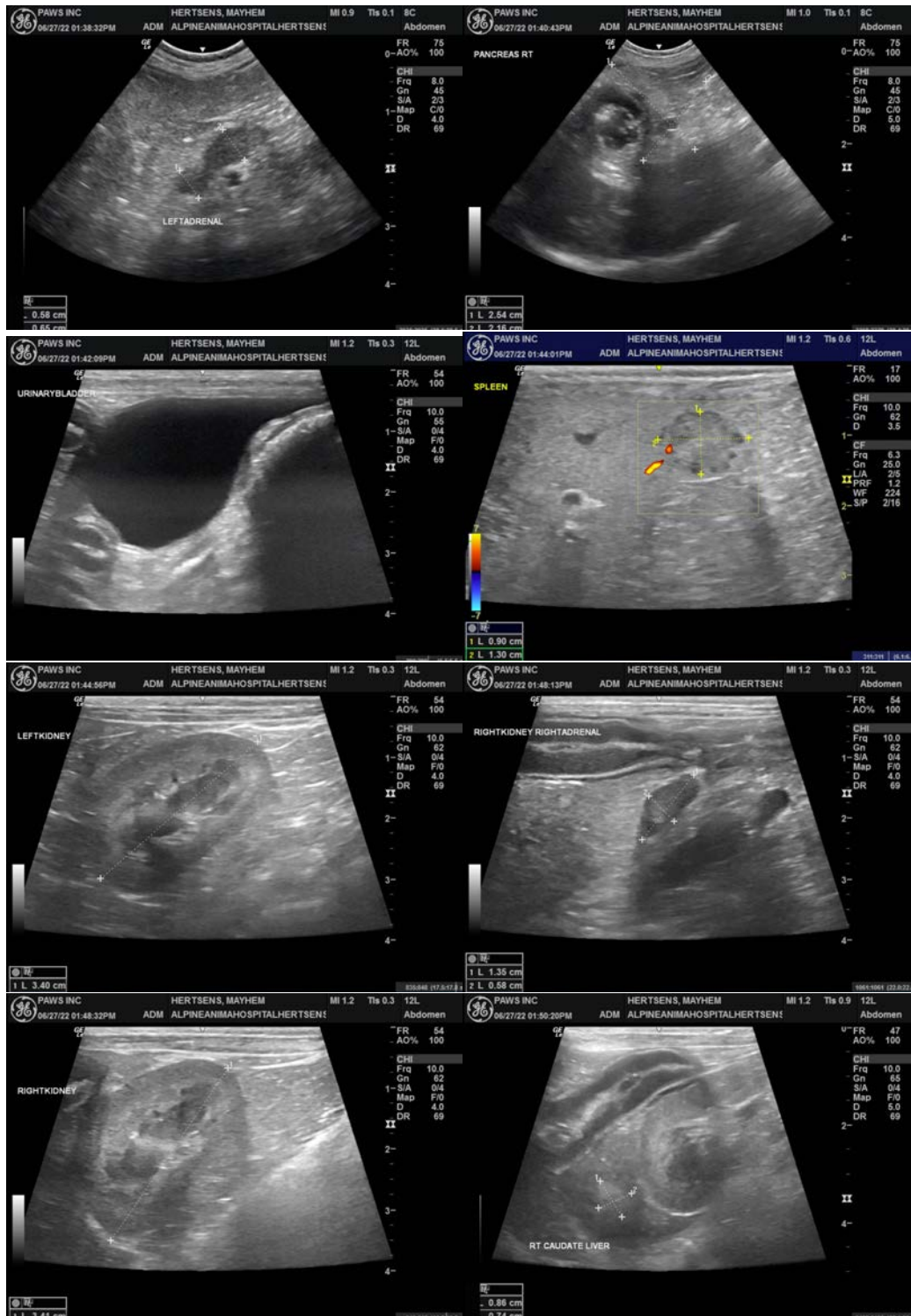
Dr. Lindsay Sjloin

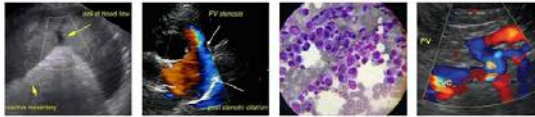
**INVOICE**

39097

**DATE**

6/29/22





**PATIENT**

Mayhem Hertsens

**SPECIES**

Canine

**BREED**

Chihuahua

**SEX**

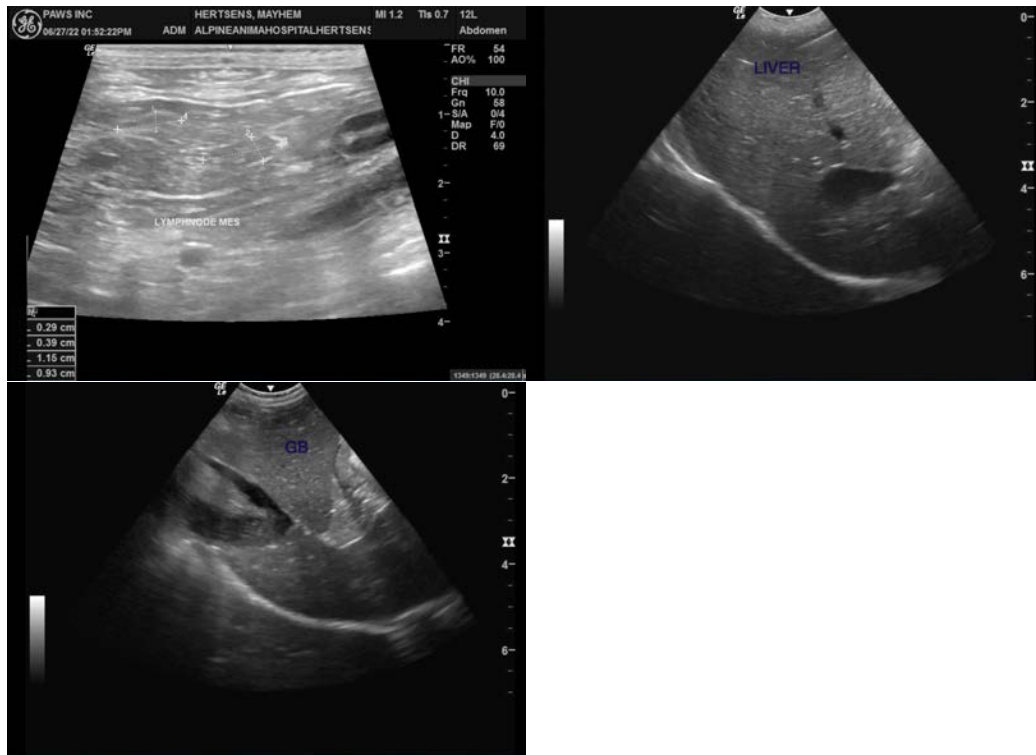
Spayed Female

**AGE**

14 Years

**WEIGHT**

9.9 Pounds



**INTERPRETED BY**

Kathleen Sennello DVM,  
MS, Diplomate ACVIM  
(Small Animal Internal  
Medicine)

The information and recommendations provided are based on the images presented by the referring veterinarian/sonographer. No evaluation can be communicated regarding pathology that was not visible in the image/video clips provided.

Thank you for this referral. If the clinical or image interpretation does not parallel your findings or if I can be of any further assistance please contact me.

**IMAGING BY**

Loetitia Saint-Jacques,  
I/VT

Kathleen Sennello DVM,MS, Diplomate ACVIM (Small animal Internal Medicine)  
kathleen.sennello@sonopath.com

**HOSPITAL NAME**

Alpine AH

**REFERRING VET**

Dr. Lindsay Sjloin

**INVOICE**

39097

**DATE**

6/29/22