

**DATE PRESENTING CLINICAL SIGNS**

6/28/23 Acute onset of Neurologic issues. Unable to walk. Xrays show abnormal calcification of the caudal abdomen.

PATIENT

Scout Rich Current Medications: Onsior 6mg (2 tabs SID)

Lab Results: See attached.

Date of Previous IntraPet Ultrasound: No previous.

SPECIES

Sedation: Not required to complete full diagnostic ultrasound.

Stat Report: Not requested.

Feline

Imaging Performed By: Rachel Brillhart, RDMS.

BREED**ULTRASONOGRAPHIC EXAMINATION OF THE ABDOMEN**

DSH

Urinary System

The urinary bladder is moderately distended with mild primarily suspended echogenic debris present. The

SEX

Bladder wall, trigone, ureteral papillae and visible urethra (to a depth of 2cm) appear normal with no

Neutered Male

evidence of wall thickening, mucosal irregularities, or masses. In the right dorsal area of the urinary bladder there appears to be some hyperechoic shadowing material measuring 0.37 cm. It is difficult to discern if this is intraluminal or associated with the bladder wall (adhered?) or extraluminal tissue.

AGE

The left kidney has a normal shape and size (4.95 cm). Overall echogenicity is slightly hyperechoic with mildly reduced corticomedullary distinction and a typical 1:3 cortex:medulla ratio. There is no evidence of focal perinephric inflammation or effusion. There is no evidence of pyelectasia, nephroliths, infarcts or hydroureter. Renal vasculature is normal.

7/2/15

WEIGHT

The right kidney has a normal shape and size (5.14 cm). Overall echogenicity is slightly hyperechoic with poor corticomedullary distinction and a typical 1:3 cortex:medulla ratio. There is no evidence of focal perinephric inflammation or effusion. There is no evidence of pyelectasia, nephroliths, infarcts or hydroureter. Renal vasculature is normal.

22 Pounds

INTERPRETED BY

Kathleen Sennello DVM,
MS, Diplomate ACVIM
(Small Animal Internal
Medicine)

Adrenal Glands

The left adrenal gland is normal in size measuring 0.41 cm at the caudal pole. It is observed in its normal position cranial to the left renal artery. It is normal in appearance (uniformly hypoechoic) and shape with no evidence of a mass effect.

HOSPITAL NAME

Greenbrier Vet Clinic

The right adrenal gland is normal in size measuring 0.48 cm at the caudal pole. It is observed in its normal position between the cranial aspect of the right kidney and the caudal vena cava. It is normal in appearance (uniformly hypoechoic) and shape with no evidence of a mass effect.

REFERRING VET

Dr. Streett

Spleen

The spleen is normal/borderline large (1.3 cm), echotexture is homogenous, and the splenic capsule is smooth with no irregularities. The blood flow through the hilus and splenic parenchyma appears normal. No focal parenchymal abnormalities are visualized.

INVOICE

43521

Liver

The liver is subjectively normal in size, and echogenicity with smooth peripheral margins. The parenchyma is homogenous echotexture. The visible portions of the vasculature and biliary tract appear normal. No focal nodules or cystic lesions are observed.

The gallbladder lumen is moderately distended. The wall of the gall bladder is not thickened and has a smooth mucosal surface. Luminal contents are mild and primarily anechoic. The cystic and common bile ducts are normal/not visible.

Gastrointestinal

The stomach contains minimal luminal contents. It measures at a normal thickness of <0.36cm with some variability due to the presence of rugal folds. The distinction of the gastric wall layers is adequate and there is no impression of reduced peristaltic activity. No masses or focal lesions were observed.

The visualized areas of duodenum, jejunum and ileum have a relatively uniform diameter with minimal fluid distension. Wall thickness is normal. Bowel loops follow a curvilinear path with distinct wall layering maintaining the typical 1:3 muscularis:mucosa layer ratio. Duodenum wall measures 0.36 cm. Jejunum wall measures 0.31 cm. Visualized peristalsis appears appropriate. There were no focal lesions consistent with obstruction or a mass effect observed.

The ileocecal junction was visualized and exhibited normal intact wall layering and is subjectively of normal thickness. Sections of colon are visualized with formed fecal material and gas shadowing distally. There is no observed focal or generalized colon wall thickening or loss of layering.

Pancreas

The pancreas is normal and isoechoic to surrounding mesentery. There is no evidence of nodules or cystic lesions. There is no evidence of regional mesenteric inflammation or fluid.

Free Abdomen

Evaluation of the peritoneal cavity did not reveal any evidence of effusion. Lymph nodes at the mesenteric root are somewhat prominent, measuring 0.35, 0.32, and 0.32 cm.

Other

There is a hyperechoic rounded structure visualized caudodorsal to the urinary bladder, measuring approximately 1.47 cm x 1.21 cm, possibly consistent with a bates body(?). Correlate with abdominal radiographs. Additionally, there is a shadowing, possibly mineralized area towards the right of the bladder, which appears somewhat extraluminal, possibly a small area of mineralized bladder wall, etc.

ULTRASONOGRAPHIC FINDINGS

- Echogenic debris in the urinary bladder – The echogenic debris in the bladder lumen could be consistent with cells, crystals, and/or mucus.
- Rounded hyperechoic shadowing structure caudodorsal to the urinary bladder – The significance of this is unclear. This could be consistent with a bates body(?).
- Shadowing/possible mineralization visualized in the right dorsal area of the urinary bladder – This could be a focal area of mineralization, mineralized bladder wall, etc. The significance is uncertain.
- Mildly reduced corticomedullary distinction in both kidneys – The bilateral renal findings are consistent with age-related change.
- Prominent lymph nodes visualized at the mesenteric root – The prominent abdominal lymph nodes are most consistent with reactive lymphadenitis or lymphoid hyperplasia. Neoplastic infiltration is considered less likely.
- Borderline enlarged spleen – I suspect this is appropriate for this size cat. A fine needle aspirate could be considered.

INTERPRETATION OF THE FINDINGS & FURTHER RECOMMENDATIONS

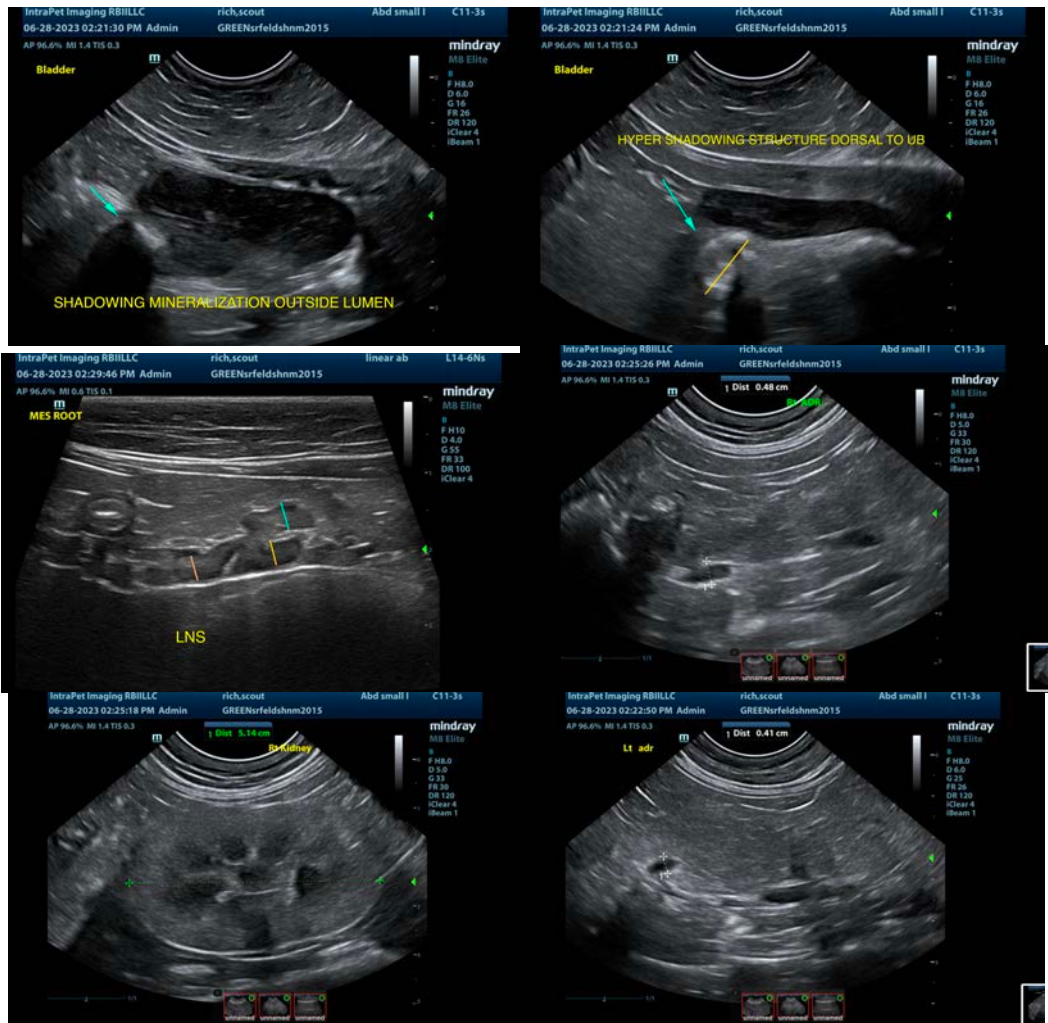
There is a significant amount of echogenic debris visualized in the urinary bladder.

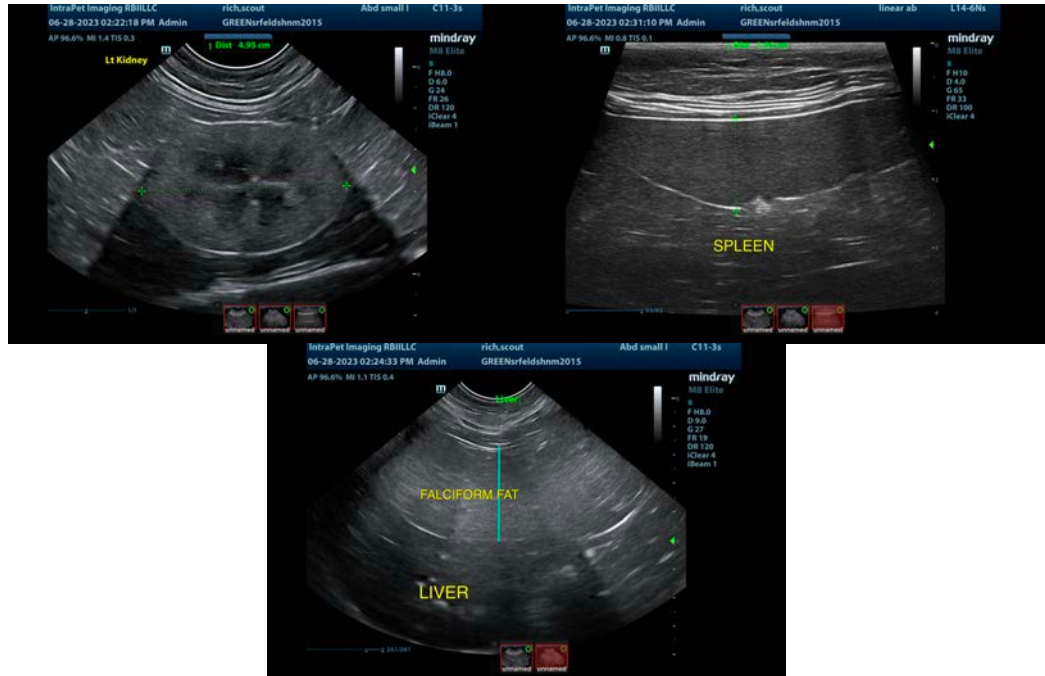
The history describes “abnormal calcification of the caudal abdomen”. It is not clear if this represents mineralized structures, generalized mineralization, etc. Ultrasound can be an insensitive modality for evaluating calcification, as the ultrasound beam does not penetrate well. There does appear to be a rounded structure in the dorsocaudal aspect of the urinary bladder, possibly consistent with a bates body(?). Correlate if that is appropriate based on radiographs. Additionally, there is some questionable mineralization in the right dorsal aspect of the urinary bladder that may not be luminal. The significance of this is unclear, but most of these changes I suspect are somewhat incidental.

The spleen does appear somewhat enlarged, but this is a very large cat and likely within normal limits. Vasculature and parenchyma appear normal.

An obvious lesion resulting in an inability to walk is not evident. Recommend palpation for femoral pulses and consider referral to a veterinary neurologist for further evaluation, provided cardiac disease is thought unlikely.

Recommend a urinalysis and culture (cysto performed during the exam).





The information and recommendations provided are based on the images presented by the referring veterinarian/sonographer. No evaluation can be communicated regarding pathology that was not visible in the image/video clips provided.

Thank you for this referral. If the clinical or image interpretation does not parallel your findings or if I can be of any further assistance please contact me.

Kathleen Sennello DVM,MS, Diplomate ACVIM (Small animal Internal Medicine)
info@sonopath.com