



PATIENT PRESENTING CLINICAL SIGNS

Puffin Harvey

Seen for weight loss, some new stressors at home (dog and new cat). Inappropriate defecation - stress vs IBD vs cognitive vs pain. Tail swellings -osteosarcoma or soft tissue? Radiographs approved and taken of tail and abdomen and spine. Soft tissue swellings noted at Coccygeal vertebra 15/16 and 16/17 at IVDD space. CO 15 shows mild lysis of distal region of vertebral body. Lesion? Trauma? No fractures seen. Abdominal rads - kidneys seem a little radio opaque, something in stomach? (but confirmed did not eat in last 10 hours). Chronic IBD cat. Has been on Gabapentin, Metronidazole, Therabites feline hip and joint chews and Metacam 6kg dose SID.

SPECIES

Feline

BREED

DLH

SEX

Spayed Female

AGE

13 Years

WEIGHT

5.3 kg

INTERPRETED BY

Kathleen Sennello DVM,
MS, Diplomate ACVIM
(Small Animal Internal
Medicine)

IMAGING PERFORMED BY

Crystal Hill

HOSPITAL NAME

Headon Forest AH

REFERRING VET

Dr. Corlett

INVOICE

43519

DATE

6/28/23

ULTRASONOGRAPHIC EXAMINATION OF THE ABDOMEN

Urinary System

The urinary bladder is moderately distended with anechoic urine. The Bladder wall, trigone, ureteral papillae and visible urethra (to a depth of 2cm) appear normal with no evidence of wall thickening, mucosal irregularities, masses or cystic calculi.

The left kidney is irregular in shape (likely due to previous infarcts), measuring 3.92 cm. Overall echogenicity is slightly hyperechoic with poor corticomedullary distinction and a typical 1:3 cortex:medulla ratio. There is no evidence of focal perinephric inflammation or effusion. There is no evidence of pyelectasia, nephroliths, infarcts or hydroureter. Renal vasculature is normal.

The right kidney is irregular in shape (likely due to previous infarcts), measuring 3.45 cm. Overall echogenicity is slightly hyperechoic with poor corticomedullary distinction and a typical 1:3 cortex:medulla ratio. There is no evidence of focal perinephric inflammation or effusion. There is no evidence of pyelectasia, nephroliths, infarcts or hydroureter. Renal vasculature is normal.

Adrenal Glands

The left adrenal gland is normal in size measuring 0.43 cm at the caudal pole. It is observed in its normal position cranial to the left renal artery. It is normal in appearance (uniformly hypoechoic) and shape with no evidence of a mass effect.

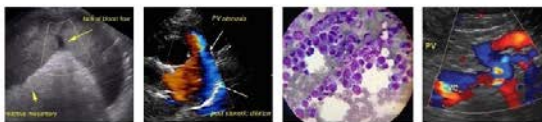
The right adrenal gland is normal in size measuring 0.46 cm at the caudal pole. It is observed in its normal position between the cranial aspect of the right kidney and the caudal vena cava. It is normal in appearance (uniformly hypoechoic) and shape with no evidence of a mass effect.

Spleen

The spleen is subjectively normal in size (0.46 cm), echotexture is homogenous, and the splenic capsule is smooth with no irregularities. The blood flow through the hilus and splenic parenchyma appears normal. No focal parenchymal abnormalities are visualized.

Liver

The liver is subjectively normal in size, and echogenicity with smooth peripheral margins. The parenchyma is homogenous echotexture. The visible portions of the vasculature and biliary tract appear normal. No focal nodules or cystic lesions are observed.



PATIENT

Puffin Harvey

The gallbladder lumen is moderately distended. The wall of the gall bladder is not thickened and has a smooth mucosal surface. Luminal contents are mild and primarily anechoic. The cystic and common bile ducts are normal/not visible.

SPECIES

Gastrointestinal

Feline

The stomach contains mild fluid and gas. It measures at a normal thickness of <0.36cm with some variability due to the presence of rugal folds. The distinction of the gastric wall layers is adequate and there is no impression of reduced peristaltic activity. No masses or focal lesions were observed.

BREED

DLH

The visualized areas of duodenum, jejunum and ileum have a relatively uniform diameter with minimal fluid distension. Wall thickness is normal. Bowel loops follow a curvilinear path with distinct wall layering maintaining the typical 1:3 muscularis:mucosa layer ratio. Jejunum wall measures 0.21 cm.

SEX

Spayed Female

Visualized peristalsis appears appropriate. There were no focal lesions consistent with obstruction or a mass effect observed.

AGE

13 Years

The ileocecal junction was visualized and exhibited normal intact wall layering and is subjectively of normal thickness. Sections of colon are visualized with formed fecal material and gas shadowing distally. There is no observed focal or generalized colon wall thickening or loss of layering.

WEIGHT

5.3 kg

Pancreas

The pancreas is prominent and mottled compared to the surrounding isoechoic mesentery. There is no evidence of nodules or cystic lesions. There is no evidence of regional mesenteric inflammation or fluid.

INTERPRETED BY

Kathleen Sennello DVM,
MS, Diplomate ACVIM
(Small Animal Internal
Medicine)

Free Abdomen

Evaluation of the peritoneal cavity did not reveal any evidence of effusion, or subjective lymphadenomegaly. The Medial iliac nodes appear normal and there was no evidence of a caudal aortic thrombus at the bifurcation. The omentum is of normal uniform echogenicity.

IMAGING PERFORMED BY

Crystal Hill

ULTRASONOGRAPHIC FINDINGS

- Decreased corticomedullary distinction in both kidneys with occasional infarcts – Mild loss of corticomedullary distinction in both kidneys could be consistent with chronic degenerative disease or interstitial nephrosis.
- Prominent, mottled pancreas – The pancreatic changes are most consistent with age-related parenchymal remodeling, potentially secondary to a prior inflammatory episode, early fibrosis or chronic pancreatitis.

HOSPITAL NAME

Headon Forest AH

REFERRING VET

Dr. Corlett

INTERPRETATION OF THE FINDINGS & FURTHER RECOMMENDATIONS

No large soft tissue mass lesions were visualized to explain the weight loss reported. The significance of the tail swellings is unknown. Consider consultation with a radiologist or orthopedist to better evaluate if bony lytic changes are suspected.

INVOICE

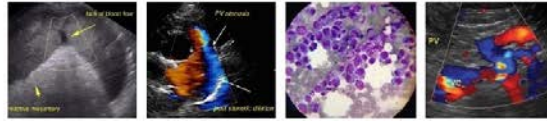
43519

There are changes visualized associated with both kidneys, likely consistent with chronic progressive age related renal disease. Recommend blood pressure, urinalysis and culture as a baseline.

DATE

6/28/23

The pancreas is slightly prominent but not overtly inflamed. These changes could be consistent with previous of pancreatitis or mild current pancreatic inflammation. Additionally, there is a small amount of fluid and shadowing material within the gastric lumen. This could be consistent with ingested foreign material, food, etc. No evidence of an obstruction is visualized.



PATIENT

Puffin Harvey

While no changes are visualized associated with the gastrointestinal tract, there can still be underlying small intestinal disease. If this is suspected, consider a GI panel to Texas A&M for a qualitative fPLI, TLI, cobalamin and folate to further evaluate.

SPECIES

Feline

Recommend three view thoracic radiographs to evaluate for possible concurrent thoracic disease/involvement.

BREED

DLH

SEX

Spayed Female

AGE

13 Years

WEIGHT

5.3 kg

INTERPRETED BY

Kathleen Sennello DVM,
 MS, Diplomate ACVIM
 (Small Animal Internal
 Medicine)

**IMAGING
 PERFORMED BY**

Crystal Hill

HOSPITAL NAME

Headon Forest AH

REFERRING VET

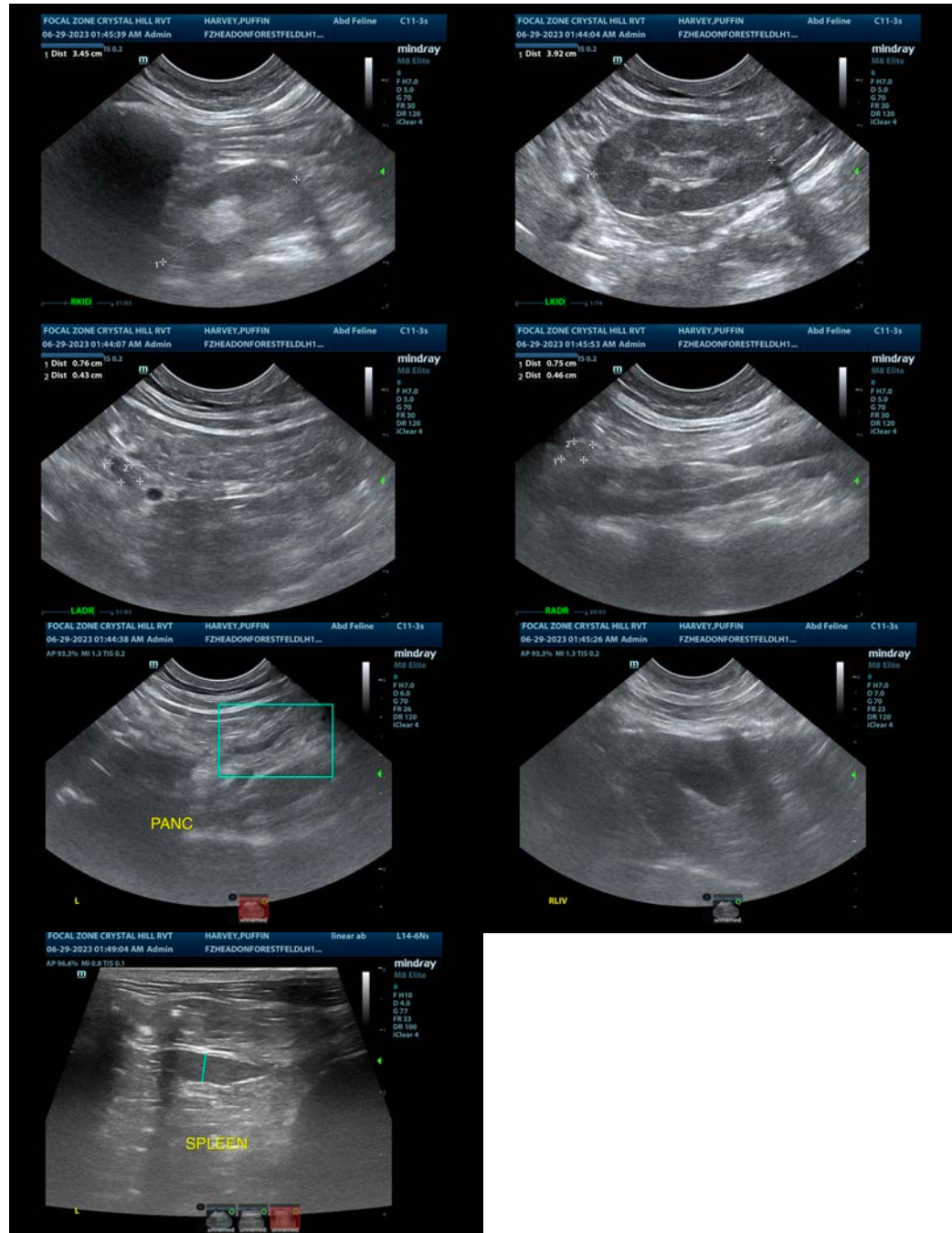
Dr. Corlett

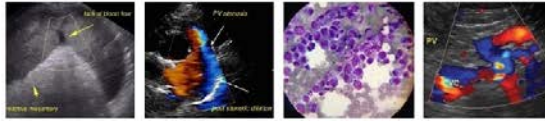
INVOICE

43519

DATE

6/28/23





PATIENT

Puffin Harvey

The information and recommendations provided are based on the images presented by the referring veterinarian/sonographer. No evaluation can be communicated regarding pathology that was not visible in the image/video clips provided.

SPECIES

Feline

Thank you for this referral. If the clinical or image interpretation does not parallel your findings or if I can be of any further assistance please contact me.

Kathleen Sennello DVM,MS, Diplomate ACVIM (Small animal Internal Medicine)

BREED

DLH

info@sonopath.com

SEX

Spayed Female

AGE

13 Years

WEIGHT

5.3 kg

INTERPRETED BY

Kathleen Sennello DVM,
MS, Diplomate ACVIM
(Small Animal Internal
Medicine)

**IMAGING
PERFORMED BY**

Crystal Hill

HOSPITAL NAME

Headon Forest AH

REFERRING VET

Dr. Corlett

INVOICE

43519

DATE

6/28/23