



PATIENT

Molly Lambie

SPECIES

Canine

BREED

Mini Schnauzer

SEX

Spayed Female

AGE

5 Years

WEIGHT

8.4 kg

INTERPRETED BY

Kathleen Sennello DVM,
MS, Diplomate ACVIM
(Small Animal Internal
Medicine)

**IMAGING
PERFORMED BY**

Dr. Sarah Barthelemy

HOSPITAL NAME

Cranston Vet Hospital

REFERRING VET

Dr. Parchello

INVOICE

43517

DATE

6/28/23

PRESENTING CLINICAL SIGNS

Has been drinking more lately and generally a bit quieter than usual. Cold seeking behavior, very good appetite. Recent episode vomiting and diarrhea in last 48 hours. Last year labs showed mild triglyceride elevation. Has been on low fat diet since last year.

Abnormal PE/Chem/CBC/UA Results: Elevated triglycerides at 6.47. Marked ALP elevation 3100 and Mild GGT elevation 27.

ULTRASONOGRAPHIC EXAMINATION OF THE ABDOMEN

Urinary System

The urinary bladder is moderately distended with anechoic urine. The Bladder wall, trigone, ureteral papillae and visible urethra (to a depth of 2cm) appear normal with no evidence of wall thickening, mucosal irregularities, or masses. In the dependent portion of the urinary bladder there are numerous hyperechoic shadowing foci, most consistent with small stones. One of these stones appears to measure approximately 0.49 cm. Correlate with abdominal radiographs.

The left kidney has a normal shape and size (4.95 cm). Overall echogenicity is normal with adequate corticomedullary distinction and a typical 1:3 cortex:medulla ratio. There is no evidence of focal perinephric inflammation or effusion. There is no evidence of pyelectasia, nephroliths, infarcts or hydroureter. Renal vasculature is normal.

The right kidney has a normal shape and size (5.33 cm). Overall echogenicity is normal with adequate corticomedullary distinction and a typical 1:3 cortex:medulla ratio. There is no evidence of focal perinephric inflammation or effusion. There is no evidence of pyelectasia, nephroliths, infarcts or hydroureter. Renal vasculature is normal.

Adrenal Glands

The left adrenal gland is normal in size measuring 0.51 cm at the caudal pole. It is observed in its normal position cranial to the left renal artery. It is normal in appearance (uniformly hypoechoic) and shape with no evidence of a mass effect.

The right adrenal gland is normal in size measuring 0.67 cm at the caudal pole. It is observed in its normal position between the cranial aspect of the right kidney and the caudal vena cava. It is normal in appearance (uniformly hypoechoic) and shape with no evidence of a mass effect.

Spleen

The spleen is subjectively normal in size, echotexture is homogenous, and the splenic capsule is smooth with no irregularities. The blood flow through the hilus and splenic parenchyma appears normal. No focal parenchymal abnormalities are visualized.

Liver

The liver is large in size, and normal in echogenicity with smooth peripheral margins. The parenchyma is heterogenous in echotexture with subtle, indistinct focal mottling. The visible portions of the vasculature and biliary tract appear normal. No focal nodules or cystic lesions are observed.



PATIENT

Molly Lambie

The gall bladder lumen is moderately distended. The wall of the gall bladder is not thickened and has a smooth mucosal surface. There is a moderate amount of non-organized echogenic debris. The cystic and common bile ducts are normal/not visible.

SPECIES

Canine

Gastrointestinal

The stomach contains minimal luminal contents. It measures at a normal thickness of <0.7cm with some variability due to the presence of rugal folds. The distinction of the gastric wall layers is adequate and there is no impression of reduced peristaltic activity. No masses or focal lesions were observed.

BREED

Mini Schnauzer

The visualized areas of duodenum, jejunum and ileum have a relatively uniform diameter with minimal fluid distension. Wall thickness is normal. Bowel loops follow a curvilinear path with distinct wall layering maintaining the typical 1:3 muscularis:mucosa layer ratio. Jejunum wall measures 0.29 cm. Visualized peristalsis appears appropriate. There were no focal lesions consistent with obstruction or a mass effect observed.

SEX

Spayed Female

AGE

5 Years

The ileocecal junction was visualized and exhibited normal intact wall layering and is subjectively of normal thickness. Sections of colon are visualized with formed fecal material and gas shadowing distally. There is no observed focal or generalized colon wall thickening or loss of layering.

WEIGHT

8.4 kg

Pancreas

The right limb of the pancreas is prominent and mottled compared to the surrounding isoechoic mesentery. There is no evidence of nodules or cystic lesions. There is no evidence of regional mesenteric inflammation or fluid.

INTERPRETED BY

Kathleen Sennello DVM,
MS, Diplomate ACVIM
(Small Animal Internal
Medicine)

Free Abdomen

Evaluation of the peritoneal cavity did not reveal any evidence of effusion, or subjective lymphadenomegaly. The Medial iliac nodes appear normal and there was no evidence of a caudal aortic thrombus at the bifurcation. The omentum is of normal uniform echogenicity.

IMAGING PERFORMED BY

Dr. Sarah Barthelemy

ULTRASONOGRAPHIC FINDINGS

- Focal hyperechoic shadowing mineralizations in the urinary bladder – Findings are consistent with small stones. Correlate with abdominal radiographs to better determine the size and number of stones present. Recommend urinalysis and culture.
- Prominent, mottled right limb of the pancreas – The pancreatic changes are most consistent with age-related parenchymal remodeling, potentially secondary to a prior inflammatory episode, early fibrosis or chronic pancreatitis.
- Large, heterogeneous liver – The diffuse hepatic changes are non-specific and could be consistent with vacuolar hepatopathy, nodular hyperplasia, inflammatory/immune-mediated disease, fibrosis, extramedullary hematopoiesis, toxic hepatopathy (e.g., copper), infiltrative neoplasia (less likely) or other hepatopathy.
- Moderate gallbladder debris – The significance of the aggregated gallbladder debris is unclear. This could represent an early mucocele, cholestasis, or may be secondary to fasting but seems unlikely to be causing a current issue. Recommend continued monitoring.

HOSPITAL NAME

Cranston Vet Hospital

REFERRING VET

Dr. Parchello

INVOICE

43517

DATE

6/28/23



PATIENT

Molly Lambie

SPECIES

Canine

BREED

Mini Schnauzer

SEX

Spayed Female

AGE

5 Years

WEIGHT

8.4 kg

INTERPRETED BY

Kathleen Sennello DVM,
MS, Diplomate ACVIM
(Small Animal Internal
Medicine)

**IMAGING
PERFORMED BY**

Dr. Sarah Barthelemy

HOSPITAL NAME

Cranston Vet Hospital

REFERRING VET

Dr. Parchello

INVOICE

43517

DATE

6/28/23

INTERPRETATION OF THE FINDINGS & FURTHER RECOMMENDATIONS

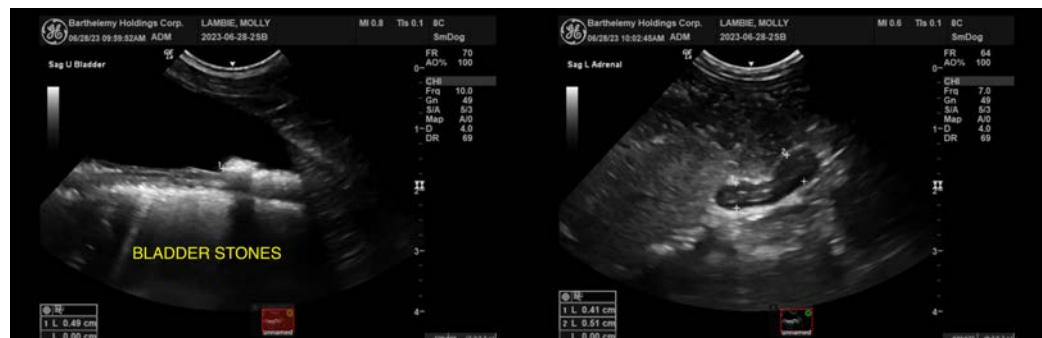
The liver is large and heterogeneous. This is a non-specific finding. No focal lesions are identified. There is a moderate to large amount of debris visualized in the gallbladder, but no significant evidence of surrounding inflammation. These are recommendations for further evaluation of a primary ALP elevation.

- Induction phenomena are the most common cause for an elevation in ALP. These are systemic illnesses that 'turn on' the liver enzyme. Causes of this include Cushing's disease, dental disease, arthritis, and numerous others. In many cases the exact cause is unclear but as long as ultrasound and bile acids tests are normal most patients do not have progressive changes in their liver. While liver biopsy is not routinely performed, vacuolar hepatopathy, is noted on most biopsies. This is often non-progressive but in rare cases can be more severe and lead to liver failure.
- If signs of cushings disease are present recommend endocrine function testing to evaluate for cushings disease.
- Consider fine needle aspirate to rule out round cell neoplasia -if this is a concern.
- If a cause for the ALP elevation is not identified: I recommend recheck general blood work every 6 months, ultrasound once per year, and bile acids test every 1-2 years based on other results. If the ALP continues to climb a biopsy could be considered.
- Consider long term use of denamarin, and monitoring for the signs of cushings developing.
- A primary vacuolar hepatopathy can be breed related and is seen in Scottish Terriers, Schnauzers, Cocker spaniels etc..

The elevation in triglycerides is likely breed related hyperlipidemia. Depending on the severity and the symptoms associated, medical management may be necessary.

The pancreas is prominent and mottled but does not appear overtly inflamed. These changes are consistent with mild chronic inflammation or previous episodes of inflammation. Correlate with a cPLI level and clinical signs.

Recommend abdominal radiographs to evaluate the bladder stones visualized, determine the number and size, and if they are small enough to pass on their own or voiding hydropropulsion. Additionally, recommend urinalysis and culture in case a dissolution diet could be helpful.





PATIENT

Molly Lambie

SPECIES

Canine

BREED

Mini Schnauzer

SEX

Spayed Female

AGE

5 Years

WEIGHT

8.4 kg

INTERPRETED BY

Kathleen Sennello DVM,
MS, Diplomate ACVIM
(Small Animal Internal
Medicine)

**IMAGING
PERFORMED BY**

Dr. Sarah Barthelemy

HOSPITAL NAME

Cranston Vet Hospital

REFERRING VET

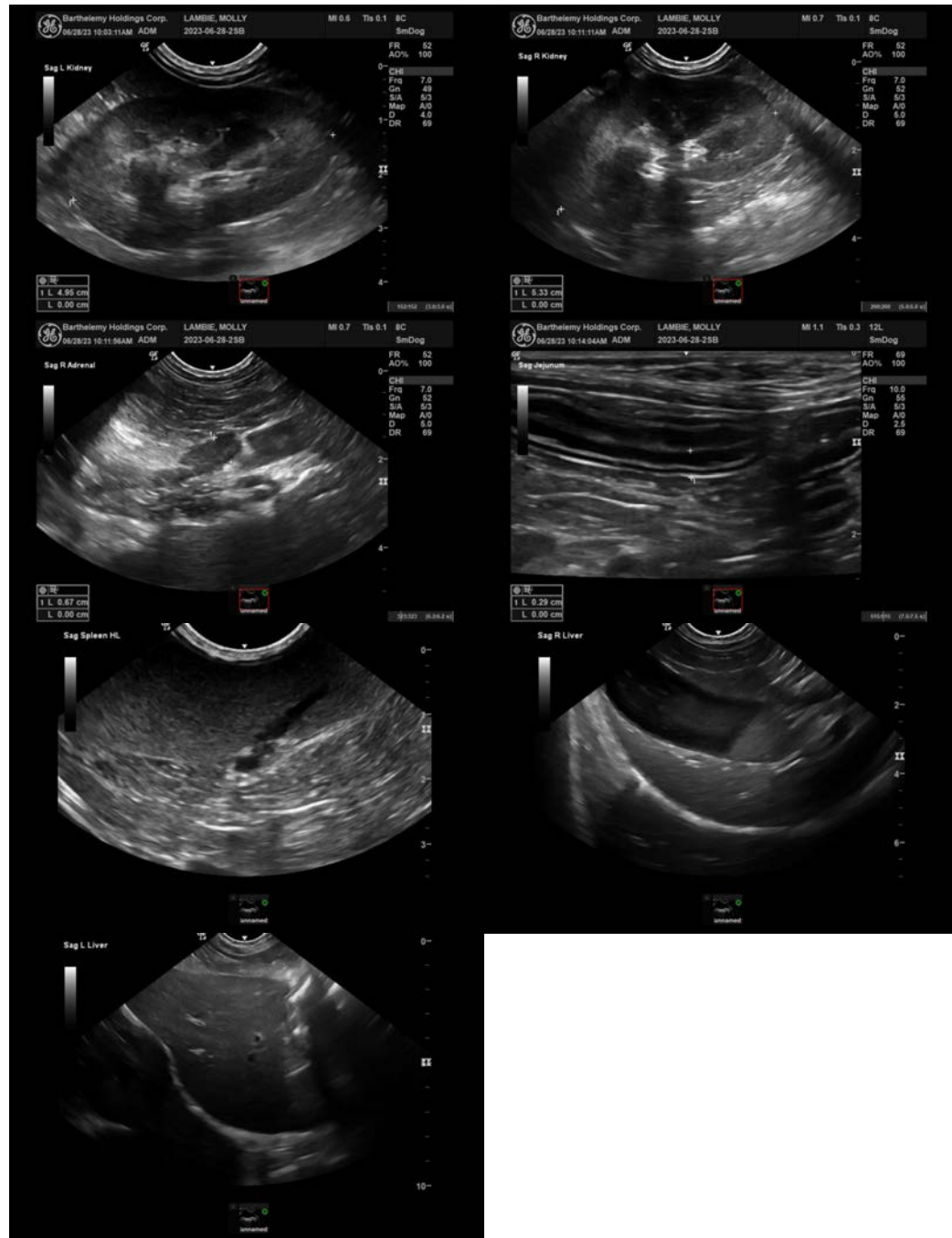
Dr. Parchello

INVOICE

43517

DATE

6/28/23



The information and recommendations provided are based on the images presented by the referring veterinarian/sonographer. No evaluation can be communicated regarding pathology that was not visible in the image/video clips provided.

Thank you for this referral. If the clinical or image interpretation does not parallel your findings or if I can be of any further assistance please contact me.

Kathleen Sennello DVM,MS, Diplomate ACVIM (Small animal Internal Medicine)

info@sonopath.com