

**DATE PRESENTING CLINICAL SIGNS**

6/28/23 Increased liver values. Suspicious spot on liver.

PATIENT

Leo Jenkins

Current Medications: Flagyl 250mg BID for 5 days and Provable probiotics SID- both started yesterday.
Lab Results: See attached.

Radiographs: See attached.

Date of Previous IntraPet Ultrasound: No previous.

Sedation: Dexdomitor.

SPECIES

Canine

Stat Report: Not requested.

Imaging Performed By: Stephanie Warga RDCS, RVT.

BREED

Labradoodle

ULTRASONOGRAPHIC EXAMINATION OF THE ABDOMEN**Urinary System**

The urinary bladder is moderately distended with anechoic urine. The Bladder wall, trigone, ureteral papillae and visible urethra (to a depth of 2cm) appear normal with no evidence of wall thickening, mucosal irregularities, masses or cystic calculi.

SEX

Neutered Male

The prostate is normal in size (0.76 cm) and shape for this neutered male dog. The parenchyma is homogenous and the external margins are smooth. The prostatic urethra appears normal with no evidence of irregularity, invasion, mass effect or calculi.

AGE

6/12/10

The left kidney has a normal shape and size (7.11 cm). Overall echogenicity is normal with adequate corticomedullary distinction and a typical 1:3 cortex:medulla ratio. There is no evidence of focal perinephric inflammation or effusion. There is no evidence of pyelectasia, nephroliths, infarcts or hydroureter. Renal vasculature is normal.

WEIGHT

63.2 Pounds

INTERPRETED BY

Kathleen Sennello DVM,
MS, Diplomate ACVIM
(Small Animal Internal
Medicine)

The right kidney has a normal shape and size (6.34 cm) with a cortical cyst measuring 1.15 cm. Overall echogenicity is normal with adequate corticomedullary distinction and a typical 1:3 cortex:medulla ratio. There is no evidence of focal perinephric inflammation or effusion. There is no evidence of pyelectasia, nephroliths, infarcts or hydroureter. Renal vasculature is normal.

HOSPITAL NAME

AMC of Dulaney Valley

Adrenal Glands

The left adrenal gland is normal in size measuring 0.89 cm at the caudal pole. It is observed in its normal position cranial to the left renal artery. It is normal in appearance (uniformly hypoechoic) and shape with no evidence of a mass effect.

REFERRING VET

Dr. Chrest

The right adrenal gland is normal in size measuring 0.69 cm at the caudal pole. It is observed in its normal position between the cranial aspect of the right kidney and the caudal vena cava. It is normal in appearance (uniformly hypoechoic) and shape with no evidence of a mass effect.

INVOICE

43523

Spleen

The spleen is subjectively normal in size, echotexture is homogenous, and the splenic capsule is smooth with no irregularities. The blood flow through the hilus and splenic parenchyma appears normal. No focal parenchymal abnormalities are visualized.

Liver

The liver is large in size, and normal in echogenicity with smooth peripheral margins. The parenchyma is heterogenous in echotexture with subtle, indistinct focal mottling. The visible portions of the vasculature and biliary tract appear normal. There are numerous small hyperechoic nodules visualized in the parenchyma. One such nodule measures at 1.37 cm. Additionally, there is a larger hyperechoic mixed echogenic mass effect visualized in the left side of the liver measuring 3.82 cm x 2.79 cm.

The gall bladder lumen is moderately distended. The wall of the gall bladder is not thickened and has a smooth mucosal surface. There is some hyperechoic sandy dependent debris visualized in the dependent portion of the gallbladder. The cystic and common bile ducts are normal/not visible.

Gastrointestinal

The stomach contains minimal luminal contents. It measures at a normal thickness of <0.7cm with some variability due to the presence of rugal folds. The distinction of the gastric wall layers is adequate and there is no impression of reduced peristaltic activity. No masses or focal lesions were observed.

The visualized areas of duodenum, jejunum and ileum have a relatively uniform diameter with minimal fluid distension. Wall thickness is normal. Bowel loops follow a curvilinear path with distinct wall layering maintaining the typical 1:3 muscularis:mucosa layer ratio. Jejunum wall measures 0.39 cm. Visualized peristalsis appears appropriate. There were no focal lesions consistent with obstruction or a mass effect observed.

The ileocecal junction was visualized and exhibited normal intact wall layering and is subjectively of normal thickness. Sections of colon are visualized with formed fecal material and gas shadowing distally. There is no observed focal or generalized colon wall thickening or loss of layering.

Pancreas

The pancreas is normal and isoechoic to surrounding mesentery. There is no evidence of nodules or cystic lesions. There is no evidence of regional mesenteric inflammation or fluid.

Free Abdomen

Evaluation of the peritoneal cavity did not reveal any evidence of effusion, or subjective lymphadenomegaly. The Medial iliac nodes appear normal and there was no evidence of a caudal aortic thrombus at the bifurcation. The omentum is of normal uniform echogenicity.

PRIMARY FINDINGS

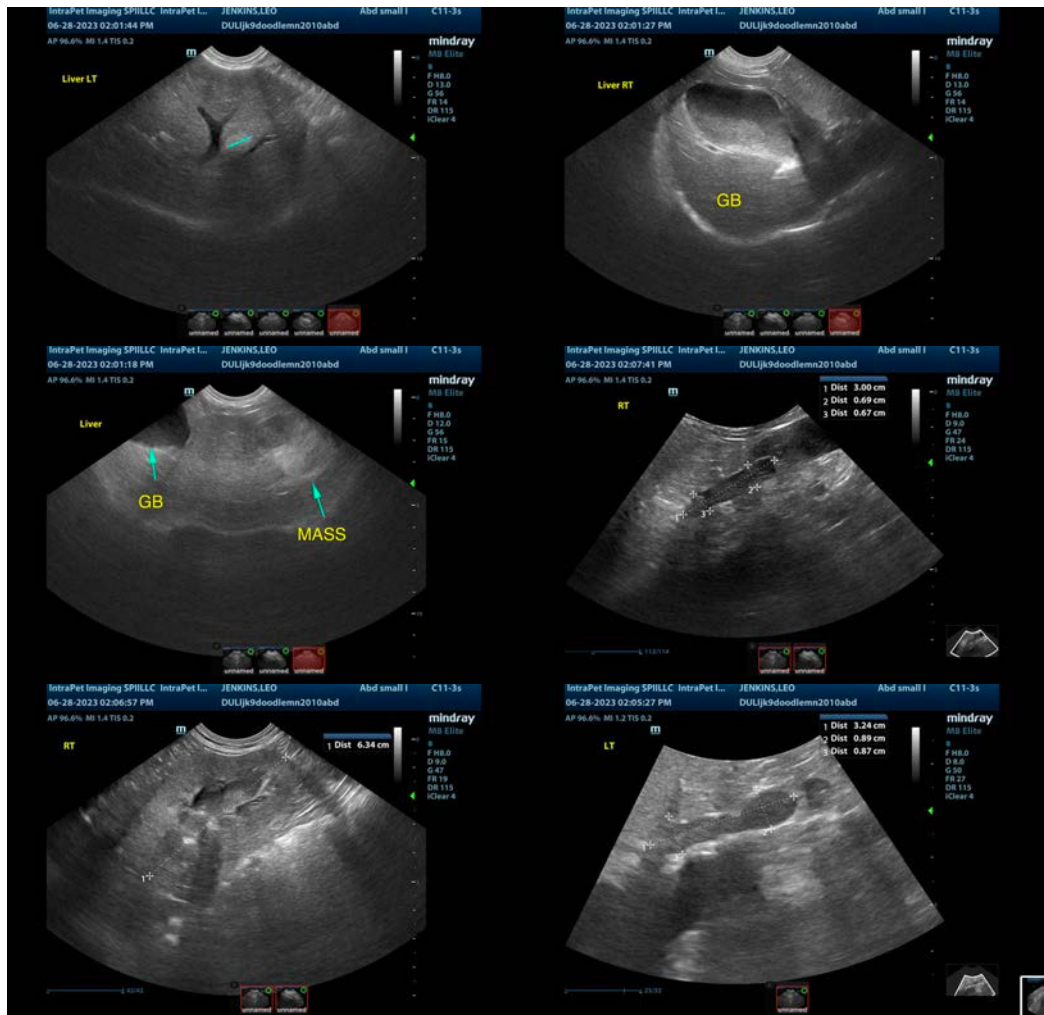
- Mildly heterogeneous liver with occasional small hyperechoic nodules and a mixed echogenic hyperechoic mass effect on the left side – The diffuse hepatic changes are non-specific and could be consistent with vacuolar hepatopathy, nodular hyperplasia, inflammatory/immune-mediated disease, fibrosis, extramedullary hematopoiesis, toxic hepatopathy (e.g., copper), infiltrative neoplasia (less likely) or other hepatopathy. The appearance of the hyperechoic nodules trends towards a more benign etiology. The larger mixed echogenic mass effect is most consistent with a primary hepatic mass lesion (adenoma, carcinoma, etc.), but other differentials are also possible.
- Moderate gallbladder debris with some dependent sandy/mineralized debris – The significance of the aggregated gallbladder debris is unclear. This could represent an early mucocele, cholestasis, or may be secondary to fasting but seems unlikely to be causing a current issue. Recommend continued monitoring.

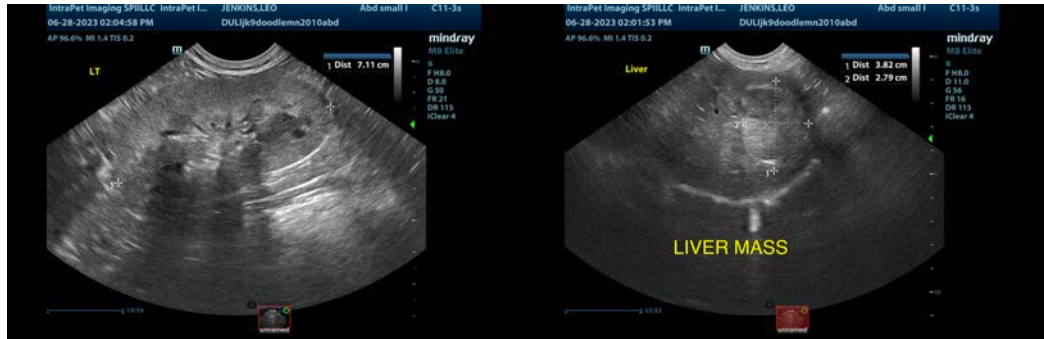
SECONDARY FINDINGS

- Cystic lesion visualized in the right kidney – Findings are most consistent with a benign renal cyst.

INTERPRETATION OF THE FINDINGS & FURTHER RECOMMENDATIONS

The liver is mildly heterogeneous with some ill-defined hyperechoic nodules. The appearance of these nodules trends towards a benign etiology, and the heterogeneous nature of the liver could be consistent with age related remodeling. There is a mixed echogenic mass effect visualized. This is concerning for a primary hepatic mass lesion (carcinoma, adenoma, other), but other lesions are also possible. Consider a contrast CT scan to better evaluate the location and nature of the lesion and look for any smaller nodule that may be concerning. Additionally, a fine needle aspirate of this lesion could be considered. If this is truly a primary hepatic mass lesion and surgical resection is successful, then the prognosis can be good, as these can often be slow-growing, slow to metastasize, etc.





The information and recommendations provided are based on the images presented by the referring veterinarian/sonographer. No evaluation can be communicated regarding pathology that was not visible in the image/video clips provided.

Thank you for this referral. If the clinical or image interpretation does not parallel your findings or if I can be of any further assistance please contact me.

Kathleen Sennello DVM,MS, Diplomate ACVIM (Small animal Internal Medicine)
info@sonopath.com