

**DATE PRESENTING CLINICAL SIGNS**

6/28/23

Recheck ultrasound following hospitalization for vomiting blood and hematochezia. Initial U/S with intrapet revealed enlarged mildly heterogenous prostate and moderate gall bladder debris
Was hospitalized at Pet ER, no underlying cause identified. Repeated rads and ultrasound, no new findings. Full ACTH stim performed was wnl. BP wnl

PATIENT

Duncan Lutz

SPECIES

Canine

BREED

Pit Bull X

SEX

Intact Male

AGE

9/7/16

WEIGHT

49.6 Pounds

INTERPRETED BY

Kathleen Sennello DVM,
MS, Diplomate ACVIM
(Small Animal Internal
Medicine)

HOSPITAL NAME

Paradise AH

REFERRING VET

Dr. Halpern

INVOICE

43524

Current Medications: Omeprazole, Sucralfate, Clavamox, Cerenia, Gabapentin
Lab Results: Coags wnl. Baseline cortisol 1.8. ACTH stim performed at ER—wnl No change to ALT post on hospitalization-- Started empirical antibiotic therapy for cholecystitis and gabapentin for pain
-- Also on sucralfate and omeprazole
Date of Previous IntraPet Ultrasound: 5/24/23. See attached.
Sedation: Dexdomitor/Torbugesic.
Stat Report: Not requested.
Imaging Performed By: Stephanie Warga RDCS, RVT.

ULTRASONOGRAPHIC EXAMINATION OF THE ABDOMEN**Urinary System**

The urinary bladder is moderately distended with anechoic urine. The Bladder wall, trigone, ureteral papillae and visible urethra (to a depth of 2cm) appear normal with no evidence of wall thickening, mucosal irregularities, masses or cystic calculi.

The prostate is large, hyperechoic and heterogeneous, measuring 3.83 cm in diameter. No discrete focal lesions are present. The prostatic urethra appears normal with no evidence of irregularity, invasion, mass effect or calculi.

The left kidney has a normal shape and size (6.29 cm). Overall echogenicity is normal with adequate corticomedullary distinction and a typical 1:3 cortex:medulla ratio. There is no evidence of focal perinephric inflammation or effusion. There is no evidence of pyelectasia, nephroliths, infarcts or hydroureter. Renal vasculature is normal.

The right kidney has a normal shape and size (6.0 cm). Overall echogenicity is normal with adequate corticomedullary distinction and a typical 1:3 cortex:medulla ratio. There is no evidence of focal perinephric inflammation or effusion. There is no evidence of pyelectasia, nephroliths, infarcts or hydroureter. Renal vasculature is normal.

Adrenal Glands

The left adrenal gland is normal in size measuring 0.57 cm at the caudal pole. It is observed in its normal position cranial to the left renal artery. It is normal in appearance (uniformly hypoechoic) and shape with no evidence of a mass effect.

The right adrenal gland is normal in size measuring 0.47 cm at the caudal pole. It is observed in its normal position between the cranial aspect of the right kidney and the caudal vena cava. It is normal in appearance (uniformly hypoechoic) and shape with no evidence of a mass effect.

Spleen

The spleen is subjectively normal in size, echotexture is homogenous, and the splenic capsule is smooth with no irregularities. The blood flow through the hilus and splenic parenchyma appears normal. No focal parenchymal abnormalities are visualized.

Liver

The liver is subjectively normal in size, and echogenicity with smooth peripheral margins. The parenchyma is heterogenous in echotexture with subtle, indistinct focal mottling. The visible portions of the vasculature and biliary tract appear normal. No focal nodules or cystic lesions are observed.

The gallbladder lumen is moderately distended. The wall of the gall bladder is not thickened and has a smooth mucosal surface. Luminal contents are mild and primarily anechoic. There is a focal area of rounded hyperechoic material/tissue visualized in the gallbladder. This appears non-mobile and appears vascular on color flow. This measures at 1.92 cm x 1.0 cm. This area of tissue/material appears stable from the previous exam. There is no evidence of wall thickening and no fluid surrounding the gallbladder on today's exam. The cystic and common bile ducts are normal/not visible.

Gastrointestinal

The stomach contains minimal luminal contents. It measures at a normal thickness of <0.7cm with some variability due to the presence of rugal folds. The distinction of the gastric wall layers is adequate and there is no impression of reduced peristaltic activity. No masses or focal lesions were observed.

The visualized areas of duodenum, jejunum and ileum have a relatively uniform diameter with minimal fluid distension. Wall thickness is normal. Bowel loops follow a curvilinear path with distinct wall layering maintaining the typical 1:3 muscularis:mucosa layer ratio. Duodenum wall measures 0.45 cm. Jejunum wall measures 0.37 cm. Visualized peristalsis appears appropriate. There were no focal lesions consistent with obstruction or a mass effect observed.

The ileocecal junction was visualized and exhibited normal intact wall layering and is subjectively of normal thickness. Sections of colon are visualized with formed fecal material and gas shadowing distally. There is no observed focal or generalized colon wall thickening or loss of layering.

Pancreas

The pancreas is normal and isoechoic to surrounding mesentery. There is no evidence of nodules or cystic lesions. There is no evidence of regional mesenteric inflammation or fluid.

Free Abdomen

Evaluation of the peritoneal cavity did not reveal any evidence of effusion, or subjective lymphadenomegaly. The Medial iliac nodes appear normal and there was no evidence of a caudal aortic thrombus at the bifurcation. The omentum is of normal uniform echogenicity.

Other

Both testicles are visualized and appear within normal limits.

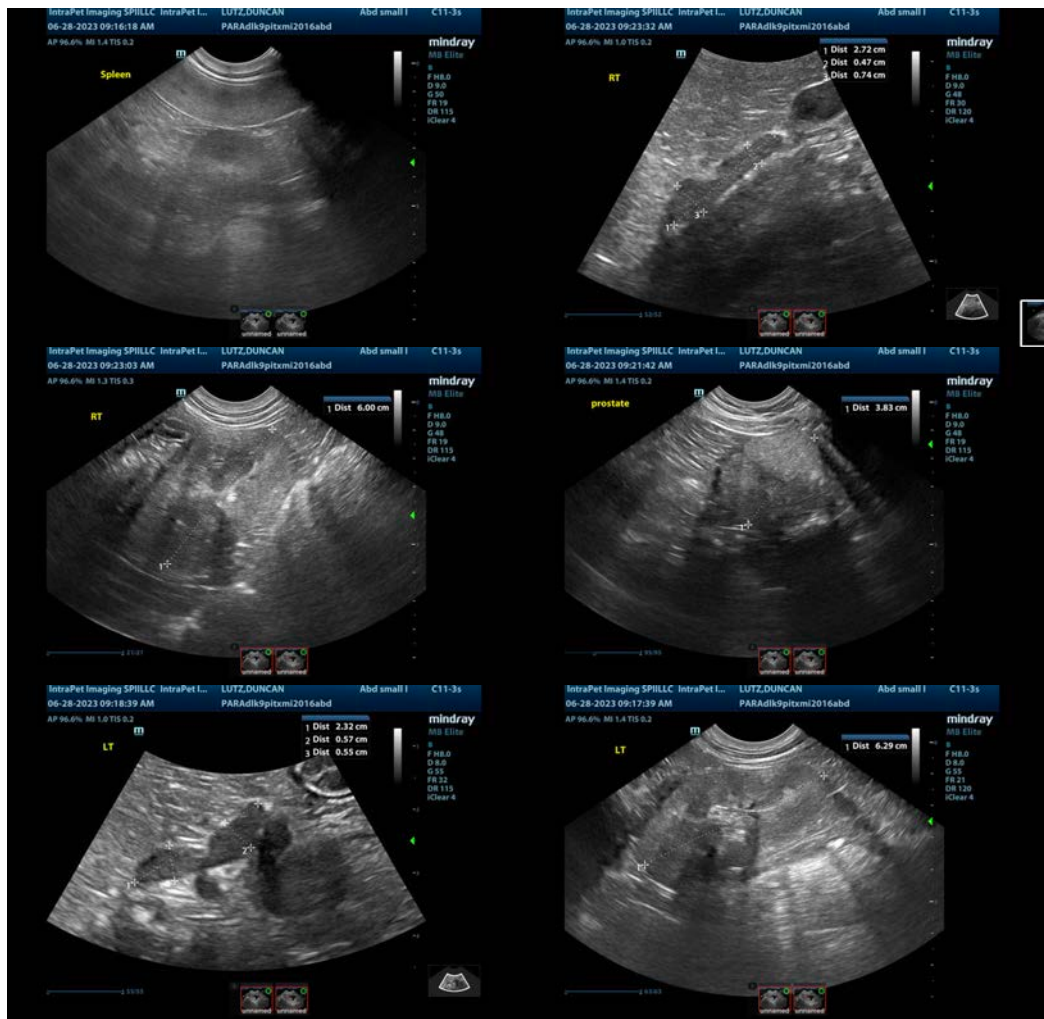
ULTRASONOGRAPHIC FINDINGS

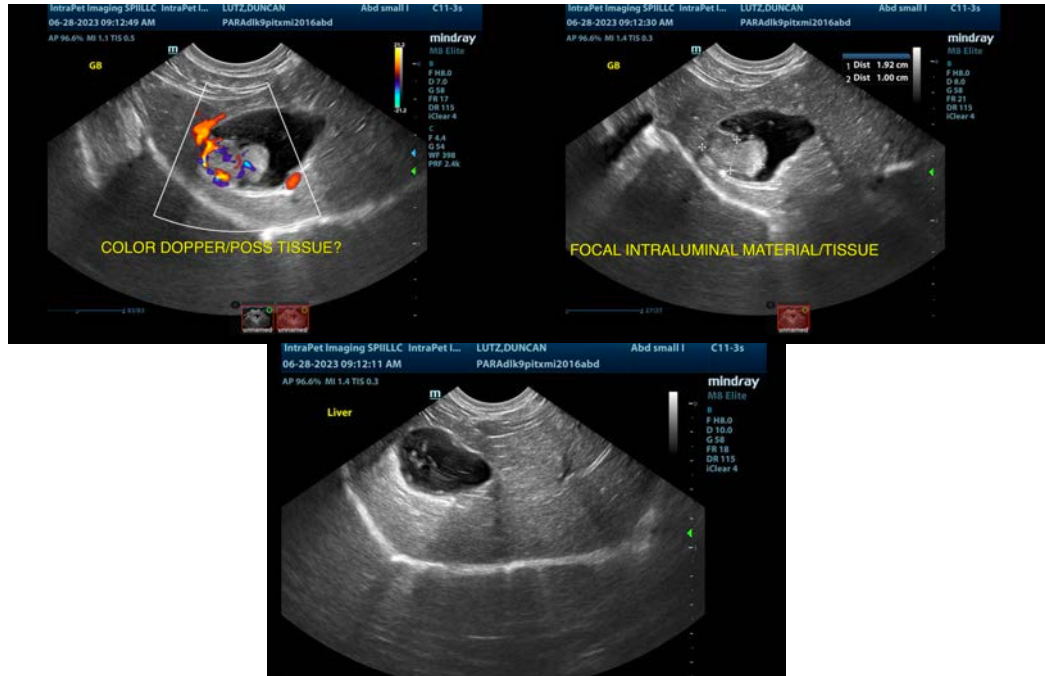
- Large, hyperechoic, heterogeneous prostate – Prostatic changes are most consistent with benign prostatic hyperplasia. Other differentials include bacterial prostatitis and prostatic neoplasia. However, given the lack of lower urinary tract symptoms, these differentials are considered less likely in this patient.
- Focal area of hyperechoic debris/tissue in the gallbladder lumen – This is suspicious for a possible mass effect/tissue. Inflamed debris is possible.

INTERPRETATION OF THE FINDINGS & FURTHER RECOMMENDATIONS

Overall, the gallbladder looks improved from the previous exam (5/2023), as there is no surrounding fluid, inflammation, etc. There is a persistent focal area of hyperechoic tissue/material that shows evidence of vascularization based on color flow and is highly suspicious for a possible mass effect. Options moving forward would include a contrast CT scan to determine if it enhances, etc. and to look for additional lesions, or you could consider continued monitoring with ultrasound to look for progression/growth, etc. (recheck in 8-12 weeks).

The prostate is large and hyperechoic, most consistent with benign prostatic hypertrophy +/- prostatitis. It appears stable compared to the previous exam.





The information and recommendations provided are based on the images presented by the referring veterinarian/sonographer. No evaluation can be communicated regarding pathology that was not visible in the image/video clips provided.

Thank you for this referral. If the clinical or image interpretation does not parallel your findings or if I can be of any further assistance please contact me.

Kathleen Sennello DVM,MS, Diplomate ACVIM (Small animal Internal Medicine)
info@sonopath.com