

**DATE PRESENTING CLINICAL SIGNS**

6/28/23 Atticus has a history of pu/pd and accidents in the house starting in May. Bloodwork showed isosthenuria and borderline proteinuria with a quiet sediment, as well as liver enzyme elevations. A LDDS was inconclusive.

**PATIENT**

Atticus Bennett

**SPECIES**

Canine

**BREED**

Mixed

**SEX**

Neutered Male

**AGE**

3/26/13

**WEIGHT**

64.1 Pounds

**INTERPRETED BY**

Kathleen Sennello DVM,  
MS, Diplomate ACVIM  
(Small Animal Internal  
Medicine)

**HOSPITAL NAME**

Frederick Road VH

**REFERRING VET**

Dr. Flynn

**INVOICE**

43529

Lab Results: Glucose 86 (63 - 114 mg/dL), ALT 240 (18 - 121 U/L), AST 50 (16 - 55 U/L), ALP 433 (5 - 160 U/L), Cholesterol 749 (131 - 345 mg/dL), Lipase 287(0 - 250 U/L), Urine Protein: Creatinine Ratio 0.4 Specific Gravity 1.011, Cortisol - Baseline 1.8 (1.0 - 6.0 µg/dL), Cortisol - 4 hr Post Dex 1.3, Cortisol - 8 hr Post Dex 0.5  
Date of Previous IntraPet Ultrasound: No previous.  
Sedation: Torbugesic.  
Stat Report: Not requested.  
Imaging Performed By: Stephanie Warga RDCS, RVT.

**ULTRASONOGRAPHIC EXAMINATION OF THE ABDOMEN****Urinary System**

The urinary bladder is moderately distended with anechoic urine. The Bladder wall, trigone, ureteral papillae and visible urethra (to a depth of 2cm) appear normal with no evidence of wall thickening, mucosal irregularities, masses or cystic calculi.

The prostate is normal in size (0.90 cm) and shape for this neutered male dog. The parenchyma is homogenous and the external margins are smooth. The prostatic urethra appears normal with no evidence of irregularity, invasion, mass effect or calculi.

The left kidney has a normal shape and size (7.7 cm). Overall echogenicity is normal with adequate corticomedullary distinction and a typical 1:3 cortex:medulla ratio. There is no evidence of focal perinephric inflammation or effusion. There is no evidence of pyelectasia, nephroliths, infarcts or hydroureter. Renal vasculature is normal.

The right kidney has a normal shape and size (7.1 cm). Overall echogenicity is normal with adequate corticomedullary distinction and a typical 1:3 cortex:medulla ratio. There is no evidence of focal perinephric inflammation or effusion. There is no evidence of pyelectasia, nephroliths, infarcts or hydroureter. Renal vasculature is normal.

**Adrenal Glands**

The left adrenal gland is normal in size measuring 0.90 cm at the caudal pole. It is observed in its normal position cranial to the left renal artery. It is normal in appearance (uniformly hypoechoic) and shape with no evidence of a mass effect.

The right adrenal gland is normal in size measuring 0.91 cm at the caudal pole. It is observed in its normal position between the cranial aspect of the right kidney and the caudal vena cava. It is normal in appearance (uniformly hypoechoic) and shape with no evidence of a mass effect.

**Spleen**

The spleen is subjectively normal in size, echotexture is homogenous, and the splenic capsule is smooth with no irregularities. The blood flow through the hilus and splenic parenchyma appears normal. No focal parenchymal abnormalities are visualized.

### ***Liver***

The liver is normal/borderline small in size, and is normal in echogenicity with smooth peripheral margins. The parenchyma is homogenous echotexture. The visible portions of the vasculature and biliary tract appear normal. No focal nodules or cystic lesions are observed.

The gallbladder lumen is moderately distended. The wall of the gall bladder is not thickened and has a smooth mucosal surface. Luminal contents are mild and primarily anechoic. The cystic and common bile ducts are normal/not visible.

### ***Gastrointestinal***

The stomach contains moderate gas and fluid. It measures at a normal thickness of <0.7cm with some variability due to the presence of rugal folds. The distinction of the gastric wall layers is adequate and there is no impression of reduced peristaltic activity. No masses or focal lesions were observed. Full evaluation of the stomach is not possible due to shadowing fluid and gas.

The visualized areas of duodenum, jejunum and ileum have a relatively uniform diameter with minimal fluid distension. Wall thickness is normal. Bowel loops follow a curvilinear path with distinct wall layering maintaining the typical 1:3 muscularis:mucosa layer ratio. Duodenum wall measures 0.54 cm. Jejunum wall measures 0.40 cm. Visualized peristalsis appears appropriate. There were no focal lesions consistent with obstruction or a mass effect observed.

The ileocecal junction was visualized and exhibited normal intact wall layering and is subjectively of normal thickness. Sections of colon are visualized with formed fecal material and gas shadowing distally. There is no observed focal or generalized colon wall thickening or loss of layering.

### ***Pancreas***

The pancreas is normal and isoechoic to surrounding mesentery. There is no evidence of nodules or cystic lesions. There is no evidence of regional mesenteric inflammation or fluid.

### ***Free Abdomen***

Evaluation of the peritoneal cavity did not reveal any evidence of effusion, or subjective lymphadenomegaly. The Medial iliac nodes appear normal and there was no evidence of a caudal aortic thrombus at the bifurcation. The omentum is of normal uniform echogenicity.

## **ULTRASONOGRAPHIC FINDINGS**

- Borderline small liver – No abnormalities were noted associated with the liver, but it was viewed primarily intracostally. The significance of this is uncertain.
- Moderate fluid/gas in the gastric lumen – Correlate with feeding history. The fluid and gas present limits full evaluation of the stomach. No abnormalities noted.

## **INTERPRETATION OF THE FINDINGS & FURTHER RECOMMENDATIONS**

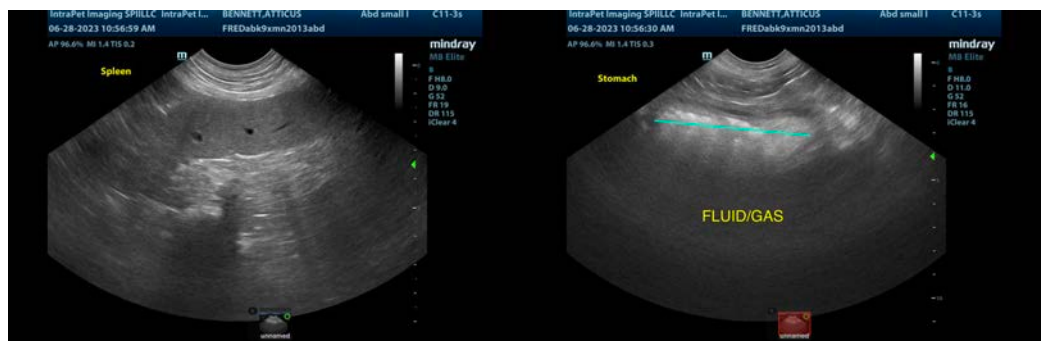
No focal lesions were visualized associated with the liver. It subjectively appears somewhat small. Correlate with abdominal radiographs, which better evaluate hepatic size. These are my recommendations for evaluation of PU/PD with limited focal lesions.

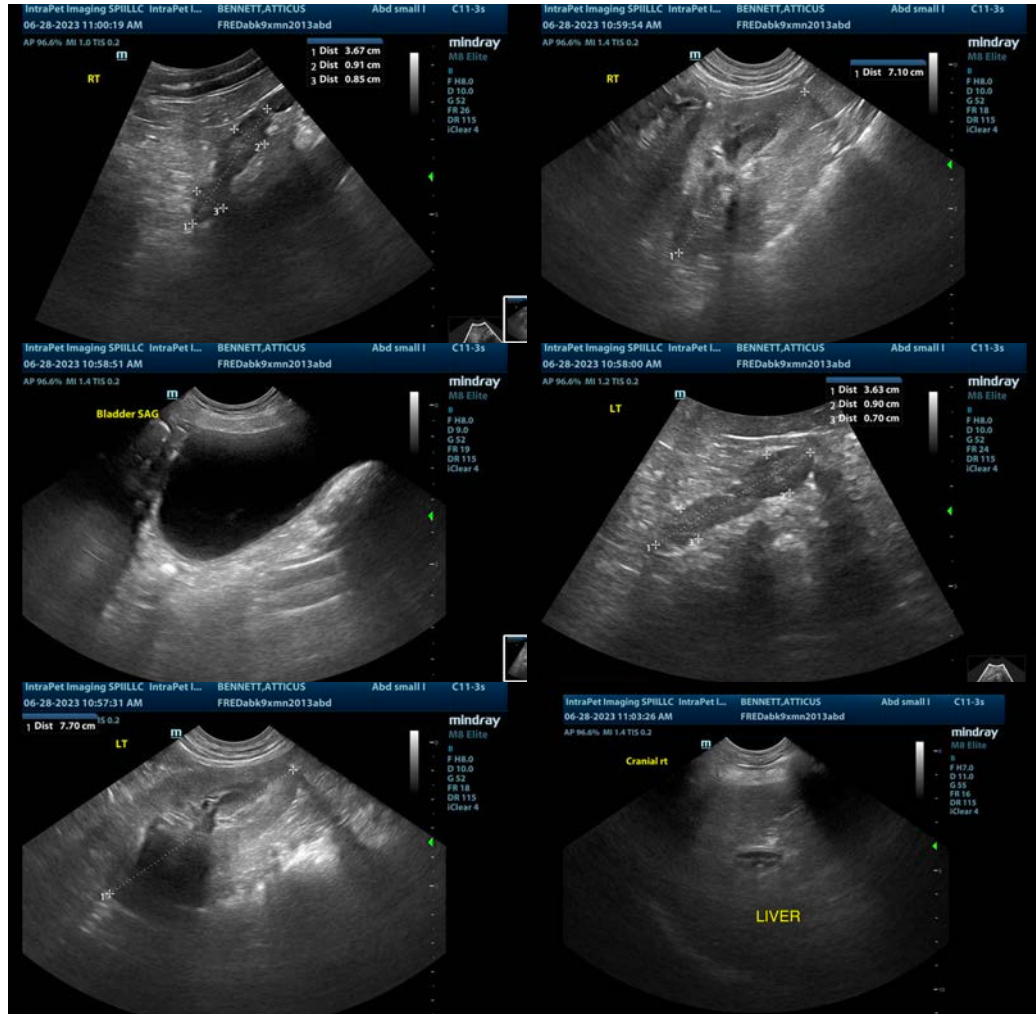
An obvious lesion responsible for the reported increase in thirst and urination was not visualized. Some issues such as early renal disease, Cushing's disease, behavioral, neurologic, dietary, electrolyte disturbances etc.. are not able to be diagnosed with ultrasound alone. These can be challenging cases. The top 10 differentials can be ruled in/out with routine bloodwork, urinalysis and culture, several more can be

evaluated with a good history and imaging. Unfortunately, as you work your way down the list the differentials become harder to definitively diagnose. This is the differential list I start with.

1. Diabetes Mellitus
2. Chronic Renal Disease/Renal Failure (can present pre-azotemic, especially in dogs, but expect the BUN & creatinine not to be at the low end of the reference range)
3. Hypercalcemia
4. Urinary tract infection
5. Iatrogenic Disease due to medications (diuretics, phenobarbital, KBr; diets either high in salt [such as S/D] or very low in protein (such as U/D))
6. Hyperthyroidism
7. Hypokalemia
8. Liver Disease (hepatic encephalopathy may be a mixed primary PU and PD)
9. Pyelonephritis
10. Polycythemia
11. Renal Tubular Diseases (glycosuria or Fanconi & Fanconi-like syndromes or RTA)
12. Hyperadrenocorticism (may be a mixed primary PU and PD)
13. Hypoadrenocorticism (either Addison's or hypocortisolism)
14. Paraneoplastic Syndromes (particularly splenic hemangiosarcoma?)
15. Pericardial Effusion
16. Pyometra (including stump pyometra in spayed dogs)
17. Chronic Partial Urinary Obstruction or Post-Obstructive Diuresis
18. Pheochromocytoma
19. Psychogenic Polydipsia (as in a true behavior disorder with a compulsive element)
20. Primary Non-Medical Polydipsia (aka "I drink a lot because I like it or I engage in activities that promote it, but that doesn't mean I'm sick")
21. Primary Nephrogenic Diabetes Insipidus (Congenital Nephrogenic Diabetes Insipidus, other diseases that cause primary PU other than Congenital Diabetes Insipidus would be considered Acquired Nephrogenic Diabetes Insipidus)
22. Atypical Cushing's and SARDS
23. Central Diabetes Insipidus

Given the liver enzyme elevations, I would likely start with a liver function test and screening for Leptospirosis. A fine needle aspirate of the liver could be considered.





The information and recommendations provided are based on the images presented by the referring veterinarian/sonographer. No evaluation can be communicated regarding pathology that was not visible in the image/video clips provided.

Thank you for this referral. If the clinical or image interpretation does not parallel your findings or if I can be of any further assistance please contact me.

Kathleen Sennello DVM,MS, Diplomate ACVIM (Small animal Internal Medicine)  
 info@sonopath.com