

IMAGING PERFORMED BY

IntraPet.com



SonoPath

Clinical Sonography & Telecytology

EDUCATIONAL TELECONSULTATION SERVICES™

1-800-838-4268 info@sonopath.com SonoPath.com

DATE PRESENTING CLINICAL SIGNS

6/28/22

Lizzie presented on 6/27 for vomiting, lethargy, not eating/drinking. On exam anisocoria in Right eye, pyrexia, bloodwork revealed elevated kidney parameters and increased white blood cells, urinalysis revealed urinary tract infection, radiographs revealed enlarged right kidney with possible nephrolith in left kidney

PATIENT

Lizzie Berry

Current Medications: Convenia- 0.4 mL given 6/27 2 weeks duration, Cerenia given 6/27 at 10:30 24 hour duration.

SPECIES

Feline

Lab Results: elevated WBC, renal parameters on bloodwork
Radiographs: renomegaly in right kidney and possible nephrolith in left kidney.
Date of Previous IntraPet Ultrasound: No previous.
Sedation: Not required to complete full diagnostic ultrasound.
Stat Report: Not requested.

BREED

DSH

ULTRASONOGRAPHIC EXAMINATION OF THE ABDOMEN

SEX

Spayed Female

Urinary System

The urinary bladder is moderately distended with anechoic urine. The Bladder wall, trigone, ureteral papillae and visible urethra (to a depth of 2cm) appear normal with no evidence of wall thickening, mucosal irregularities, masses or cystic calculi.

AGE

5/15/13

The left kidney has a normal shape and size (4.59 cm) with a non-obstructive nephrolith measuring 0.43 cm and pyelectasia at 0.32 cm. Overall echogenicity is slightly hyperechoic with poor corticomedullary distinction and a typical 1:3 cortex:medulla ratio. There is no evidence of perinephric inflammation or effusion. There is no evidence of infarcts or hydronephrosis. Renal vasculature is normal.

WEIGHT

9.3 Pounds

The right kidney is hydronephrotic with very little visible parenchyma. This structure measures at 6.55 cm. No stones are visualized, and a dilated ureter is not clearly visualized.

INTERPRETED BY

Kathleen Sennello DVM,
MS, Diplomate ACVIM
(Small Animal Internal
Medicine)

Adrenal Glands

The left adrenal gland is normal/borderline large in size measuring 0.56 cm at the caudal pole. It is observed in its normal position cranial to the left renal artery. It is normal in appearance (uniformly hypoechoic) and shape with no evidence of a mass effect.

IMAGING PERFORMED BY

Rachel Brillhart RDMS

The right adrenal gland is normal/borderline in size measuring 0.52 cm at the caudal pole. It is observed in its normal position between the cranial aspect of the right kidney and the caudal vena cava. It is normal in appearance (uniformly hypoechoic) and shape with no evidence of a mass effect.

HOSPITAL NAME

Homeward Bound VS

Spleen

The spleen is subjectively normal in size, echotexture is homogenous, and the splenic capsule is smooth with no irregularities. The blood flow through the hilus and splenic parenchyma appears normal. No focal parenchymal abnormalities are visualized.

REFERRING VET

Dr. Williams

Liver

The liver is subjectively normal in size, and echogenicity with smooth peripheral margins. The parenchyma is homogenous echotexture. The visible portions of the vasculature and biliary tract appear normal. No focal nodules or cystic lesions are observed.

INVOICE

39070

The gallbladder lumen is moderately distended. The wall of the gall bladder is not thickened and has a smooth mucosal surface. Luminal contents are primarily anechoic. The cystic and common bile ducts are normal/not visible.

Gastrointestinal

The stomach contains minimal luminal contents. It measures at a normal thickness of <0.36cm with some variability due to the presence of rugal folds. The distinction of the gastric wall layers is adequate and there is no impression of reduced peristaltic activity. No masses or focal lesions were observed.

The visualized areas of duodenum, jejunum and ileum have a relatively uniform diameter with minimal fluid distension. Wall thickness is normal. Bowel loops follow a curvilinear path with distinct wall layering maintaining the typical 1:3 muscularis:mucosa layer ratio. Jejunum wall measured 0.27 cm. Visualized peristalsis appears appropriate. There were no focal lesions consistent with obstruction or a mass effect observed.

The ileocecal junction was visualized and exhibited normal intact wall layering and is subjectively of normal thickness. Sections of colon are visualized with formed fecal material and gas shadowing distally. There is no observed focal or generalized colon wall thickening or loss of layering.

Pancreas

The pancreas is normal and isoechoic to surrounding mesentery. There is no evidence of nodules or cystic lesions. There is no evidence of regional mesenteric inflammation or fluid.

Free Abdomen

Evaluation of the peritoneal cavity did not reveal any evidence of effusion, or subjective lymphadenomegaly. The Medial iliac nodes appear normal and there was no evidence of a caudal aortic thrombus at the bifurcation. The omentum is of normal uniform echogenicity.

PRIMARY FINDINGS

- Large, hydronephrotic right kidney - No obvious focal obstruction is visualized. Suspect a stricture at the proximal ureter(?).
- Decreased corticomedullary distinction of the left kidney with a small, non-obstructive nephrolith and mild pyelectasia - Mild loss of corticomedullary distinction in both kidneys could be consistent with chronic degenerative disease or interstitial nephrosis. Pyelectasia of the left kidney could be consistent with pyelonephritis, chronic renal disease, secondary to PU/PD or fluid therapy (if applicable), other.

SECONDARY FINDINGS

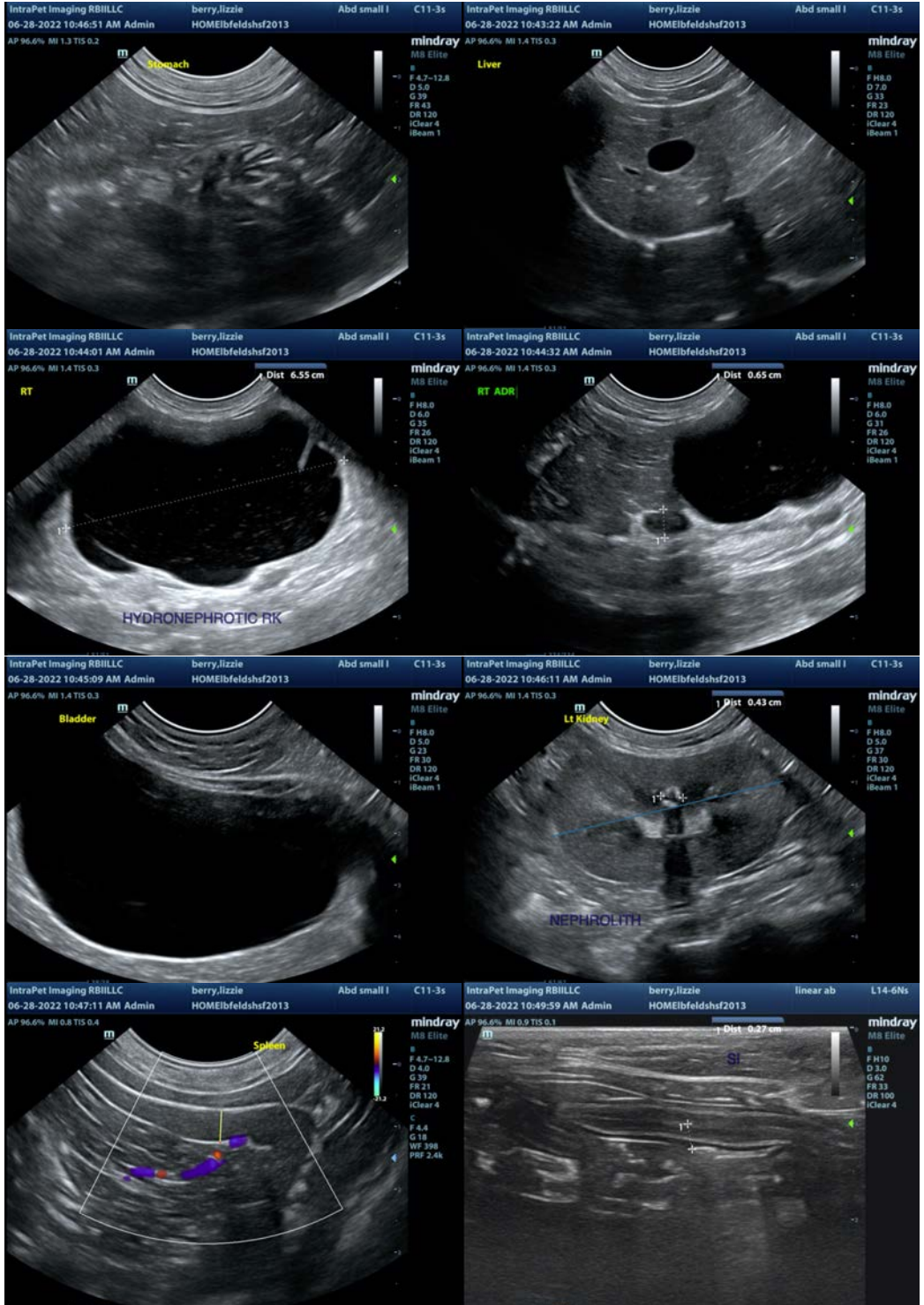
- Borderline bilateral adrenomegaly - likely a stress response due to chronic illness.

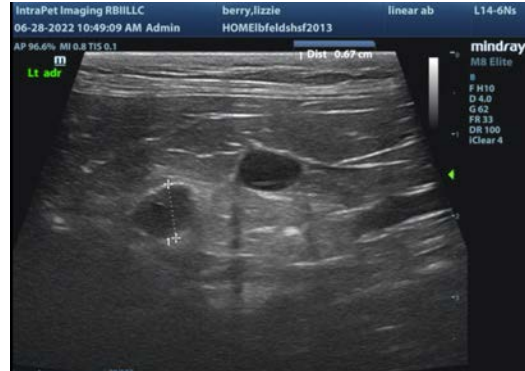INTERPRETATION OF THE FINDINGS & FURTHER RECOMMENDATIONS

The right kidney is completely hydronephrotic with little to no viable parenchyma visualized. The cause of this is not seen, but I suspect there could be a stricture at the level of the proximal ureter, possibly due to previous stone passing(?). Correlate with abdominal radiographs, looking for any evidence of mineralization along the path of the right ureter.

The left kidney has decreased corticomedullary distinction and mild pyelectasia. This could be due to pyelonephritis or just secondary to PU/PD due to underlying renal disease. Recommend a blood pressure evaluation and urine protein to creatinine ratio if the urine culture is negative.

Recommend continued monitoring of the right kidney. If it is continuing to enlarge, or is a source of discomfort, it could be surgically removed. Otherwise, continued monitoring for any signs of infection, pain, etc. are warranted.





The information and recommendations provided are based on the images presented by the referring veterinarian/sonographer. No evaluation can be communicated regarding pathology that was not visible in the image/video clips provided.

Thank you for this referral. If the clinical or image interpretation does not parallel your findings or if I can be of any further assistance please contact me.

Kathleen Sennello DVM,MS, Diplomate ACVIM (Small animal Internal Medicine)
kathleen.sennello@sonopath.com