



PATIENT

Tucker Malley

SPECIES

Canine

BREED

Mixed

SEX

Neutered Male

AGE

14 Years 8 Months

WEIGHT

46.8 Pounds

INTERPRETED BY

Kathleen Sennello DVM,
MS, Diplomate ACVIM
(Small Animal Internal
Medicine)

**IMAGING
PERFORMED BY**

Val Shumskaya

HOSPITAL NAME

Ho-Ho-Kus VH

REFERRING VET

Dr. Gannon

INVOICE

43482

DATE

6/27/23

PRESENTING CLINICAL SIGNS

Decreased app x 2 weeks, no v/d, exam nsf Current meds: Aspirin 81mg (2 tabs BID)
Abnormal PE/Chem/CBC/UA Results: wnl

ULTRASONOGRAPHIC EXAMINATION OF THE ABDOMEN

Urinary System

The urinary bladder is moderately distended with anechoic urine. The Bladder wall, trigone, ureteral papillae and visible urethra (to a depth of 2cm) appear normal with no evidence of wall thickening, mucosal irregularities, masses or cystic calculi.

The visualized areas of prostate and surrounding tissue appear normal. Unfortunately, the prostate is not fully visualized likely due to its intrapelvic location. Correlate with rectal exam findings.

The left kidney has a normal shape and size (5.7 cm). Overall echogenicity is normal with adequate corticomedullary distinction and a typical 1:3 cortex:medulla ratio. There is no evidence of focal perinephric inflammation or effusion. There is no evidence of pyelectasia, nephroliths, infarcts or hydroureter. Renal vasculature is normal.

The right kidney has a normal shape and size (5.59 cm). Overall echogenicity is normal with adequate corticomedullary distinction and a typical 1:3 cortex:medulla ratio. There is no evidence of focal perinephric inflammation or effusion. There is no evidence of pyelectasia, nephroliths, infarcts or hydroureter. Renal vasculature is normal.

Adrenal Glands

The left adrenal gland is normal in size measuring 0.50 cm at the caudal pole. It is observed in its normal position cranial to the left renal artery. It is normal in appearance (uniformly hypoechoic) and shape with no evidence of a mass effect.

The right adrenal gland is normal in size measuring 0.68 cm at the caudal pole. It is observed in its normal position between the cranial aspect of the right kidney and the caudal vena cava. It is normal in appearance (uniformly hypoechoic) and shape with no evidence of a mass effect.

Spleen

The spleen is subjectively normal in size, echotexture is homogenous, and the splenic capsule is smooth with no irregularities. The blood flow through the hilus and splenic parenchyma appears normal. No focal parenchymal abnormalities are visualized.

Liver

The liver is subjectively normal in size, and echogenicity with smooth peripheral margins. The parenchyma is heterogenous in echotexture with subtle, indistinct focal mottling. The visible portions of the vasculature and biliary tract appear normal. No focal nodules or cystic lesions are observed.

The gall bladder lumen is moderately distended. The wall of the gall bladder is not thickened and has a smooth mucosal surface. There is a moderate amount of non-organized echogenic debris. The cystic and common bile ducts are normal/not visible.



PATIENT

Gastrointestinal

Tucker Malley

The stomach contains minimal luminal contents. The stomach wall appears slightly irregular and thickened at 0.68 cm. The distinction of the gastric wall layers is adequate and there is no impression of reduced peristaltic activity. No masses or focal lesions were observed.

SPECIES

Canine

The visualized areas of duodenum, jejunum and ileum have a relatively uniform diameter with minimal fluid distension. Wall thickness is normal. Bowel loops follow a curvilinear path with distinct wall layering maintaining the typical 1:3 muscularis:mucosa layer ratio. Duodenum wall measures 0.35 cm. Jejunum wall measures 0.29 cm. Visualized peristalsis appears appropriate. There were no focal lesions consistent with obstruction or a mass effect observed.

BREED

Mixed

SEX

Neutered Male

The ileocecal junction was visualized and exhibited normal intact wall layering and is subjectively of normal thickness. Sections of colon are visualized with formed fecal material and gas shadowing distally. There is no observed focal or generalized colon wall thickening or loss of layering.

AGE

14 Years 8 Months

Pancreas

The pancreas is normal and isoechoic to surrounding mesentery. There is no evidence of nodules or cystic lesions. There is no evidence of regional mesenteric inflammation or fluid.

WEIGHT

46.8 Pounds

Free Abdomen

Evaluation of the peritoneal cavity did not reveal any evidence of effusion, or subjective lymphadenomegaly. The Medial iliac nodes appear normal and there was no evidence of a caudal aortic thrombus at the bifurcation. The omentum is of normal uniform echogenicity.

INTERPRETED BY

Kathleen Sennello DVM,
MS, Diplomate ACVIM
(Small Animal Internal
Medicine)

ULTRASONOGRAPHIC FINDINGS

- Heterogeneous liver – The diffuse hepatic changes are non-specific and could be consistent with vacuolar hepatopathy, nodular hyperplasia, inflammatory/immune-mediated disease, fibrosis, extramedullary hematopoiesis, toxic hepatopathy (e.g., copper), infiltrative neoplasia (less likely) or other hepatopathy.
- Moderate gallbladder debris – The significance of the aggregated gallbladder debris is unclear. This could represent an early mucocele, cholestasis, or may be secondary to fasting but seems unlikely to be causing a current issue. Recommend continued monitoring.
- Subjectively thickened gastric wall – The stomach wall thickening could be consistent with inflammation, edema, infiltrative neoplasia, imaging artifact due to rugal folds, other.

IMAGING PERFORMED BY

Val Shumskaya

HOSPITAL NAME

Ho-Ho-Kus VH

REFERRING VET

Dr. Gannon

INTERPRETATION OF THE FINDINGS & FURTHER RECOMMENDATIONS

No obvious focal lesions are visualized to explain the decrease in appetite reported. Subjectively the gastric wall appears slightly irregular and thickened in some regions. This can be highly variable due to rugal folding and the plane of imaging. Although the current dose of aspirin administered is relatively mild, this can be fully ulcerogenic in some individuals. You could consider discontinuing this medication and anti-ulcer therapy for a period of time to see if symptoms improve. If they do improve, an alternative NSAID could be considered. Alternately, an upper GI endoscopy could be performed to further evaluate the stomach. Unfortunately, there are many causes for inappetence that cannot be diagnosed by ultrasound alone.

INVOICE

43482

DATE

6/27/23

The changes visualized associated with the liver and gallbladder are of questionable significant if liver values are normal.



PATIENT

Tucker Malley

SPECIES

Canine

BREED

Mixed

SEX

Neutered Male

AGE

14 Years 8 Months

WEIGHT

46.8 Pounds

INTERPRETED BY

Kathleen Sennello DVM,
MS, Diplomate ACVIM
(Small Animal Internal
Medicine)

IMAGING PERFORMED BY

Val Shumskaya

HOSPITAL NAME

Ho-Ho-Kus VH

REFERRING VET

Dr. Gannon

INVOICE

43482

DATE

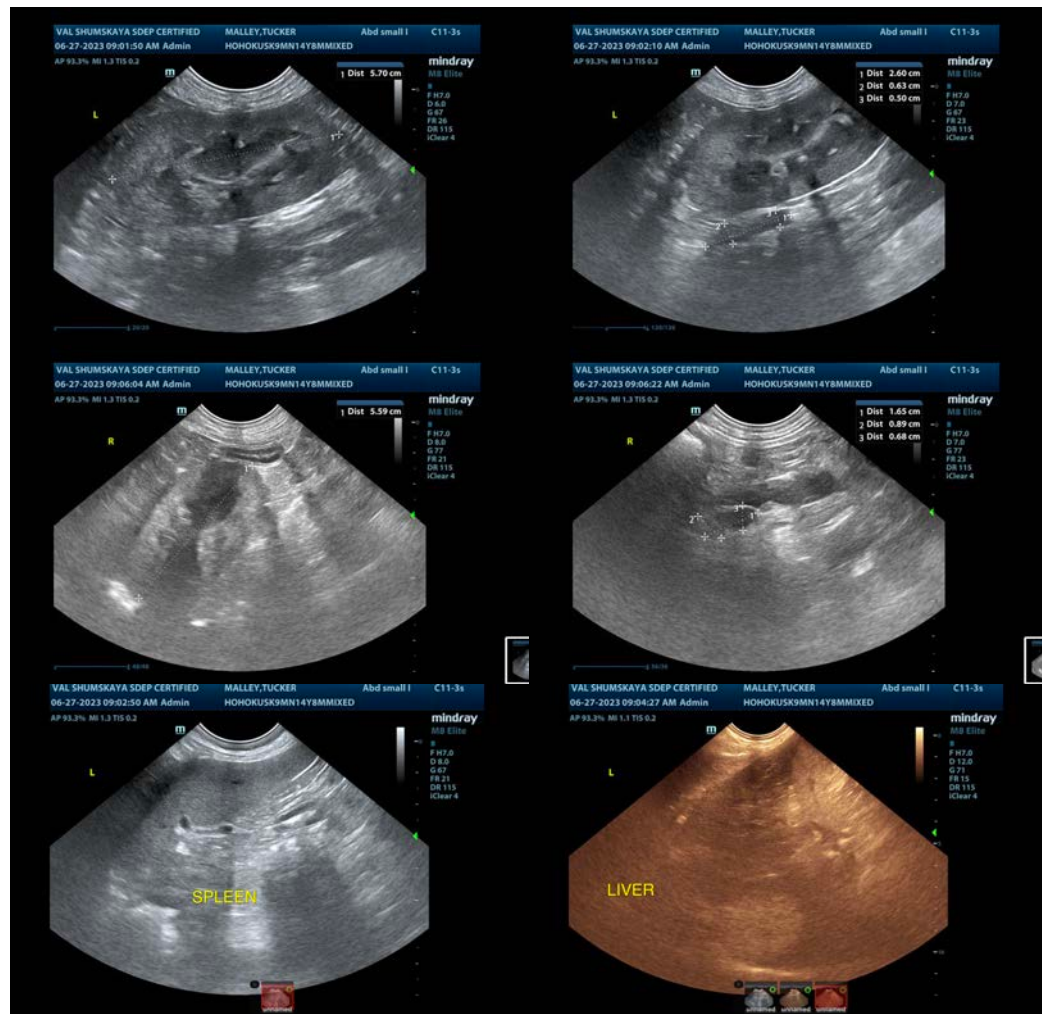
6/27/23

Additionally, you can have fairly significant gastrointestinal symptoms with minimal ultrasonographic changes. Consider the following:

- Consider a novel protein/hydrolyzed protein diet (exclusively at least 4-6 weeks)
- Consider a GI panel to Texas A&M for evaluation of B12 levels, folate, PLI/TLI etc.. to further evaluate for pancreatic/small intestinal disease.
- Consider chronic probiotic therapy.

Recommend three view thoracic radiographs to evaluate for possible concurrent thoracic disease/involvement.

If symptoms are persistent and there are no clues via diagnostics or therapies tried, then consider repeat imaging in the future, looking for progression of any lesions.





PATIENT

Tucker Malley

SPECIES

Canine

BREED

Mixed

SEX

Neutered Male

AGE

14 Years 8 Months

WEIGHT

46.8 Pounds

INTERPRETED BY

Kathleen Sennello DVM,
MS, Diplomate ACVIM
(Small Animal Internal
Medicine)

**IMAGING
PERFORMED BY**

Val Shumskaya

HOSPITAL NAME

Ho-Ho-Kus VH

REFERRING VET

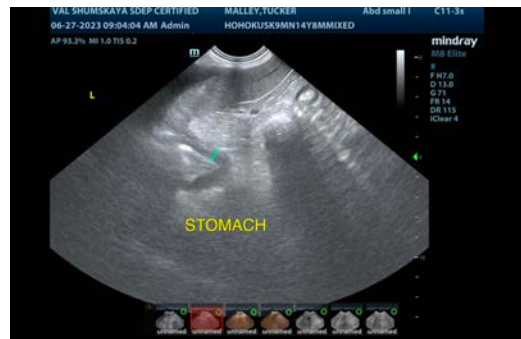Dr. Gannon

INVOICE

43482

DATE

6/27/23



The information and recommendations provided are based on the images presented by the referring veterinarian/sonographer. No evaluation can be communicated regarding pathology that was not visible in the image/video clips provided.

Thank you for this referral. If the clinical or image interpretation does not parallel your findings or if I can be of any further assistance please contact me.

Kathleen Sennello DVM,MS, Diplomate ACVIM (Small animal Internal Medicine)

info@sonopath.com