



PATIENT PRESENTING CLINICAL SIGNS

Nightshade Valenzuela

Nightshade has hx of stable chronic renal disease. PU/PD historically but worsening. Weight loss despite excellent appetite. Non regenerative anemia noted on most recent labs. Normoglycemic.

SPECIES

Feline

Abnormal PE/Chem/CBC/UA Results: Irregular kidneys on palpation, irregular area in cranial abdomen. Weight loss. Obvious gall stones on rads and suspicious mass effect in cranial abdomen. Hematocrit 28%, Hb 9.6 g/dl, low retic BUN 29 mg/dl, Creatinine 2.1 mg/dl, SDMA 12 ug/dl USG 1.015, UPC 0.3

BREED

DSH

ULTRASONOGRAPHIC EXAMINATION OF THE ABDOMEN

SEX

Neutered Male

Urinary System

The urinary bladder is moderately distended with mild primarily suspended echogenic debris present. The Bladder wall, trigone, ureteral papillae and visible urethra (to a depth of 2cm) appear normal with no evidence of wall thickening, mucosal irregularities, masses or calculi. Echogenic debris of this type can be associated with small crystals, cellular debris and proteinaceous debris.

AGE

16 Years

The left kidney has a normal shape and size (4.84 cm). Overall echogenicity is slightly hyperechoic with poor corticomedullary distinction and a typical 1:3 cortex:medulla ratio. There is no evidence of focal perinephric inflammation or effusion. There is no evidence of pyelectasia, nephroliths, infarcts or hydroureter. Renal vasculature is normal.

WEIGHT

8.3 Pounds

The right kidney has a normal shape and size (4.26 cm). Overall echogenicity is slightly hyperechoic with poor corticomedullary distinction and a typical 1:3 cortex:medulla ratio. There is no evidence of focal perinephric inflammation or effusion. There is no evidence of pyelectasia, nephroliths, infarcts or hydroureter. Renal vasculature is normal.

INTERPRETED BY

Kathleen Sennello DVM,
MS, Diplomate ACVIM
(Small Animal Internal
Medicine)

Adrenal Glands

The left adrenal gland is normal in size measuring 0.50 cm at the caudal pole. It is observed in its normal position cranial to the left renal artery. It is normal in appearance (uniformly hypoechoic) and shape with no evidence of a mass effect.

IMAGING PERFORMED BY

Dr. Judy Schroeder

The right adrenal gland is normal in size measuring 0.30 cm at the caudal pole. It is observed in its normal position between the cranial aspect of the right kidney and the caudal vena cava. It is normal in appearance (uniformly hypoechoic) and shape with no evidence of a mass effect.

HOSPITAL NAME

Animal Health
Associates

Spleen

The spleen is subjectively normal in size (0.88 cm), echotexture is homogenous, and the splenic capsule is smooth with no irregularities. The blood flow through the hilus and splenic parenchyma appears normal. No focal parenchymal abnormalities are visualized.

REFERRING VET

Dr. Judy Schroeder

INVOICE

43491

Liver

The liver is subjectively normal in size, and echogenicity with smooth peripheral margins. The parenchyma is homogenous echotexture. The visible portions of the vasculature and biliary tract appear normal. No focal nodules or cystic lesions are observed.

DATE

6/27/23

The gallbladder lumen is moderately distended. The wall of the gall bladder is not thickened and has a smooth mucosal surface. There are numerous shadowing choleliths visualized within the gallbladder lumen. Examples measure 0.71, 0.79, and 0.76 cm. The proximal bile duct is somewhat dilated and slightly tortuous measuring at 0.48 cm. This can be visualized distal to the liver. No obstruction is visualized. No evidence of choleliths visualized causing an obstruction.



PATIENT

Nightshade Valenzuela

SPECIES

Feline

BREED

DSH

SEX

Neutered Male

AGE

16 Years

WEIGHT

8.3 Pounds

INTERPRETED BY

Kathleen Sennello DVM,
MS, Diplomate ACVIM
(Small Animal Internal
Medicine)

**IMAGING
PERFORMED BY**

Dr. Judy Schroeder

HOSPITAL NAME

Animal Health
Associates

REFERRING VET

Dr. Judy Schroeder

INVOICE

43491

DATE

6/27/23

Gastrointestinal

The stomach contains minimal luminal contents. It measures at a normal thickness of <0.36cm with some variability due to the presence of rugal folds. The distinction of the gastric wall layers is adequate and there is no impression of reduced peristaltic activity. No masses or focal lesions were observed.

The visualized areas of duodenum, jejunum and ileum have a relatively uniform diameter with minimal fluid distension. Wall thickness is normal. Bowel loops follow a curvilinear path with distinct wall layering maintaining the typical 1:3 muscularis:mucosa layer ratio. Duodenum wall measures 0.24 cm. Jejunum wall measures 0.22 cm. Visualized peristalsis appears appropriate. There were no focal lesions consistent with obstruction or a mass effect observed.

The ileocecal junction was visualized and exhibited normal intact wall layering and is subjectively of normal thickness. Sections of colon are visualized with formed fecal material and gas shadowing distally. There is no observed focal or generalized colon wall thickening or loss of layering.

Pancreas

The left limb of the pancreas is somewhat obscured by a large ill-defined, mixed echogenic mass effect that appears primarily situated caudal to the stomach, measuring approximately 4.23 cm x 4.33 cm. There is a more focal mottled, hypoechoic region in the mid body of the mass effect, measuring 2.22 cm x 2.38 cm. This could represent a pancreatic mass lesion based on its location. The right limb of the pancreas is not clearly visualized.

Free Abdomen

Evaluation of the peritoneal cavity did not reveal any evidence of effusion, or subjective lymphadenomegaly. The Medial iliac nodes appear normal and there was no evidence of a caudal aortic thrombus at the bifurcation. The mesentery is hyperechoic around the cranial abdominal mass.

PRIMARY FINDINGS

- Large, mixed echogenic, complex, ill-defined mass effect visualized in the left cranial abdomen caudal to the stomach – Based on its location, a pancreatic mass lesion would be most likely, although other differentials such as splenic or hepatic origins are possible.
- Decreased corticomedullary distinction in both kidneys – Mild loss of corticomedullary distinction in both kidneys could be consistent with chronic degenerative disease or interstitial nephrosis.
- Shadowing stones visualized within the gallbladder and mild bile duct dilation – Findings are consistent with multiple choleliths – Dilation of the common bile duct could be consistent with a functional obstruction (i.e. primary hepatic disease resulting in hepatocellular swelling) or with an extrahepatic bile duct obstruction (ie. choledocholith, bile duct tumor, pancreatic disease, other).

SECONDARY FINDINGS

- Echogenic debris in the urinary bladder – The echogenic debris in the bladder lumen could be consistent with cells, crystals, and/or mucus.



PATIENT

Nightshade Valenzuela

SPECIES

Feline

BREED

DSH

SEX

Neutered Male

AGE

16 Years

WEIGHT

8.3 Pounds

INTERPRETED BY

Kathleen Sennello DVM,
MS, Diplomate ACVIM
(Small Animal Internal
Medicine)

IMAGING PERFORMED BY

Dr. Judy Schroeder

HOSPITAL NAME

Animal Health
Associates

REFERRING VET

Dr. Judy Schroeder

INVOICE

43491

DATE

6/27/23

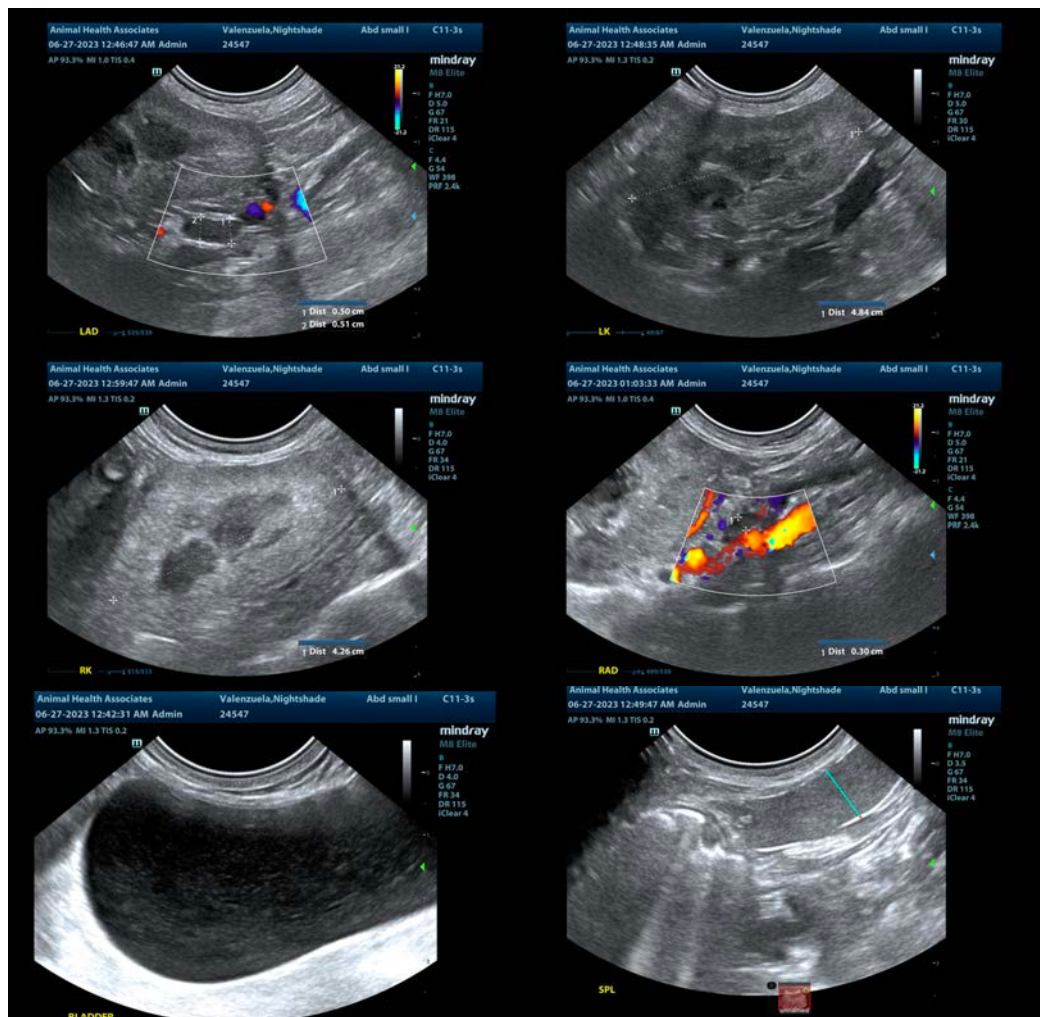
INTERPRETATION OF THE FINDINGS & FURTHER RECOMMENDATIONS

There is a large, mixed echogenic, somewhat ill-defined mass effect visualized in the left cranial abdomen caudal to the stomach. The location of this lesion is concerning for a possible pancreatic mass lesion, although other differentials such as a splenic or hepatic mass lesion are possible. Recommend a fine needle aspirate of the mass. If surgical intervention is desired, it is likely that a contrast CT scan would be recommended for surgical planning and to better identify the source of this lesion.

Recommend three view thoracic radiographs to evaluate for possible concurrent thoracic disease/involvement.

There are numerous choleliths visualized and mild bile duct dilation, but overall, there is not a lot of inflammation visualized associated with this lesion. Correlate with lab work findings. If liver enzymes are elevated, consider treating for cholecystitis and continued monitoring. If persistent clinical signs and/or liver enzyme elevations are noted, surgical removal could be considered, but I suspect this is not the primary issue at this time.

Recommend a blood pressure, urinalysis and culture to further evaluate the kidneys and the debris visualized in the urinary bladder.





PATIENT

Nightshade Valenzuela

SPECIES

Feline

BREED

DSH

SEX

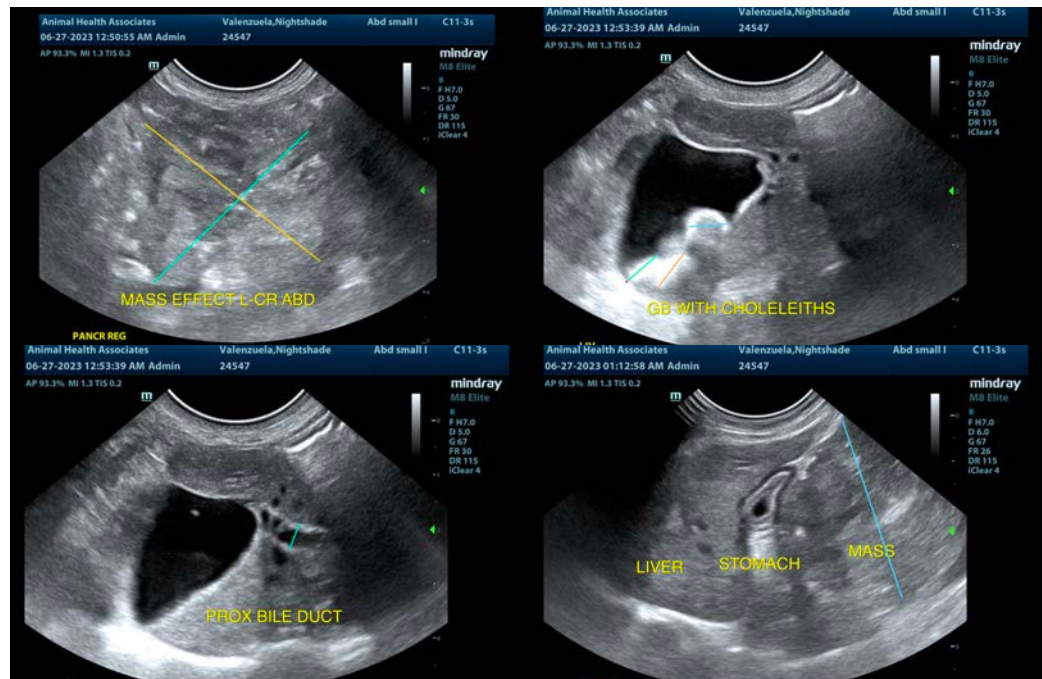
Neutered Male

AGE

16 Years

WEIGHT

8.3 Pounds



INTERPRETED BY

Kathleen Sennello DVM,
MS, Diplomate ACVIM
(Small Animal Internal
Medicine)

IMAGING PERFORMED BY

Dr. Judy Schroeder

HOSPITAL NAME

Animal Health
Associates

REFERRING VET

Dr. Judy Schroeder

INVOICE

43491

DATE

6/27/23

The information and recommendations provided are based on the images presented by the referring veterinarian/sonographer. No evaluation can be communicated regarding pathology that was not visible in the image/video clips provided.

Thank you for this referral. If the clinical or image interpretation does not parallel your findings or if I can be of any further assistance please contact me.

Kathleen Sennello DVM,MS, Diplomate ACVIM (Small animal Internal Medicine)

info@sonopath.com