



PATIENT PRESENTING CLINICAL SIGNS

Hanuman Margolis

Grade 3/6 heart murmur(parasternal) noted on 6/19/23 when presented for sedated groom. Also previously noted in 2021 but no echo in record.

SPECIES

Feline

Abnormal PE/Chem/CBC/UA Results: CKD stage 2 as of June 2023.; Ca 10.9; Previous AUS - FEB 2023 for staging /grading for MCT in Jan 2023.

BREED

DSH

ULTRASONOGRAPHIC EXAMINATION OF THE ABDOMEN

Urinary System

SEX

Neutered Male

The urinary bladder is moderately distended with anechoic urine. The Bladder wall, trigone, ureteral papillae and visible urethra (to a depth of 2cm) appear normal with no evidence of wall thickening, mucosal irregularities, masses or cystic calculi.

AGE

12

The left kidney has a normal shape and size (3.68 cm). Overall echogenicity is normal with adequate corticomedullary distinction and a typical 1:3 cortex:medulla ratio. There is no evidence of focal perinephric inflammation or effusion. There is no evidence of pyelectasia, nephroliths, infarcts or hydroureter. Renal vasculature is normal.

WEIGHT

13.13

The right kidney has a normal shape and size (4.21 cm). Overall echogenicity is normal with adequate corticomedullary distinction and a typical 1:3 cortex:medulla ratio. There is no evidence of focal perinephric inflammation or effusion. There is no evidence of pyelectasia, nephroliths, infarcts or hydroureter. Renal vasculature is normal.

INTERPRETED BY

Kathleen Sennello DVM,
MS, Diplomate ACVIM
(Small Animal Internal
Medicine)

Adrenal Glands

The region of left adrenal (Cranial to left renal artery) is unremarkable but the adrenal is not distinctly visualized. No evidence of a mass effect is visualized.

IMAGING PERFORMED BY

Elaina Petrone

The region of the right adrenal (between right cranial kidney and vena cava) is unremarkable, but the adrenal is not distinctly visualized. No evidence of a mass effect is visualized.

HOSPITAL NAME

Long Branch AH

Spleen

The spleen is subjectively normal in size (0.85 cm), echotexture is homogenous, and the splenic capsule is smooth with no irregularities. The blood flow through the hilus and splenic parenchyma appears normal. No focal parenchymal abnormalities are visualized.

REFERRING VET

Dr. Elizabeth Griffin

Liver

The liver is subjectively normal in size, and echogenicity with smooth peripheral margins. The parenchyma is homogenous echotexture. The visible portions of the vasculature and biliary tract appear normal. No focal nodules or cystic lesions are observed.

INVOICE

43505

The gallbladder lumen is moderately distended. The wall of the gall bladder is not thickened and has a smooth mucosal surface. Luminal contents are mild and primarily anechoic. The cystic and common bile ducts are normal/not visible.

DATE

6/27/23

Gastrointestinal

The stomach contains minimal luminal contents. It measures at a normal thickness of <0.36cm with some variability due to the presence of rugal folds. The distinction of the gastric wall layers is adequate and there is no impression of reduced peristaltic activity. No masses or focal lesions were observed.



PATIENT

Hanuman Margolis

SPECIES

Feline

BREED

DSH

SEX

Neutered Male

AGE

12

WEIGHT

13.13

INTERPRETED BY

Kathleen Sennello DVM,
MS, Diplomate ACVIM
(Small Animal Internal
Medicine)

IMAGING PERFORMED BY

Elaina Petrone

HOSPITAL NAME

Long Branch AH

REFERRING VET

Dr. Elizabeth Griffin

INVOICE

43505

DATE

6/27/23

The visualized areas of duodenum, jejunum and ileum have a relatively uniform diameter with minimal fluid distension. Wall thickness is normal. Bowel loops follow a curvilinear path with distinct wall layering maintaining the typical 1:3 muscularis:mucosa layer ratio. Jejunum wall measures 0.20 cm. Visualized peristalsis appears appropriate. There were no focal lesions consistent with obstruction or a mass effect observed.

The ileocecal junction was visualized and exhibited normal intact wall layering and is subjectively of normal thickness. Sections of colon are visualized with formed fecal material and gas shadowing distally. There is no observed focal or generalized colon wall thickening or loss of layering.

Pancreas

The pancreas is normal and isoechoic to surrounding mesentery. There is no evidence of nodules or cystic lesions. There is no evidence of regional mesenteric inflammation or fluid.

Free Abdomen

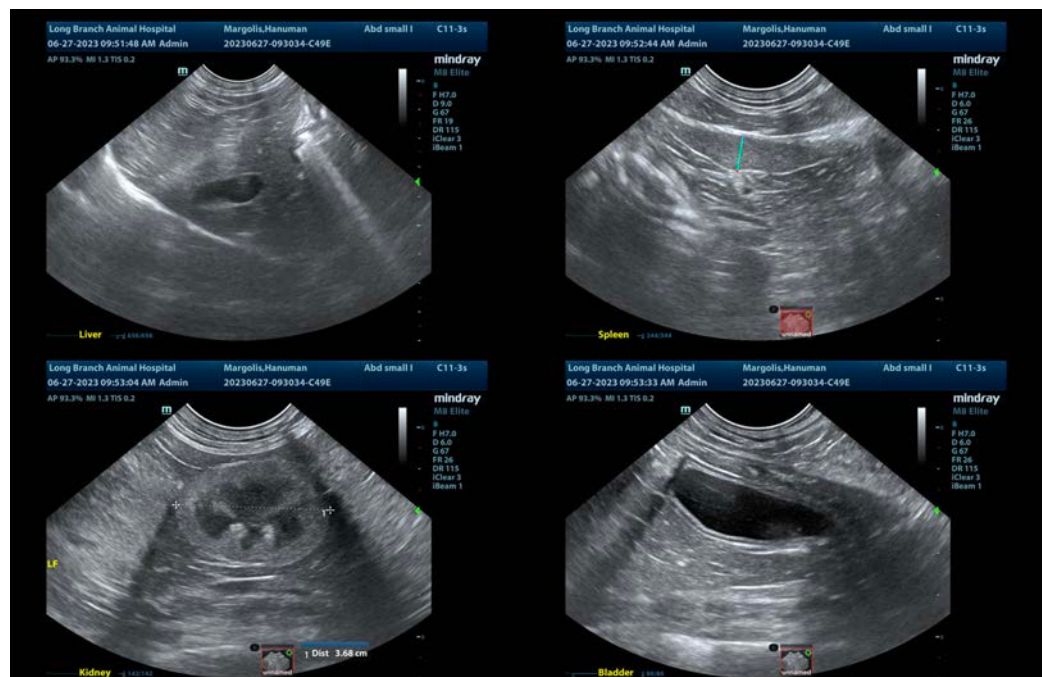
Evaluation of the peritoneal cavity did not reveal any evidence of effusion. Mesenteric lymph nodes are slightly prominent, measuring 0.20, 0.24, and 0.30 cm. The omentum is of normal echogenicity.

ULTRASONOGRAPHIC FINDINGS

- No significant ultrasonographic lesions visualized

INTERPRETATION OF THE FINDINGS & FURTHER RECOMMENDATIONS

Today's scan appears relatively normal and stable from the previous exam in 2/2023. No focal lesions are visualized associated with the kidneys such as pyelectasia, nodules, etc. The appearance of the kidneys does not always correlate with their function. Recommend a blood pressure, urinalysis, culture, and urine protein to creatinine ratio as a baseline if this has not already been done.





PATIENT

Hanuman Margolis

SPECIES

Feline

BREED

DSH

SEX

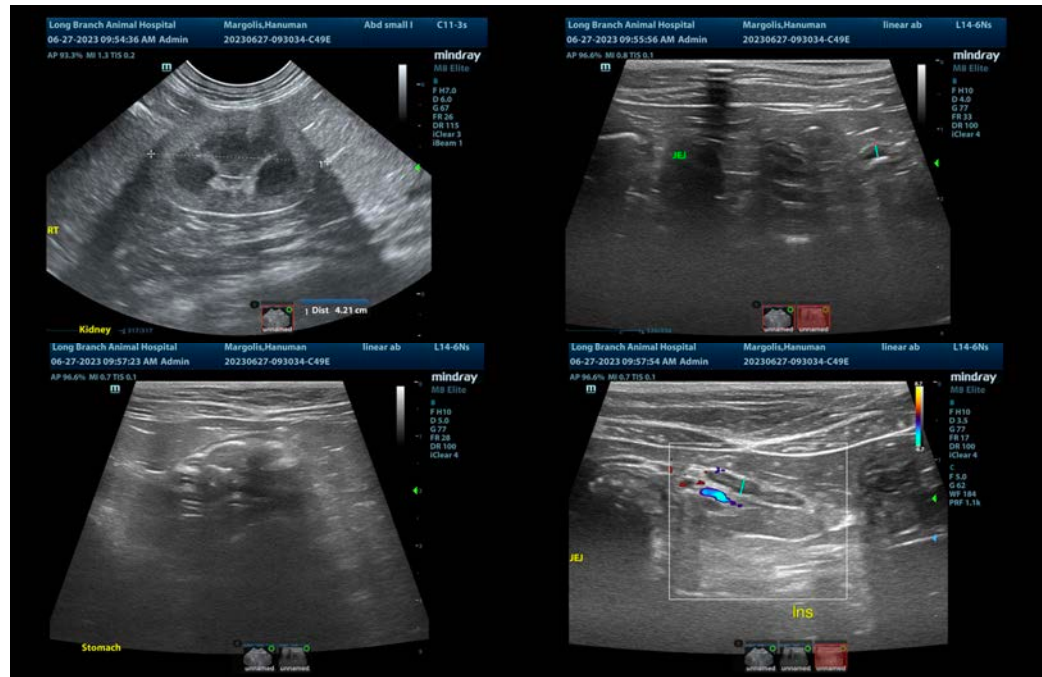
Neutered Male

AGE

12

WEIGHT

13.13



INTERPRETED BY

Kathleen Sennello DVM,
MS, Diplomate ACVIM
(Small Animal Internal
Medicine)

The information and recommendations provided are based on the images presented by the referring veterinarian/sonographer. No evaluation can be communicated regarding pathology that was not visible in the image/video clips provided.

Thank you for this referral. If the clinical or image interpretation does not parallel your findings or if I can be of any further assistance please contact me.

Kathleen Sennello DVM,MS, Diplomate ACVIM (Small animal Internal Medicine)

IMAGING PERFORMED BY

Elaina Petrone

info@sonopath.com

HOSPITAL NAME

Long Branch AH

REFERRING VET

Dr. Elizabeth Griffin

INVOICE

43505

DATE

6/27/23