


**PATIENT PRESENTING CLINICAL SIGNS**

**Patient:** Franz Kunkel  
**History:** Presented at our hospital for NE since Thursday, weight loss, lethargy, V+ once last night.  
**Previous Health Concerns:** none **Current Medications:** none **Appetite/When did they eat last:** decreasing/Thursday

**SPECIES:** Abnormal PE/Chem/CBC/UA **Results:** Abdominal: doughy; irregular kidney vs mass near spine Rads: midabdominal mass

**Feline**

**ULTRASONOGRAPHIC EXAMINATION OF THE ABDOMEN**
**BREED** *Urinary System*

**DSH** The urinary bladder is moderately distended with anechoic urine. The bladder wall, trigone, ureteral papillae and visible urethra (to a depth of 2cm) appear normal with no evidence of wall thickening, mucosal irregularities, masses or cystic calculi.

**SEX**

Neutered Male

The left kidney has a normal shape and size (4.21 cm). Overall echogenicity is normal with adequate corticomedullary distinction and a typical 1:3 cortex:medulla ratio. There is no evidence of perinephric inflammation or effusion. There is no evidence of pyelectasia, nephroliths, infarcts or hydroureter. Renal vasculature is normal.

**AGE**

11 years

The right kidney has a normal shape and size (4.77 cm). Overall echogenicity is normal with adequate corticomedullary distinction and a typical 1:3 cortex:medulla ratio. There is no evidence of perinephric inflammation or effusion. There is no evidence of pyelectasia, nephroliths, infarcts or hydroureter. Renal vasculature is normal.

**WEIGHT**

6.12 kg

*Adrenal Glands*

The area of the left adrenal gland is normal in size. It is observed in its normal position cranial to the left renal artery. It is normal in appearance (uniformly hypoechoic) and shape with no evidence of a mass effect.

**INTERPRETED BY**

Kathleen Sennello  
 DVM, MS, Diplomate  
 ACVIM (Small Animal  
 Internal Medicine)

The area of the right adrenal gland is normal in size. It is observed in its normal position between the cranial aspect of the right kidney and the caudal vena cava. It is normal in appearance (uniformly hypoechoic) and shape with no evidence of a mass effect.

*Spleen*

The spleen is normal in size (0.67 cm in width at the level of the hilus), echotexture is homogenous, and the splenic capsule is smooth with no irregularities. The blood flow through the hilus and splenic parenchyma appears normal. No focal parenchymal abnormalities are visualized.

**IMAGING PERFORMED BY**

Erin Wicks

*Liver*

The liver is subjectively normal in size, and echogenicity with smooth peripheral margins. The parenchyma is homogenous echotexture. The visible portions of the vasculature and biliary tract appear normal. No focal nodules or cystic lesions are observed. The gall bladder lumen is moderately distended. The wall of the gall bladder is not thickened and has a smooth mucosal surface. Luminal contents are primarily anechoic. The cystic and common bile ducts are normal/not visible.

**HOSPITAL NAME**

Shores VEC

**REFERRING VET**

Dr Miller

*Gastrointestinal*

The stomach contains minimal luminal contents. It measures at a normal thickness of <0.36cm with some variability due to the presence of rugal folds. The distinction of the gastric wall layers is adequate and there is no impression of reduced peristaltic activity. No masses or focal lesions were observed.

**INVOICE**

13490

The visualized areas of duodenum, jejunum and ileum have a uniform diameter with minimal fluid distension. Wall thickness is normal to slightly increased. Bowel loops follow a typical curvilinear path with distinct wall layering, but some areas display a prominent muscularis layer which does not display the

**DATE**

6.26.23



**PATIENT** Franz Kunkel  
**SPECIES** Feline  
 typical 1:3 muscularis:mucosa layer ratio. The jejunum measured 0.29 mm in diameter. Visualized peristalsis appears appropriate. There is a large, irregular hypoechoic mass effect visualized in the abdomen. This abnormal tissue is associated with thickened irregular bowel, most consistent with a focal bowel mass, with complete loss of wall layering. This mass effect measures 5.40 x 5.04 cm. The bowel wall in this area measures >1.17 cm in wall thickness. It is difficult to determine if there is more than one mass effect, or an irregularly-shaped, somewhat extensive single mass effect.

**BREED** DSH  
 The ileocecal junction was visualized and exhibited normal intact wall layering and is subjectively of normal thickness. Sections of colon are visualized with formed fecal material and gas shadowing distally. There is no observed focal or generalized colon wall thickening or loss of layering.

**SEX** Neutered Male  
**Pancreas**  
 The area of the left limb of the pancreas appears relatively normal, with no evidence of significant inflammation or tissue irregularity. In the region of the right limb of the pancreas, there is a large hypoechoic, inflamed mass effect, which I suspect is bowel in origin. Normal pancreas is not clearly visualized.

**AGE** 11 years  
**Free Abdomen**  
 Evaluation of the peritoneal cavity did not reveal any free fluid, or subjective lymphadenomegaly. The mesentery is severely hyperechoic around the bowel mass. The Medial iliac nodes appear normal and there was no evidence of a caudal aortic thrombus at the bifurcation. The omentum is of normal uniform echogenicity.

## ULTRASONOGRAPHIC FINDINGS

### Primary Findings

- Diffuse thickening of the small intestine with focal area/area(s) of bowel, severely irregular surrounding tissue, and thickened walls with complete loss of layering. – Findings are most consistent with a bowel mass. Primary differentials would be round cell neoplasia, carcinoma, other.

## INTERPRETATION OF THE FINDINGS & FURTHER RECOMMENDATIONS

There is a large cranial/midabdominal mass effect visualized, associated with the small bowel. The abnormal tissue is arising from the wall of the small intestine and progresses to a large expansile mass effect, which is hypoechoic with complete loss of layering. This is most consistent with an irregular, large cranial abdominal mass effect, although two irregular mass effects are also possible. A primary differential would be a neoplastic process (round cell neoplasia, carcinoma, other), although other differentials exist. Recommend a fine-needle aspirate of the bowel mass and three-view thoracic radiographs.

## INTERPRETED BY

Kathleen Sennello  
DVM, MS, Diplomate  
ACVIM (Small Animal  
Internal Medicine)

## IMAGING PERFORMED BY

Erin Wicks

## HOSPITAL NAME

Shores VEC

## REFERRING VET

Dr Miller

## INVOICE

13490

## DATE

6.26.23



**PATIENT**

Franz Kunkel

**SPECIES**

Feline

**BREED**

DSH

**SEX**

Neutered Male

**AGE**

11 years

**WEIGHT**

6.12 kg

**INTERPRETED BY**

Kathleen Sennello  
DVM, MS, Diplomate  
ACVIM (Small Animal  
Internal Medicine)

**IMAGING  
PERFORMED BY**

Erin Wicks

**HOSPITAL NAME**

Shores VEC

**REFERRING VET**

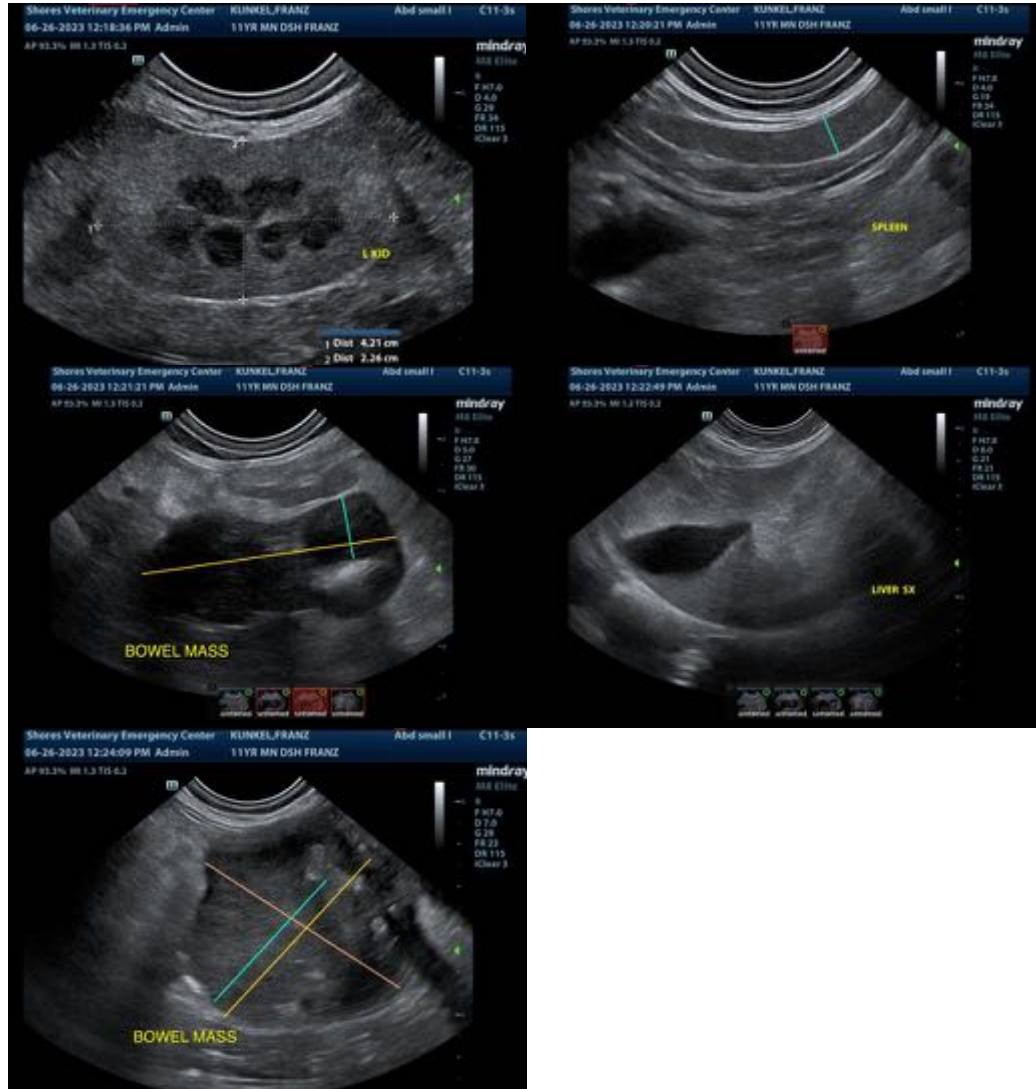
Dr Miller

**INVOICE**

13490

**DATE**

6.26.23



The information and recommendations provided are based on the images presented by the referring veterinarian. No evaluation can be communicated regarding pathology that was not visible in the image/video clips provided.

Thank you for this referral. If the clinical or image interpretation does not parallel your findings or if I can be of any further assistance, please contact me.

Kathleen Sennello DVM, MS, Diplomate ACVIM (Small animal Internal Medicine)  
[info@SonoPath.com](mailto:info@SonoPath.com)