



PATIENT PRESENTING CLINICAL SIGNS

Martie Geissinger Presented at our hospital for lethargy, not acting right. P did go to Rdvm and had high BG – 398. Transferred here for care. Previous Health Concerns: c-section done prior to O getting P, allergies
SPECIES Current Medications/Supplements/OTC: none

Canine Abnormal PE/Chem/CBC/UA Results: 4DX: neg UA: 1.024, 2+ glucose, 1+ ketones, no bacteria or blood cells Chem: ALP >2000, ALT 133, Amyl 454, GGT 29, Glu 398, Lipase 2795, K 2.5, Na 141, Cl 94 CBC: HCT 38.7%, WBC 23.5k, neut 18.6k, PLT 696 BG intake 419 Ketometer at intake 4.8mM

Shih Tzu ULTRASONOGRAPHIC EXAMINATION OF THE ABDOMEN

SEX Urinary System

Spayed Female The urinary bladder is moderately distended with anechoic urine. The Bladder wall, trigone, ureteral papillae and visible urethra (to a depth of 2cm) appear normal with no evidence of wall thickening, mucosal irregularities, masses or cystic calculi.

AGE

6 Years The left kidney has a normal shape and size (5.01 cm). Overall echogenicity is normal with adequate corticomedullary distinction and a typical 1:3 cortex:medulla ratio. There is no evidence of focal perinephric inflammation or effusion. There is no evidence of pyelectasia, nephroliths, infarcts or hydroureter. Renal vasculature is normal.

WEIGHT

5.2 kg

The right kidney has a normal shape and size (5.19 cm). Overall echogenicity is normal with adequate corticomedullary distinction and a typical 1:3 cortex:medulla ratio. There is no evidence of focal perinephric inflammation or effusion. There is no evidence of pyelectasia, nephroliths, infarcts or hydroureter. Renal vasculature is normal.

INTERPRETED BY

Kathleen Sennello DVM, MS, Diplomate ACVIM (Small Animal Internal Medicine)

Adrenal Glands

The left adrenal gland is normal in size measuring 0.62 cm at the caudal pole. It is observed in its normal position cranial to the left renal artery. It is normal in appearance (uniformly hypoechoic) and shape with no evidence of a mass effect.

IMAGING PERFORMED BY

Erin Wicks

The right adrenal gland is normal in size measuring 0.57 cm at the caudal pole. It is observed in its normal position between the cranial aspect of the right kidney and the caudal vena cava. It is normal in appearance (uniformly hypoechoic) and shape with no evidence of a mass effect.

HOSPITAL NAME

Shores VEC

Spleen

REFERRING VET

Dr. Welti

The spleen is subjectively normal in size, echotexture is homogenous, and the splenic capsule is smooth with no irregularities. The blood flow through the hilus and splenic parenchyma appears normal. No focal parenchymal abnormalities are visualized.

INVOICE

43399

Liver

DATE

6/23/23

The liver is large with smooth peripheral margins. The parenchyma is hyperechoic and homogenous in echotexture. The visible portions of the vasculature and biliary tract appear normal. No focal nodules or cystic lesions are observed.

The gallbladder lumen is moderately distended. The wall of the gall bladder is not thickened and has a smooth mucosal surface. Luminal contents are mild and primarily anechoic. The cystic and common bile ducts are normal/not visible.



PATIENT *Gastrointestinal*

Martie Geissinger

The stomach contains moderate fluid/ingesta. It measures at a normal thickness of <0.7cm with some variability due to the presence of rugal folds. The distinction of the gastric wall layers is adequate and there is no impression of reduced peristaltic activity. No masses or focal lesions were observed.

SPECIES

Canine

The visualized areas of duodenum, jejunum and ileum have a relatively uniform diameter with minimal fluid distension. Wall thickness is normal. Bowel loops follow a curvilinear path with distinct wall layering maintaining the typical 1:3 muscularis:mucosa layer ratio. Jejunum wall measures 0.27 cm.

BREED

Shih Tzu

Visualized peristalsis appears appropriate. There were no focal lesions consistent with obstruction or a mass effect observed.

SEX

Spayed Female

The ileocecal junction was visualized and exhibited normal intact wall layering and is subjectively of normal thickness. Sections of colon are visualized with formed fecal material and gas shadowing distally. There is no observed focal or generalized colon wall thickening or loss of layering.

AGE

6 Years

Pancreas

The area of the pancreas is normal and isoechoic to surrounding mesentery. There is no evidence of nodules or cystic lesions. There is no evidence of regional mesenteric inflammation or fluid.

WEIGHT

5.2 kg

Free Abdomen

Evaluation of the peritoneal cavity did not reveal any evidence of effusion, or subjective lymphadenomegaly. The Medial iliac nodes appear normal and there was no evidence of a caudal aortic thrombus at the bifurcation. The omentum is of normal uniform echogenicity.

INTERPRETED BY

Kathleen Sennello DVM,
MS, Diplomate ACVIM
(Small Animal Internal
Medicine)

ULTRASONOGRAPHIC FINDINGS

- Large, hyperechoic liver – The diffuse hepatic changes are non-specific and can be seen with vacuolar hepatopathy, reactive change, nodular hyperplasia or, less likely, inflammatory/immune-mediated disease, infiltrative neoplasia, or other hepatopathy. This is likely consistent with a diabetic hepatopathy.
- Moderate fluid and ingesta visualized within the gastric lumen – Correlate with feeding history. If the patient was adequately fasted, consider such differentials as delayed gastric emptying, a partial outflow tract obstruction, etc. (none seen).

IMAGING PERFORMED BY

Erin Wicks

HOSPITAL NAME

Shores VEC

INTERPRETATION OF THE FINDINGS & FURTHER RECOMMENDATIONS

REFERRING VET

Dr. Welti

Many of the changes observed on today's scan are commonly seen in unregulated diabetic patients. I did not visualize any evidence of pancreatic inflammation on today's exam, but that does not definitively rule out pancreatitis. Correlate these findings with a quantitative PLI level. Recommend a urinalysis and culture and treatment for diabetic ketoacidosis. If the patient is not feeling better, you could consider a liver function test and a fine needle aspirate of the liver.

INVOICE

43399

DATE

6/23/23



PATIENT

Martie Geissinger

SPECIES

Canine

BREED

Shih Tzu

SEX

Spayed Female

AGE

6 Years

WEIGHT

5.2 kg

INTERPRETED BY

Kathleen Sennello DVM,
MS, Diplomate ACVIM
(Small Animal Internal
Medicine)

**IMAGING
PERFORMED BY**

Erin Wicks

HOSPITAL NAME

Shores VEC

REFERRING VET

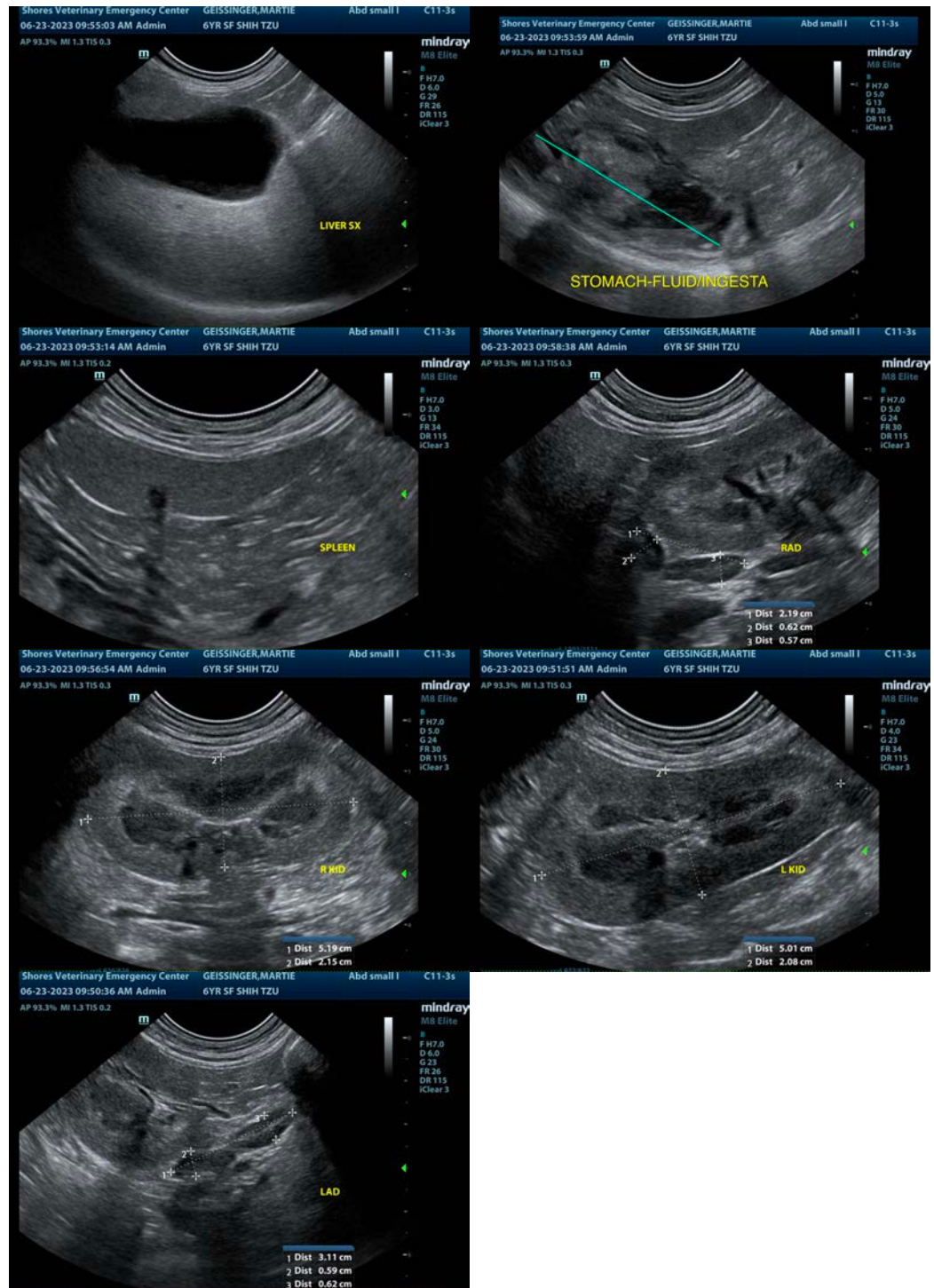
Dr. Welti

INVOICE

43399

DATE

6/23/23



The information and recommendations provided are based on the images presented by the referring veterinarian/sonographer. No evaluation can be communicated regarding pathology that was not visible in the image/video clips provided.

Thank you for this referral. If the clinical or image interpretation does not parallel your findings or if I can be of any further assistance please contact me.

Kathleen Sennello DVM,MS, Diplomate ACVIM (Small animal Internal Medicine) info@sonopath.com