



PATIENT

Watson Houge

PRESENTING CLINICAL SIGNS

SPECIES

Canine

BREED

Beagle X

light sedation with butorphanol and alfaxalone IV-
Abnormal PE/Chem/CBC/JA Results: Chief Concern / Provisional Diagnosis: ~Has a large Semi-soft inguinal mass. Determination if mass or inguinal herniation Also has 2/6 cardiac murmur New Finding.~ Relevant Medical History and Physical Exam findings: ~2/6 murmur Other skin tags and smaller masses. Concerning inguinal mass, unable to determine if Herniation involved. US of area to determine if issue or just mass so can have removed.~ Recent Diagnostics: Relevant Laboratory Results / Abnormalities: ~Not performed as yet.~ Current medications (include full name, dosage and frequency): ~None Relevant Radiograph Findings(email radiographs if available): ~Owner declined~

SEX

Neutered Male

AGE

9 Years 2 Months

WEIGHT

40.8 Pounds

ULTRASONOGRAPHIC EXAMINATION OF THE ABDOMEN

Urinary System

The urinary bladder is moderately distended with anechoic urine. The Bladder wall, trigone, ureteral papillae and visible urethra (to a depth of 2cm) appear normal with no evidence of wall thickening, mucosal irregularities, masses or cystic calculi.

The prostate is normal in size (1.14 cm) and shape for this neutered male dog. The parenchyma is homogenous and the external margins are smooth. The prostatic urethra appears normal with no evidence of irregularity, invasion, mass effect or calculi.

The left kidney has a normal shape and size (7.23 cm). Overall echogenicity is normal with adequate corticomedullary distinction and a typical 1:3 cortex:medulla ratio. There is no evidence of perinephric inflammation or effusion. There is no evidence of pyelectasia, nephroliths, infarcts or hydronephrosis. Renal vasculature is normal.

The right kidney has a normal shape and size (6.7 cm). Overall echogenicity is normal with adequate corticomedullary distinction and a typical 1:3 cortex:medulla ratio. There is no evidence of perinephric inflammation or effusion. There is no evidence of pyelectasia, nephroliths, infarcts or hydronephrosis. Renal vasculature is normal.

Adrenal Glands

The left adrenal gland is normal in size measuring 0.74 cm at the caudal pole. It is observed in its normal position cranial to the left renal artery. It is normal in appearance (uniformly hypoechoic) and shape with no evidence of a mass effect.

The region of the right adrenal (between right cranial kidney and vena cava) is unremarkable, but the adrenal is not distinctly visualized. No evidence of a mass effect.

Spleen

The spleen is subjectively normal in size, echotexture is homogenous, and the splenic capsule is smooth with no irregularities. The blood flow through the hilus and splenic parenchyma appears normal. No focal parenchymal abnormalities are visualized.

INTERPRETED BY

Kathleen Sennello DVM,
MS, Diplomate ACVIM
(Small Animal Internal
Medicine)

IMAGING BY

Loetitia Saint-Jacques,
LVT

HOSPITAL NAME

MountainView AH

REFERRING VET

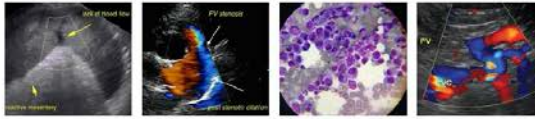
Dr. Kris Kingrey

INVOICE

39056

DATE

6/23/22



PATIENT

Watson Houge

Liver

The liver is subjectively normal in size, and echogenicity with smooth peripheral margins. The parenchyma is homogenous echotexture. The visible portions of the vasculature and biliary tract appear normal. No focal nodules or cystic lesions are observed.

SPECIES

Canine

The gallbladder lumen is moderately distended. The wall of the gall bladder is not thickened and has a smooth mucosal surface. Luminal contents are primarily anechoic. The cystic and common bile ducts are normal/not visible.

BREED

Beagle X

Gastrointestinal

The stomach contains minimal luminal contents. It measures at a normal thickness of <0.7cm with some variability due to the presence of rugal folds. The distinction of the gastric wall layers is adequate and there is no impression of reduced peristaltic activity. No masses or focal lesions were observed.

SEX

Neutered Male

The visualized areas of duodenum, jejunum and ileum have a relatively uniform diameter with minimal fluid distension. Wall thickness is normal. Bowel loops follow a curvilinear path with distinct wall layering maintaining the typical 1:3 muscularis:mucosa layer ratio. The duodenum measured as normal (between 0.3-0.5cm in wall thickness) and the jejunum measured as normal (between 0.2-0.47cm.) Visualized peristalsis appears appropriate. There were no focal lesions consistent with obstruction or a mass effect observed.

AGE

9 Years 2 Months

WEIGHT

40.8 Pounds

The ileocecal junction was visualized and exhibited normal intact wall layering and is subjectively of normal thickness. Sections of colon are visualized with formed fecal material and gas shadowing distally. There is no observed focal or generalized colon wall thickening or loss of layering.

INTERPRETED BY

Kathleen Sennello DVM,
MS, Diplomate ACVIM
(Small Animal Internal
Medicine)

Pancreas

The pancreas is normal and isoechoic to surrounding mesentery. There is no evidence of nodules or cystic lesions. There is no evidence of regional mesenteric inflammation or fluid.

Free Abdomen

Evaluation of the peritoneal cavity did not reveal any evidence of effusion, or subjective lymphadenomegaly. The Medial iliac nodes appear normal and there was no evidence of a caudal aortic thrombus at the bifurcation. The omentum is of normal uniform echogenicity.

IMAGING BY

Loetitia Saint-Jacques,
LVT

Other

A mass effect in the inguinal area is imaged in efforts to differentiate between a lipoma and an inguinal hernia. This lesion is >4.8 cm in width and 3.3 cm in depth and is heterogeneous and isoechoic to the surrounding fat and tissue. These findings are most consistent with a lipoma. An inguinal hernia with herniated fat would be an alternate differential. No evidence of bowel loops, etc. are visualized.

HOSPITAL NAME

MountainView AH

REFERRING VET

Dr. Kris Kingrey

ULTRASONOGRAPHIC FINDINGS

- Suspect lipoma in the inguinal region

INTERPRETATION OF THE FINDINGS & FURTHER RECOMMENDATIONS

INVOICE

39056

Today's scan is normal for a 9 year old Beagle. The inguinal mass lesion appears to obtain fat opacity tissue and is most consistent with a lipoma. An inguinal hernia with herniated fat would be

DATE

6/23/22



PATIENT

Watson Houge

an alternate differential. Despite the findings of this ultrasound, caution is warranted at the time of surgery, as with any mass removal.

SPECIES

Canine

BREED

Beagle X

SEX

Neutered Male

AGE

9 Years 2 Months

WEIGHT

40.8 Pounds

INTERPRETED BY

Kathleen Sennello DVM,
MS, Diplomate ACVIM
(Small Animal Internal
Medicine)

IMAGING BY

Loetitia Saint-Jacques,
LVT

HOSPITAL NAME

MountainView AH

REFERRING VET

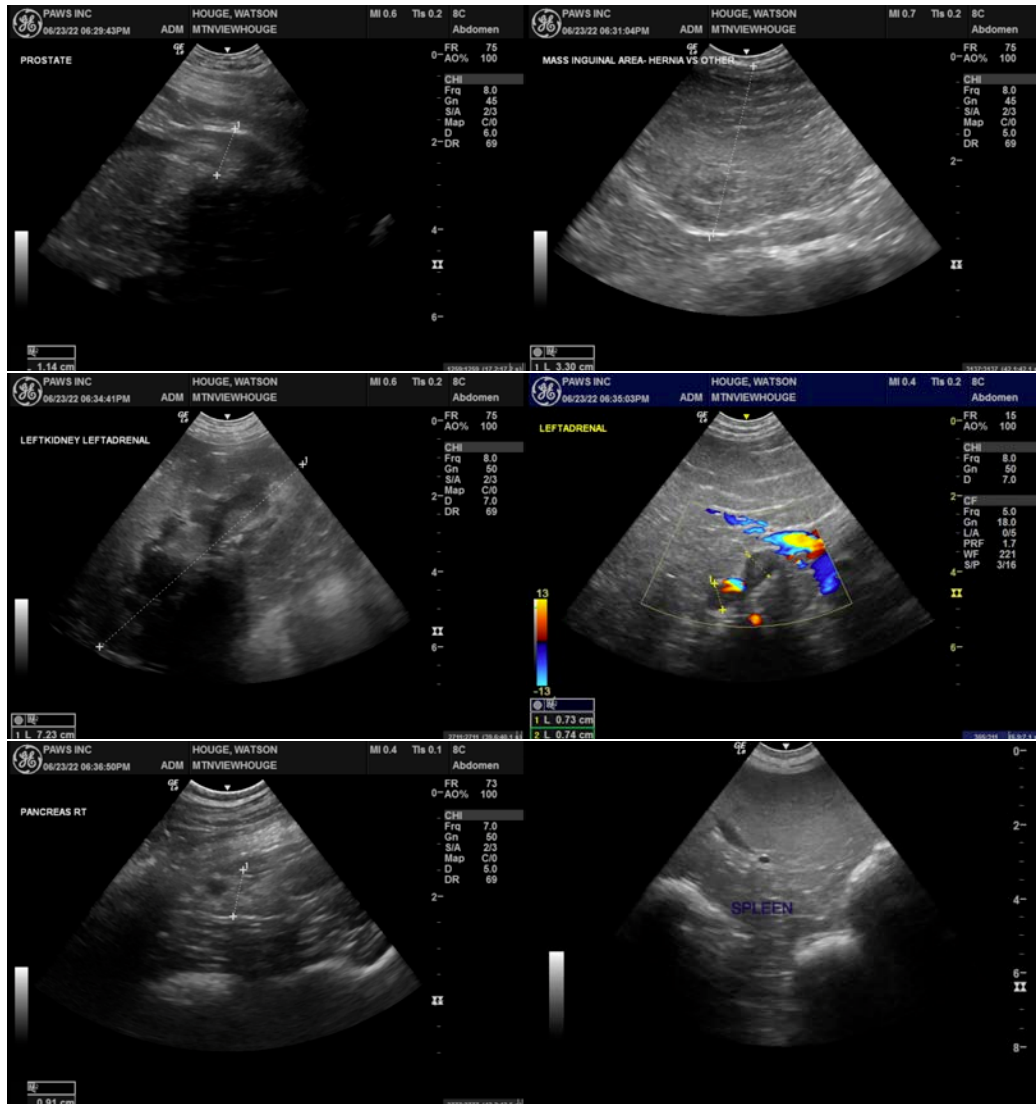
Dr. Kris Kingrey

INVOICE

39056

DATE

6/23/22





PATIENT

Watson Houge

SPECIES

Canine

BREED

Beagle X

SEX

Neutered Male

AGE

9 Years 2 Months

WEIGHT

40.8 Pounds

INTERPRETED BY

Kathleen Sennello DVM,
MS, Diplomate ACVIM
(Small Animal Internal
Medicine)

IMAGING BY

Loetitia Saint-Jacques,
LVT

HOSPITAL NAME

MountainView AH

REFERRING VET

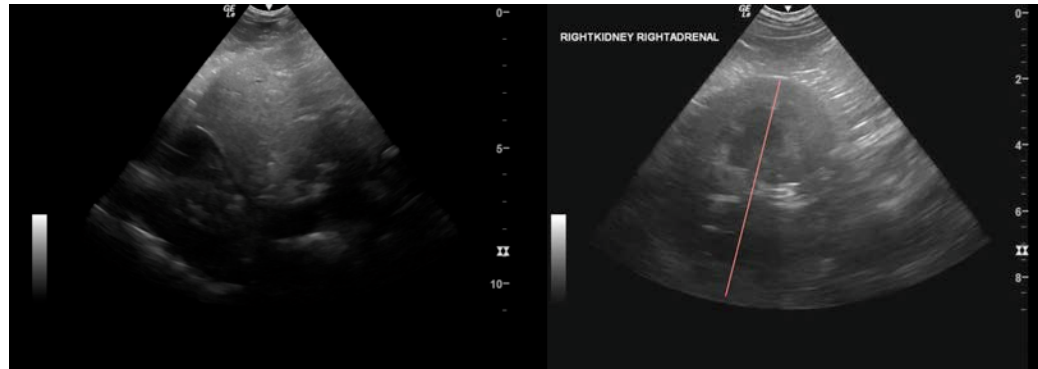
Dr. Kris Kingrey

INVOICE

39056

DATE

6/23/22



The information and recommendations provided are based on the images presented by the referring veterinarian/sonographer. No evaluation can be communicated regarding pathology that was not visible in the image/video clips provided.

Thank you for this referral. If the clinical or image interpretation does not parallel your findings or if I can be of any further assistance please contact me.

Kathleen Sennello DVM,MS, Diplomate ACVIM (Small animal Internal Medicine)
kathleen.sennello@sonopath.com