

**DATE PRESENTING CLINICAL SIGNS**

6/23/22 Liver values no change and worsening blood counts. Time to evaluate further.

**PATIENT**

Maxwell Hubrich

Labs: Chem: inc alb 4.0, inc alp 735, NOSF. CBC: low RBC 4.51, low HCT 33.8, low Hgb 10.4, low MCHC 30.8, low retic 24, low mono 0.112, low plt 121, on smear anisocytosis slight, platelets clumped but appear actually to be low and Ig platelets present, NOSF.

**SPECIES**

Canine

Current Medications: ursodiol 12mg/kg/d.  
Date of Previous IntraPet Ultrasound: No previous.  
Sedation: Not required to complete full diagnostic ultrasound.  
Stat Report: Not requested.

**BREED**

Australian Cattle Dog X

**ULTRASONOGRAPHIC EXAMINATION OF THE ABDOMEN****SEX**

Neutered Male

**Urinary System**

The urinary bladder is moderately distended with anechoic urine. The Bladder wall, trigone, ureteral papillae and visible urethra (to a depth of 2cm) appear normal with no evidence of wall thickening, mucosal irregularities, masses or cystic calculi.

**AGE**

4/22/16

The prostate is normal in size (1.08 cm) and shape for this neutered male dog. The parenchyma is homogenous and the external margins are smooth. The prostatic urethra appears normal with no evidence of irregularity, invasion, mass effect or calculi.

**WEIGHT**

41.8 Pounds

The left kidney has a normal shape and size (6.22 cm) with pinpoint non-obstructive nephroliths. Overall echogenicity is normal with adequate corticomedullary distinction and a typical 1:3 cortex:medulla ratio. There is no evidence of perinephric inflammation or effusion. There is no evidence of pyelectasia, nephroliths, infarcts or hydronephrosis. Renal vasculature is normal.

**INTERPRETED BY**

Kathleen Sennello DVM,  
MS, Diplomate ACVIM  
(Small Animal Internal  
Medicine)

The right kidney has a normal shape and size (6.51 cm) with pinpoint non-obstructive nephroliths. Overall echogenicity is normal with adequate corticomedullary distinction and a typical 1:3 cortex:medulla ratio. There is no evidence of perinephric inflammation or effusion. There is no evidence of pyelectasia, nephroliths, infarcts or hydronephrosis. Renal vasculature is normal.

**IMAGING PERFORMED BY**

Stephanie Pearce  
RDMS, RVT

**Adrenal Glands**

The left adrenal gland is normal in size measuring 0.55 cm at the caudal pole. It is observed in its normal position cranial to the left renal artery. It is normal in appearance (uniformly hypoechoic) and shape with no evidence of a mass effect.

**HOSPITAL NAME**

Happy Tails VH

The right adrenal gland is normal in size measuring 0.72 cm at the caudal pole. It is observed in its normal position between the cranial aspect of the right kidney and the caudal vena cava. It is normal in appearance (uniformly hypoechoic) and shape with no evidence of a mass effect.

**REFERRING VET**

Dr. Calpeno

**Spleen**

The spleen is large in size. It has slightly irregular shape and is folded back on itself at the tail. The spleen echotexture is heterogenous and mottled. The blood flow through the hilus and splenic parenchyma appears normal. No focal parenchymal abnormalities are visualized.

**INVOICE**

39021

**Liver**

The liver is large in size, and normal in echogenicity with smooth peripheral margins. The parenchyma is heterogenous in echotexture with subtle, indistinct focal mottling. The visible portions of the vasculature and biliary tract appear normal. No focal nodules or cystic lesions are observed.

The gall bladder lumen is moderately distended. The wall of the gall bladder is not thickened and has a smooth mucosal surface. There is a moderate amount of non-organized echogenic debris. The cystic and common bile ducts are normal/not visible.

### ***Gastrointestinal***

The stomach contains minimal luminal contents. It measures at a normal thickness of <0.7cm with some variability due to the presence of rugal folds. The distinction of the gastric wall layers is adequate and there is no impression of reduced peristaltic activity. No masses or focal lesions were observed.

The visualized areas of duodenum, jejunum and ileum have a relatively uniform diameter with minimal fluid distension. Wall thickness is normal. Bowel loops follow a curvilinear path with distinct wall layering maintaining the typical 1:3 muscularis:mucosa layer ratio. Jejunum wall measured 0.37 cm. Visualized peristalsis appears appropriate. There were no focal lesions consistent with obstruction or a mass effect observed.

The ileocecal junction was visualized and exhibited normal intact wall layering and is subjectively of normal thickness. Sections of colon are visualized with formed fecal material and gas shadowing distally. There is no observed focal or generalized colon wall thickening or loss of layering.

### ***Pancreas***

The pancreas is normal and isoechoic to surrounding mesentery. There is no evidence of nodules or cystic lesions. There is no evidence of regional mesenteric inflammation or fluid.

### ***Free Abdomen***

Evaluation of the peritoneal cavity did not reveal any evidence of effusion, or subjective lymphadenomegaly. The Medial iliac nodes appear normal and there was no evidence of a caudal aortic thrombus at the bifurcation. The omentum is of normal uniform echogenicity.

## **ULTRASONOGRAPHIC FINDINGS**

- Large, mottled spleen – The diffuse splenic changes are non-specific and could be consistent with lymphoid hyperplasia, extramedullary hematopoiesis, infiltrative neoplasia, inflammation, other. Cytology or histopathology would be necessary to get a definitive diagnosis.
- Large, heterogeneous liver – The diffuse hepatic changes are non-specific and could be consistent with vacuolar hepatopathy, nodular hyperplasia, inflammatory/immune-mediated disease, fibrosis, extramedullary hematopoiesis, toxic hepatopathy (e.g., copper), infiltrative neoplasia (less likely) or other hepatopathy.
- Moderate gallbladder debris – The significance of the aggregated gallbladder sludge is unclear. This could represent an early mucocele, cholestasis, or may be secondary to fasting.

## **INTERPRETATION OF THE FINDINGS & FURTHER RECOMMENDATIONS**

Today's scan has relatively subtle non-specific changes. The spleen appears prominent and folded back on itself (which is not a pathologic finding), but given the anemia present, a fine needle aspirate could be considered.

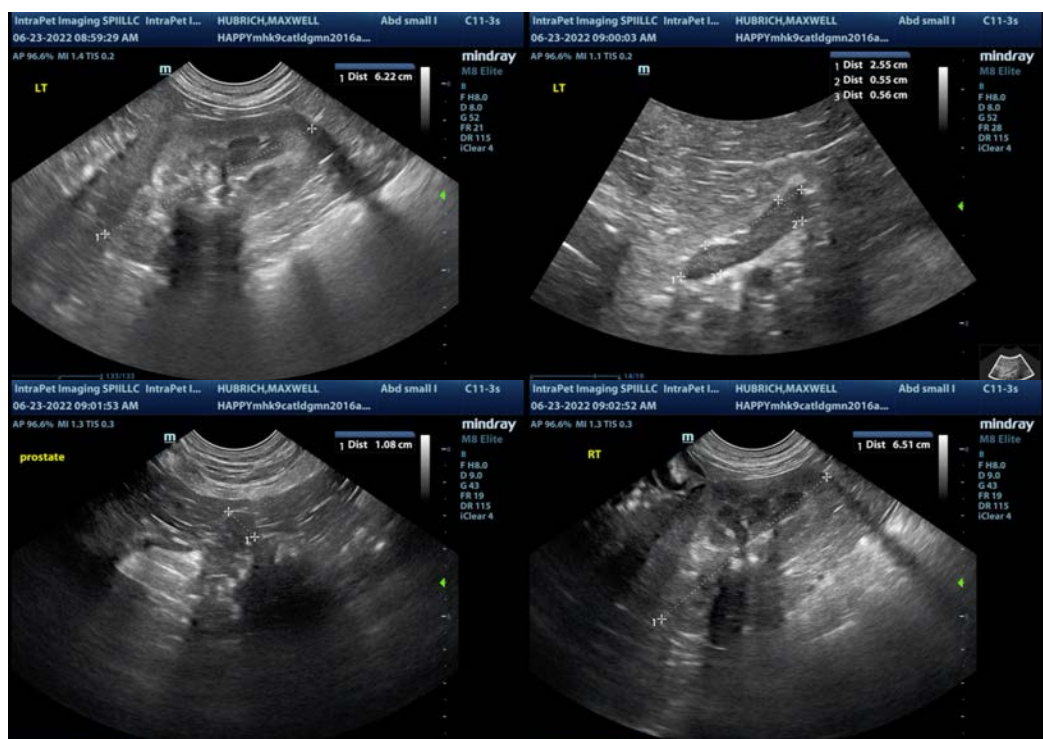
The liver is large and mildly heterogeneous. You could consider a liver function test and a fine needle aspirate of the liver. Consider a pathologist review of the blood smear to look for any atypical cells, blood parasites, etc. At this time, it is suspicious for an anemia chronic disease. Recommend 3-view thoracic radiographs.

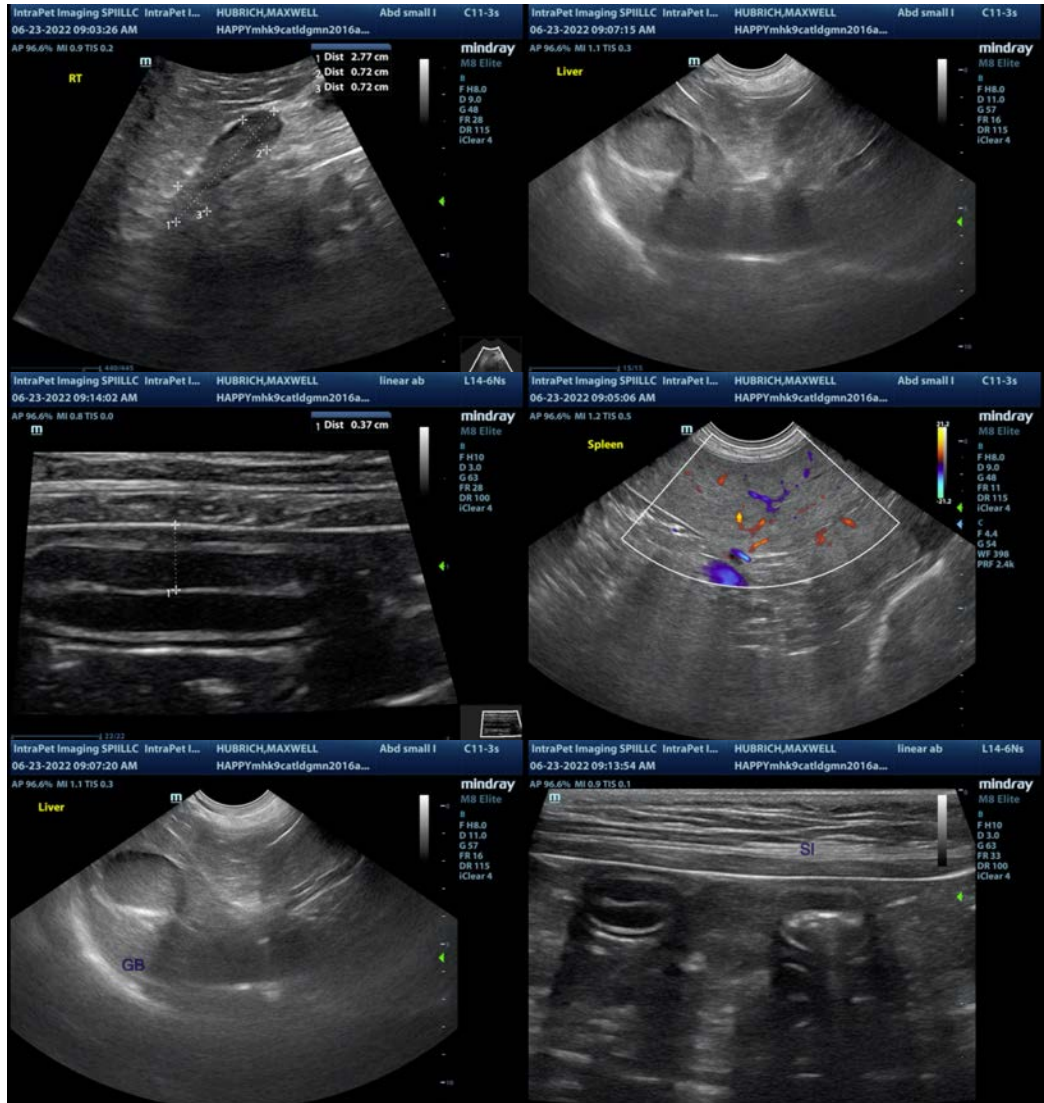
The changes observed in the gallbladder are mild, and continued monitoring is warranted.

The following are my recommendations for a primary elevation in ALP. I'm concerned that most of these pets are somewhat asymptomatic, so I'm not sure if this directly applies to Maxwell, but this could be a place to start.

- Induction phenomena are the most common cause for an elevation in ALP. These are systemic illnesses that 'turn on' the liver enzyme. Causes of this include Cushing's disease, dental disease, arthritis, and numerous others. In many cases the exact cause is unclear but as long as ultrasound and bile acids tests are normal most patients do not have progressive changes in their liver. While liver biopsy is not routinely performed, vacuolar hepatopathy, is noted on most biopsies. This is often non-progressive but in rare cases can be more severe and lead to liver failure.
- If signs of Cushing's disease are present recommend endocrine function testing to evaluate for Cushing's disease.
- Consider fine needle aspirate to rule out round cell neoplasia if this is a concern.
- If a cause for the ALP elevation is not identified: I recommend recheck general blood work every 6 months, ultrasound once per year, and bile acids test every 1-2 years based on other results. If the ALP continues to climb a biopsy could be considered.
- Consider long term use of denamarin, and monitoring for the signs of Cushing's developing.
- A primary vacuolar hepatopathy can be breed related and is seen in Scottish Terriers, Schnauzers, Cocker spaniels etc..

As stated above, I'm concerned that there may be more going on with Maxwell than a benign ALP elevation. Continued testing and monitoring is strongly recommended.





The information and recommendations provided are based on the images presented by the referring veterinarian/sonographer. No evaluation can be communicated regarding pathology that was not visible in the image/video clips provided.

Thank you for this referral. If the clinical or image interpretation does not parallel your findings or if I can be of any further assistance please contact me.

Kathleen Sennello DVM,MS, Diplomate ACVIM (Small animal Internal Medicine)  
 kathleen.sennello@sonopath.com