



PATIENT

Lucy Duncan

SPECIES

Canine

BREED

Labrador Retriever

SEX

Spayed Female

AGE

11 Years

WEIGHT

57 Pounds

INTERPRETED BY

Kathleen Sennello DVM,
MS, Diplomate ACVIM
(Small Animal Internal
Medicine)

**IMAGING
PERFORMED BY**

Kelly Vazquez

HOSPITAL NAME

Vet Wellness Center

REFERRING VET

Dr. Sepulveda

INVOICE

39033

DATE

6/23/22

PRESENTING CLINICAL SIGNS

Patient presents for chronic, vomiting, lethargy, decreased appetite, and progressive weight loss. Normal weight range 70-75 lbs, at last visit the patient weighed 59.3 lbs, today she weighs 57 lbs. Very prominent spine, thin appearance. Current meds: PPA 25mgs, Tramadol, Carprofen. Abnormal PE/Chem/CBC/UA Results: Bloods done April 2022 were WNL. No recent bloods.

ULTRASONOGRAPHIC EXAMINATION OF THE ABDOMEN

Urinary System

The urinary bladder is moderately distended with anechoic urine. The Bladder wall, trigone, ureteral papillae and visible urethra (to a depth of 2cm) appear normal with no evidence of wall thickening, mucosal irregularities, masses or cystic calculi.

The left kidney has a normal shape and size (5.16 cm). Overall echogenicity is normal with adequate corticomedullary distinction and a typical 1:3 cortex:medulla ratio. There is no evidence of perinephric inflammation or effusion. There is no evidence of pyelectasia, nephroliths, infarcts or hydroureter. Renal vasculature is normal.

The right kidney has a normal shape and size (6.04 cm). Overall echogenicity is normal with adequate corticomedullary distinction and a typical 1:3 cortex:medulla ratio. There is no evidence of perinephric inflammation or effusion. There is no evidence of pyelectasia, nephroliths, infarcts or hydroureter. Renal vasculature is normal.

Adrenal Glands

The left adrenal gland is large in size measuring 1.37 cm at the cranial pole, 0.67 cm at the caudal pole, and 1.37 cm in length. It is observed in its normal position cranial to the left renal artery. It is somewhat abnormal in appearance in that the cranial pole is enlarged and hyperechoic, creating the appearance of a hyperechoic nodule in the cranial pole measuring 1.3 cm x 1.12 cm. There is no evidence of obvious vascular invasion.

The right adrenal gland is normal in size measuring 0.63 cm at the caudal pole. It is observed in its normal position between the cranial aspect of the right kidney and the caudal vena cava. It is normal in appearance (uniformly hypoechoic) and shape with no evidence of a mass effect.

Spleen

The spleen is subjectively normal in size, echotexture is homogenous, and the splenic capsule is smooth with no irregularities. The blood flow through the hilus and splenic parenchyma appears normal. No focal parenchymal abnormalities are visualized.

Liver

The liver is subjectively normal in size, and echogenicity with smooth peripheral margins. The parenchyma is homogenous echotexture. The visible portions of the vasculature and biliary tract appear normal. No focal nodules or cystic lesions are observed.

The gallbladder lumen is moderately distended. The wall of the gall bladder is not thickened and has a smooth mucosal surface. Luminal contents are primarily anechoic. The cystic and common bile ducts are normal/not visible.



PATIENT

Lucy Duncan

SPECIES

Canine

BREED

Labrador Retriever

SEX

Spayed Female

AGE

11 Years

WEIGHT

57 Pounds

INTERPRETED BY

Kathleen Sennello DVM,
MS, Diplomate ACVIM
(Small Animal Internal
Medicine)

**IMAGING
PERFORMED BY**

Kelly Vazquez

HOSPITAL NAME

Vet Wellness Center

REFERRING VET

Dr. Sepulveda

INVOICE

39033

DATE

6/23/22

Gastrointestinal

The stomach contains minimal luminal contents. It measures at a normal thickness of <0.7cm with some variability due to the presence of rugal folds. The distinction of the gastric wall layers is adequate and there is no impression of reduced peristaltic activity. No masses or focal lesions were observed.

Much of the small intestine appears mildly fluid dilated. There is a focal region of small intestine with a severely thickened wall and complete loss of layering. In this area, the bowel has a diameter of 2.46 cm and wall thickness of 1.59 cm. Orad to this lesion, there is shadowing, most consistent with an obstruction due to the bowel mass. This lesion creates the effect of a mass lesion approximately 2.52 cm x 3.37 cm. There are areas of small bowel proximal to this lesion with thickened wall and reduced layering. More normal areas of small intestine are visible distally with a lack of fluid distention, normal wall layering and thickness.

The ileocecal junction was visualized and exhibited normal intact wall layering and is subjectively of normal thickness. Sections of colon are visualized with formed fecal material and gas shadowing distally. There is no observed focal or generalized colon wall thickening or loss of layering.

Pancreas

The pancreas is normal and isoechoic to surrounding mesentery. There is no evidence of nodules or cystic lesions. There is no evidence of regional mesenteric inflammation or fluid.

Free Abdomen

Evaluation of the peritoneal cavity did not reveal any evidence of effusion, or subjective lymphadenomegaly. The Medial iliac nodes appear normal and there was no evidence of a caudal aortic thrombus at the bifurcation. The omentum is of increased echogenicity around the abnormal bowel.

ULTRASONOGRAPHIC FINDINGS

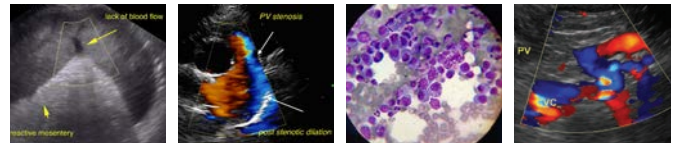
- Hyperechoic nodule in the cranial pole of the left adrenal gland – Left/right adrenomegaly could be consistent with neoplasia (e.g., adenoma, carcinoma, pheochromocytoma), hyperplasia, inflammation, other.
- Mass effect with severely thickened wall and loss of layering in the small intestine – This lesion is most concerning for a primary bowel mass with a suspected secondary obstruction.

INTERPRETATION OF THE FINDINGS & FURTHER RECOMMENDATIONS

The symptoms described today are most likely associated with the bowel lesion visualized. This area of small intestine appears to have a complete loss of layering and bowel dilation with an accumulation of shadowing material orad to the lesion, most consistent with an obstruction. The bowel is abnormal and significantly obscured by inflammatory changes, so I cannot definitively rule out that this is not a colonic lesion, but I strongly suspect that it is small intestinal.

Additionally, there is a lesion in the cranial pole of the left adrenal gland. This lesion is relatively small. There is no overt evidence of vascular invasion. This could be a benign or malignant lesion and could secrete hormone or be non-active. Options moving forward include:

- If signs of cushings are present, consider adrenal function testing. I prefer an ACTH stimulation test combined with an adrenal panel to the University of Tennessee's endocrine lab to look for atypical adrenal hormones as well as cortisol. (other testing can suffice)
- If adrenal dependent cushings is suspected and supported by adrenal function testing consider medical therapy with lysodren or trilostane or consider surgical removal (recommend referral



PATIENT

to a board certified veterinary surgeon and possible pre op CT)

Lucy Duncan

SPECIES

Canine

- Recommend blood pressure evaluation-if hypertensive consider testing catecholamine levels for a possible pheochromocytoma

BREED

Labrador Retriever

- If no symptoms of cushings are present, consider either referral for surgery or continued monitoring with ultrasound (in 3-4 months).

SEX

Spayed Female

- Many of these nodules can be benign and incidental in nature, unfortunately that is difficult to determine with a single ultrasound.

AGE

11 Years

Options moving forward include either exploratory surgery for both diagnostic and therapeutic purposes with the intent to likely resect abnormal bowel and submit histopathology, as well as to look for other areas of abnormal bowel or any obvious metastatic lesions, abnormal lymph nodes, etc. (recommend referral to a veterinary surgeon, as the definitive location of this bowel mass is not verified) as long as thoracic radiographs are normal. If surgical intervention is not desired, you could consider a fine needle aspirate of the bowel mass, but based on the appearance of this lesion, there is concern for a possible obstruction.

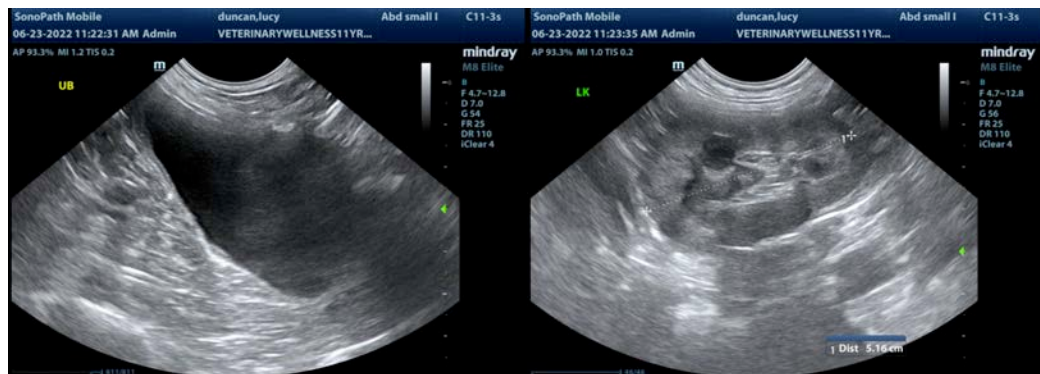
WEIGHT

57 Pounds

Keep in mind that the significance of the adrenal lesion is unknown, and as long as the blood pressure is normal, this could likely be further evaluated down the road after the bowel lesion is handled. I suspect this is an incidental finding on today's scan.

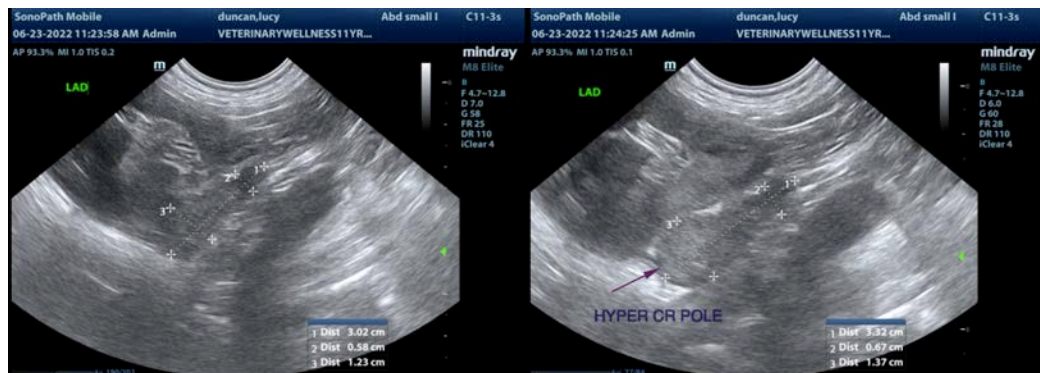
INTERPRETED BY

Kathleen Sennello DVM, MS, Diplomate ACVIM (Small Animal Internal Medicine)



IMAGING PERFORMED BY

Kelly Vazquez



HOSPITAL NAME

Vet Wellness Center

REFERRING VET

Dr. Sepulveda

INVOICE

39033

DATE

6/23/22



PATIENT

Lucy Duncan

SPECIES

Canine

BREED

Labrador Retriever

SEX

Spayed Female

AGE

11 Years

WEIGHT

57 Pounds

INTERPRETED BY

Kathleen Sennello DVM,
MS, Diplomate ACVIM
(Small Animal Internal
Medicine)

**IMAGING
PERFORMED BY**

Kelly Vazquez

HOSPITAL NAME

Vet Wellness Center

REFERRING VET

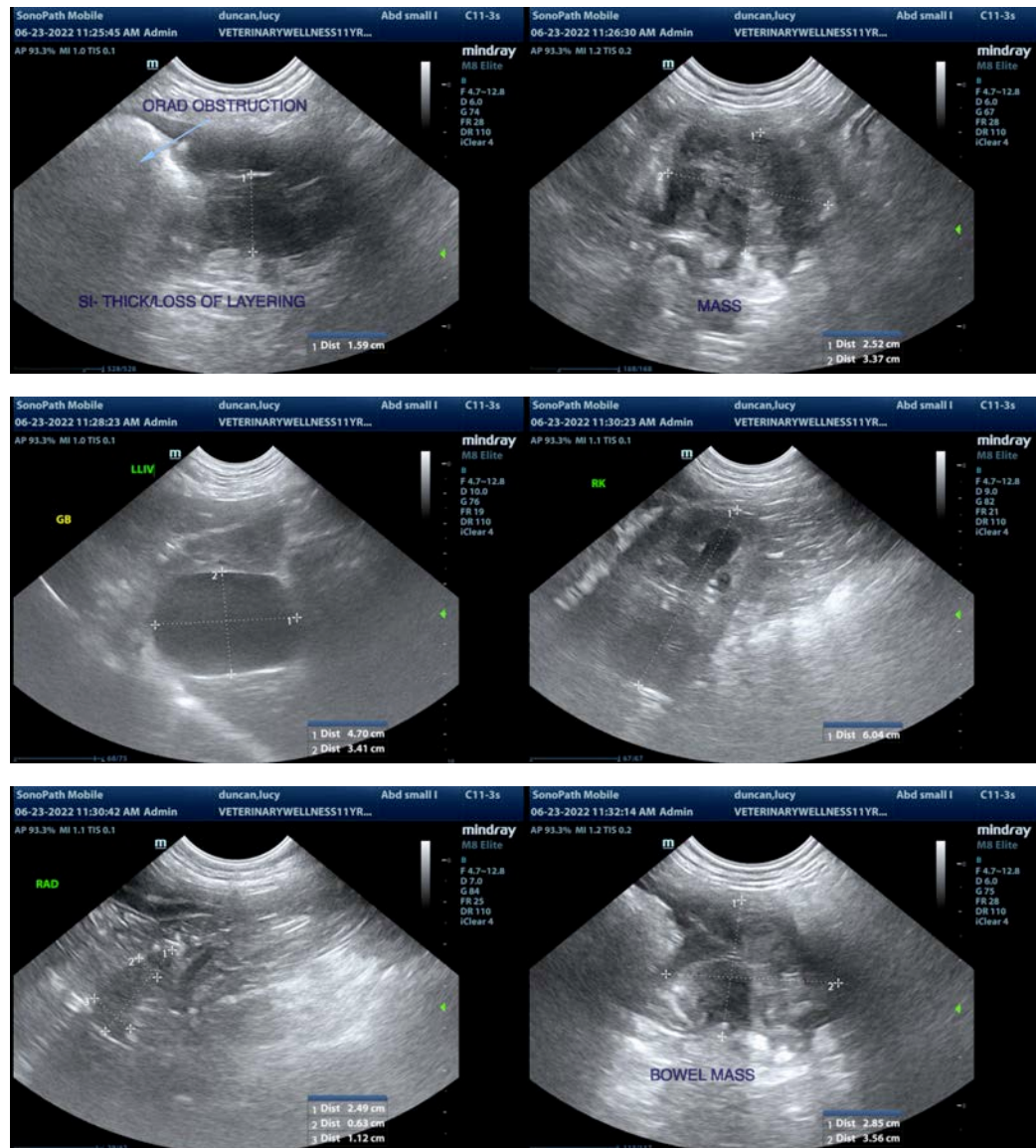
Dr. Sepulveda

INVOICE

39033

DATE

6/23/22



The information and recommendations provided are based on the images presented by the referring veterinarian/sonographer. No evaluation can be communicated regarding pathology that was not visible in the image/video clips provided.

Thank you for this referral. If the clinical or image interpretation does not parallel your findings or if I can be of any further assistance please contact me.

Kathleen Sennello DVM,MS, Diplomate ACVIM (Small animal Internal Medicine)

kathleen.sennello@sonopath.com