



PATIENT

Butterball Powell

SPECIES

Canine

BREED

Labrador Retriever

SEX

Spayed Female

AGE

12 Years

WEIGHT

78.8 Pounds

INTERPRETED BY

Kathleen Sennello DVM,
MS, Diplomate ACVIM
(Small Animal Internal
Medicine)

**IMAGING
PERFORMED BY**

Jessica Bailes

HOSPITAL NAME

All Creatures Great &
Small Corvallis

REFERRING VET

Dr. Chantal Litalien

INVOICE

39034

DATE

6/23/22

PRESENTING CLINICAL SIGNS

hx of chronic diarrhea and progressive weight loss despite overall unremarkable exam and blood work. Scheduled for a dental cleaning in 2 weeks- want to R/O obvious neoplasia.

Abnormal PE/Chem/CBC/UA Results: Dental disease, multiple SQ lipoma - like masses, otherwise NSF on PE Bloodwork NSF No hx of urinary concerns or urinalysis being performed.

ULTRASONOGRAPHIC EXAMINATION OF THE ABDOMEN

Urinary System

The urinary bladder is moderately distended with echogenic urine. There is a focal abnormality in the dorsal apical aspect of the urinary bladder with a polypoid mass lesion that appears calcified. This area measures approximately 2.3 cm x 1.8 cm, and the bladder wall is thickened. The area of the trigone, ureteral papillae and visible urethra (to a depth of 2cm) appear free of any significant lesions or calculi.

The left kidney has a normal shape and size (6.94 cm). Overall echogenicity is normal with adequate corticomedullary distinction and a typical 1:3 cortex:medulla ratio. There is no evidence of perinephric inflammation or effusion. There is no evidence of pyelectasia, nephroliths, infarcts or hydroureter. Renal vasculature is normal.

The right kidney has a normal shape and size (5.95 cm). Overall echogenicity is normal with adequate corticomedullary distinction and a typical 1:3 cortex:medulla ratio. There is no evidence of perinephric inflammation or effusion. There is no evidence of pyelectasia, nephroliths, infarcts or hydroureter. Renal vasculature is normal.

Adrenal Glands

The left adrenal gland is normal in size measuring 0.65 cm at the caudal pole. It is observed in its normal position cranial to the left renal artery. It is normal in appearance (uniformly hypoechoic) and shape with no evidence of a mass effect.

The right adrenal gland is normal in size measuring 0.77 cm at the caudal pole. It is observed in its normal position between the cranial aspect of the right kidney and the caudal vena cava. It is normal in appearance (uniformly hypoechoic) and shape with no evidence of a mass effect.

Spleen

The spleen is subjectively normal in size and the echotexture is homogenous. The splenic capsule is smooth with no visible irregularities. Rare discrete focal hyperechoic, perivascular parenchymal abnormalities are present. The appearance of these lesions is most consistent with benign splenic myelolipomas. The blood flow through the hilus and splenic parenchyma appears normal.

Liver

The liver is subjectively normal in size, and echogenicity with smooth peripheral margins. The parenchyma is homogenous echotexture. The visible portions of the vasculature and biliary tract appear normal. No focal nodules or cystic lesions are observed.

The gallbladder lumen is moderately distended. The wall of the gall bladder is not thickened and has a smooth mucosal surface. Luminal contents are primarily anechoic. The cystic and common bile ducts are normal/not visible.



PATIENT

Butterball Powell

SPECIES

Canine

BREED

Labrador Retriever

SEX

Spayed Female

AGE

12 Years

WEIGHT

78.8 Pounds

INTERPRETED BY

Kathleen Sennello DVM,
MS, Diplomate ACVIM
(Small Animal Internal
Medicine)

**IMAGING
PERFORMED BY**

Jessica Bailes

HOSPITAL NAME

All Creatures Great &
Small Corvallis

REFERRING VET

Dr. Chantal Litalien

INVOICE

39034

DATE

6/23/22

Gastrointestinal

The stomach contains minimal luminal contents. It measures at a normal thickness of <0.7cm with some variability due to the presence of rugal folds. The distinction of the gastric wall layers is adequate and there is no impression of reduced peristaltic activity. No masses or focal lesions were observed.

The visualized areas of duodenum, jejunum and ileum have a relatively uniform diameter with minimal fluid distension. Wall thickness is normal. Bowel loops follow a curvilinear path with distinct wall layering maintaining the typical 1:3 muscularis:mucosa layer ratio. Jejunum wall measured 0.29 cm. Visualized peristalsis appears appropriate. There were no focal lesions consistent with obstruction or a mass effect observed.

The ileocecal junction was visualized and exhibited normal intact wall layering and is subjectively of normal thickness. Sections of colon are visualized with formed fecal material and gas shadowing distally. There is no observed focal or generalized colon wall thickening or loss of layering.

Pancreas

The pancreas is normal and isoechoic to surrounding mesentery. There is no evidence of nodules or cystic lesions. There is no evidence of regional mesenteric inflammation or fluid.

Free Abdomen

Evaluation of the peritoneal cavity did not reveal any evidence of effusion, or subjective lymphadenomegaly. The Medial iliac nodes appear normal and there was no evidence of a caudal aortic thrombus at the bifurcation. The omentum is of normal uniform echogenicity.

ULTRASONOGRAPHIC FINDINGS

- Focal mineralized irregularity of the urinary bladder wall – most consistent with a TCC, but a mineralized polyp or other possibilities exist.
- Numerous hyperechoic nodules within the splenic parenchyma – most consistent with benign myelolipomas, but an underlying neoplastic process cannot be excluded as a possibility. Consider a fine needle aspirate.

INTERPRETATION OF THE FINDINGS & FURTHER RECOMMENDATIONS

There is a large mineralized irregular mass lesion in the apical portion of the urinary bladder wall. The appearance of this lesion is concerning for a transitional cell carcinoma, but polyps and inflammatory lesions can sometimes have a similar appearance. A definitive diagnosis cannot be determined by ultrasound alone.

-Recommend urine evaluation for BRAF mutation seen in patients with transitional cell carcinomas. A positive test is diagnostic, a negative test is inconclusive and will need further diagnostics.

-If negative or non-diagnostic BRAF consider traumatic catheterization to obtain representative cells for cytology, or biopsy sampling via either cystoscopy (if a female) or surgery.

-Patients with bladder pathology should always have urinalysis and culture performed. Ideally cystocentesis should be avoided in patients with suspected bladder masses to try and prevent tracking of tumor cells along the needle path.

-If TCC is confirmed consider referral to/consultation with a board certified. Veterinary oncologist for recommendations regarding treatment options and prognosis.



PATIENT

Butterball Powell

If treatment would be considered in this pet, a cystoscopic evaluation may be beneficial to determine if there are surgical options or if there are additional small lesions present more diffusely, which would reduce the likely success of a surgical procedure. Biopsies could be obtained at the time of cystoscopy.

SPECIES

Canine

It is somewhat unusual for a bladder mass to cause systemic illness, weight loss, or diarrhea, so unfortunately this could be an incidental finding. No focal lesions were observed involving the GI tract.

BREED

Labrador Retriever

- Consider a novel protein/hydrolyzed protein prescription diet.
- Consider chronic probiotic therapy.
- Consider a GI panel to Texas A&M for a qualitative PLI, TLI, cobalamin and folate to further evaluate the pancreas and small intestine.
- If diarrhea persists, you could consider obtaining GI biopsies.

SEX

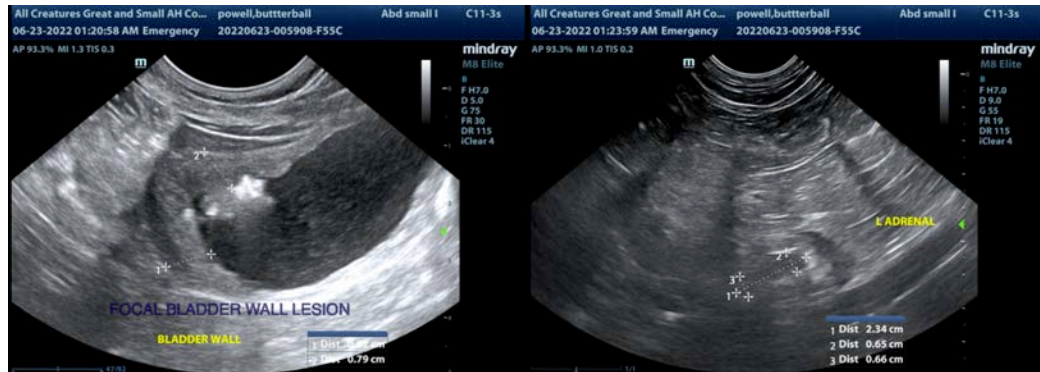
Spayed Female

AGE

12 Years

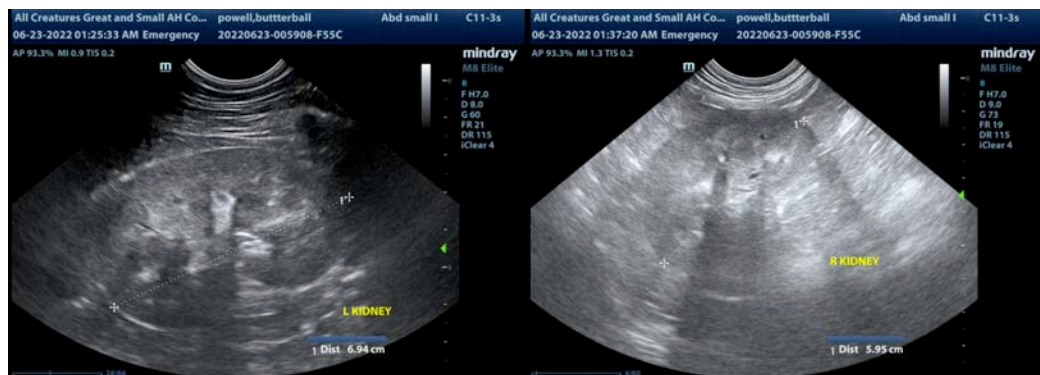
WEIGHT

78.8 Pounds



INTERPRETED BY

Kathleen Sennello DVM, MS, Diplomate ACVIM (Small Animal Internal Medicine)

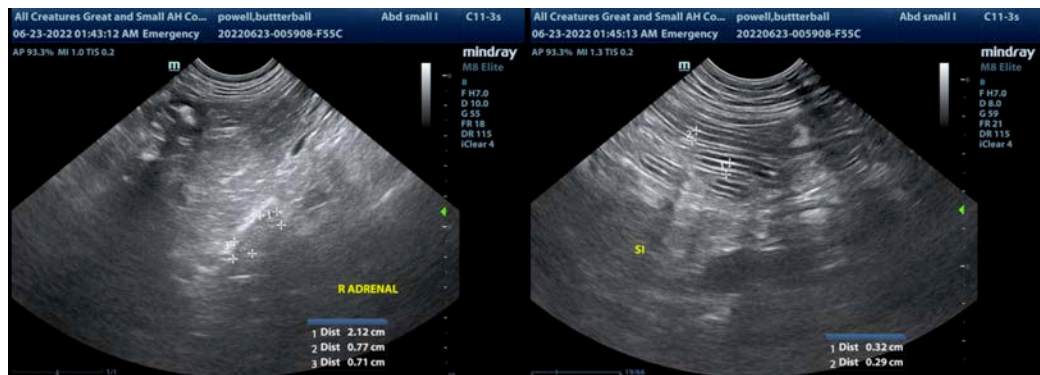


IMAGING PERFORMED BY

Jessica Bailes

HOSPITAL NAME

All Creatures Great & Small Corvallis



REFERRING VET

Dr. Chantal Litalien

INVOICE

39034

DATE

6/23/22



PATIENT

Butterball Powell

SPECIES

Canine

BREED

Labrador Retriever

SEX

Spayed Female

AGE

12 Years

WEIGHT

78.8 Pounds

INTERPRETED BY

Kathleen Sennello DVM,
MS, Diplomate ACVIM
(Small Animal Internal
Medicine)

**IMAGING
PERFORMED BY**

Jessica Bailes

HOSPITAL NAME

All Creatures Great &
Small Corvallis

REFERRING VET

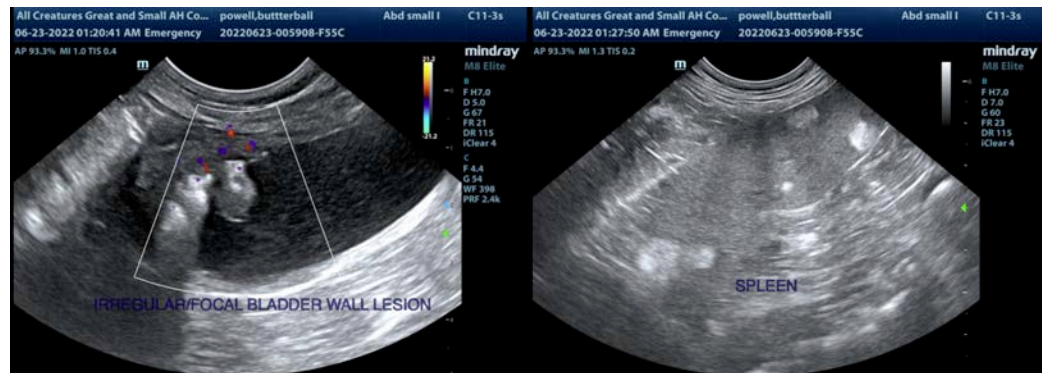
Dr. Chantal Litalien

INVOICE

39034

DATE

6/23/22



The information and recommendations provided are based on the images presented by the referring veterinarian/sonographer. No evaluation can be communicated regarding pathology that was not visible in the image/video clips provided.

Thank you for this referral. If the clinical or image interpretation does not parallel your findings or if I can be of any further assistance please contact me.

Kathleen Sennello DVM,MS, Diplomate ACVIM (Small animal Internal Medicine)

kathleen.sennello@sonopath.com