



PATIENT PRESENTING CLINICAL SIGNS

PATIENT Rambo Heald Pet has had a progressively elevated ALP for past few years. ALP is 655. Pet is asymptomatic. Pet has seizures. Pet takes Keppra and Denamarin.

SPECIES ULTRASONOGRAPHIC EXAMINATION OF THE ABDOMEN

SPECIES Canine

BREED

Labradoodle

SEX

Neutered Male

AGE

4 Years

WEIGHT

87.6

INTERPRETED BY

Kathleen Sennello DVM,
MS, Diplomate ACVIM
(Small Animal Internal
Medicine)

IMAGING PERFORMED BY

Dr. Sheldon

HOSPITAL NAME

Advacned PetCare
of Oakland

REFERRING VET

Dr. Sheldon

INVOICE

43385

DATE

6/22/23

Urinary System

The urinary bladder is moderately distended with anechoic urine. The Bladder wall, trigone, ureteral papillae and visible urethra (to a depth of 2cm) appear normal with no evidence of wall thickening, mucosal irregularities, masses or cystic calculi.

The visualized areas of prostate and surrounding tissue appear normal. Unfortunately, the prostate is not fully visualized likely due to its intrapelvic location. Correlate with rectal exam findings.

The left kidney has a normal shape and size (7.17 cm). Overall echogenicity is normal with adequate corticomedullary distinction and a typical 1:3 cortex:medulla ratio. There is no evidence of focal perinephric inflammation or effusion. There is no evidence of pyelectasia, nephroliths, infarcts or hydroureter. Renal vasculature is normal.

The right kidney has a normal shape and size (7.39 cm). Overall echogenicity is normal with adequate corticomedullary distinction and a typical 1:3 cortex:medulla ratio. There is no evidence of focal perinephric inflammation or effusion. There is no evidence of pyelectasia, nephroliths, infarcts or hydroureter. Renal vasculature is normal.

Adrenal Glands

The left adrenal gland is normal in size measuring 0.79 cm at the caudal pole. It is observed in its normal position cranial to the left renal artery. It is normal in appearance (uniformly hypoechoic) and shape with no evidence of a mass effect.

The region of the right adrenal (between right cranial kidney and vena cava) is unremarkable, but the adrenal is not distinctly visualized. No evidence of a mass effect is visualized.

Spleen

The spleen is subjectively normal in size, echotexture is homogenous, and the splenic capsule is smooth with no irregularities. The blood flow through the hilus and splenic parenchyma appears normal. No focal parenchymal abnormalities are visualized.

Liver

The liver is subjectively normal in size, and echogenicity with smooth peripheral margins. The parenchyma is heterogenous in echotexture with subtle, indistinct focal mottling. The visible portions of the vasculature and biliary tract appear normal. No focal nodules or cystic lesions are observed.

The gallbladder lumen is moderately distended. The wall of the gall bladder is not thickened and has a smooth mucosal surface. Luminal contents are mild and primarily anechoic. The cystic and common bile ducts are normal/not visible.

Gastrointestinal

The stomach contains minimal luminal contents. It measures at a normal thickness of <0.7cm with some variability due to the presence of rugal folds. The distinction of the gastric wall layers is adequate and there is no impression of reduced peristaltic activity. No masses or focal lesions were observed.



PATIENT

Rambo Heald

SPECIES

Canine

BREED

Labradoodle

SEX

Neutered Male

AGE

4 Years

WEIGHT

87.6

INTERPRETED BY

Kathleen Sennello DVM,
MS, Diplomate ACVIM
(Small Animal Internal
Medicine)

**IMAGING
PERFORMED BY**

Dr. Sheldon

HOSPITAL NAME

Advacned PetCare
of Oakland

REFERRING VET

Dr. Sheldon

INVOICE

43385

DATE

6/22/23

The visualized areas of duodenum, jejunum and ileum have a relatively uniform diameter with minimal fluid distension. Wall thickness is normal. Bowel loops follow a curvilinear path with distinct wall layering maintaining the typical 1:3 muscularis:mucosa layer ratio. Duodenum wall measures 0.53 cm. Jejunum wall measures 0.27 cm. Visualized peristalsis appears appropriate. There were no focal lesions consistent with obstruction or a mass effect observed.

The ileocecal junction was visualized and exhibited normal intact wall layering and is subjectively of normal thickness. Sections of colon are visualized with formed fecal material and gas shadowing distally. There is no observed focal or generalized colon wall thickening or loss of layering.

Pancreas

The pancreas is normal and isoechoic to surrounding mesentery. There is no evidence of nodules or cystic lesions. There is no evidence of regional mesenteric inflammation or fluid.

Free Abdomen

Evaluation of the peritoneal cavity did not reveal any evidence of effusion, or subjective lymphadenomegaly. The Medial iliac nodes appear normal and there was no evidence of a caudal aortic thrombus at the bifurcation. The omentum is of normal uniform echogenicity.

ULTRASONOGRAPHIC FINDINGS

- Heterogeneous liver – The diffuse hepatic changes are non-specific and could be consistent with vacuolar hepatopathy, nodular hyperplasia, inflammatory/immune-mediated disease, fibrosis, extramedullary hematopoiesis, toxic hepatopathy (e.g., copper), infiltrative neoplasia (less likely) or other hepatopathy.

INTERPRETATION OF THE FINDINGS & FURTHER RECOMMENDATIONS

No focal lesions are visualized associated with the liver to explain the elevation in ALP reported. Additionally, the gallbladder appears relatively normal. Unfortunately, there are many causes for an elevation in ALP which cannot be diagnosed by ultrasound alone. Consider the following:

- Induction phenomena are the most common cause for an elevation in ALP. These are systemic illnesses that 'turn on' the liver enzyme. Causes of this include Cushing's disease, dental disease, arthritis, and numerous others. In many cases the exact cause is unclear but as long as ultrasound and bile acids tests are normal most patients do not have progressive changes in their liver. While liver biopsy is not routinely performed, vacuolar hepatopathy, is noted on most biopsies. This is often non-progressive but in rare cases can be more severe and lead to liver failure.
- If signs of cushings disease are present recommend endocrine function testing to evaluate for cushings disease.
- Consider fine needle aspirate to rule out round cell neoplasia -if this is a concern.
- If a cause for the ALP elevation is not identified: I recommend recheck general blood work every 6 months, ultrasound once per year, and bile acids test every 1-2 years based on other results. If the ALP continues to climb a biopsy could be considered.
- Consider long term use of denamarin, and monitoring for the signs of cushings developing.



PATIENT

- A primary vacuolar hepatopathy can be breed related and is seen in Scottish Terriers, Schnauzers, Cocker spaniels etc..

Rambo Heald

SPECIES

Canine

BREED

Labradoodle

SEX

Neutered Male

AGE

4 Years

WEIGHT

87.6

INTERPRETED BY

Kathleen Sennello DVM,
MS, Diplomate ACVIM
(Small Animal Internal
Medicine)

**IMAGING
PERFORMED BY**

Dr. Sheldon

HOSPITAL NAME

Advacned PetCare
of Oakland

REFERRING VET

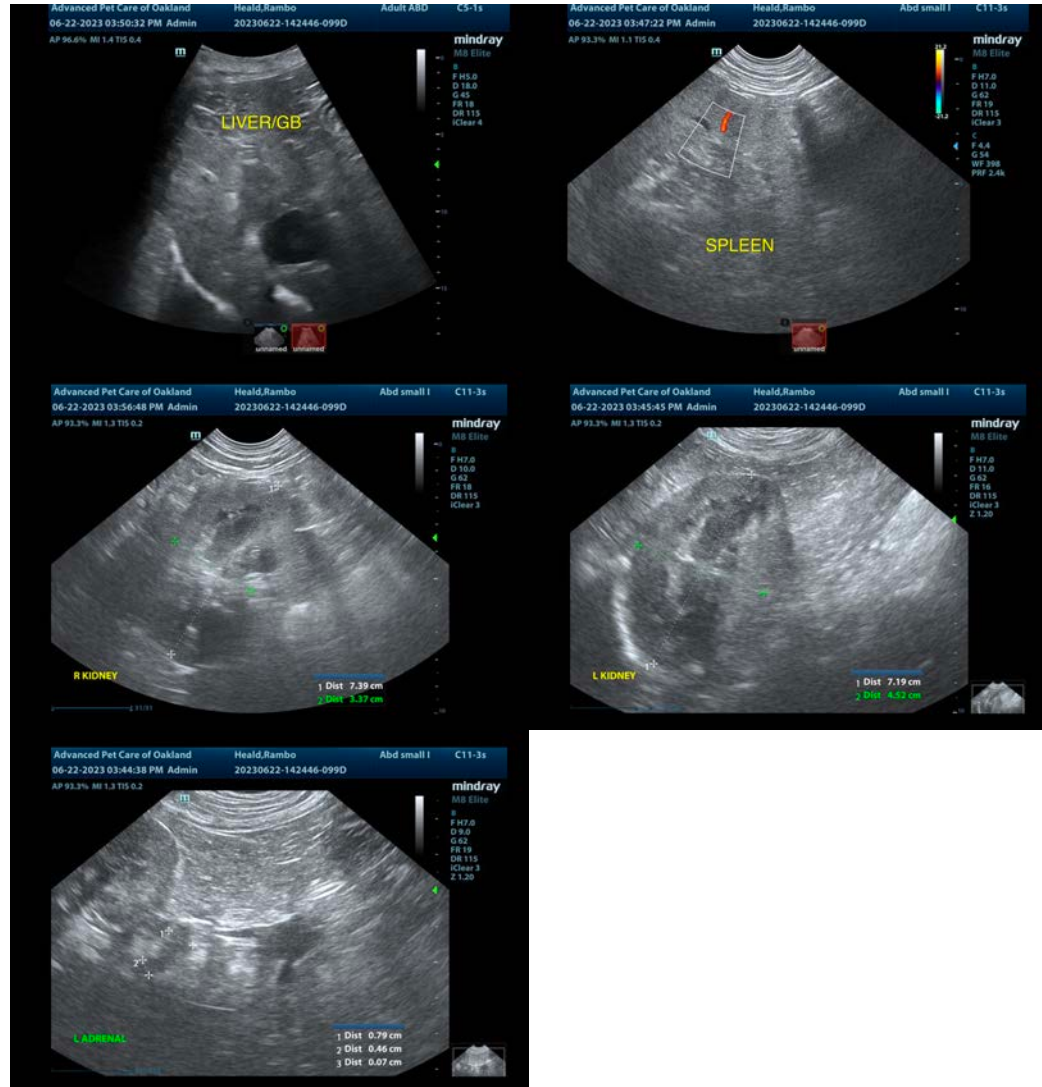
Dr. Sheldon

INVOICE

43385

DATE

6/22/23



The information and recommendations provided are based on the images presented by the referring veterinarian/sonographer. No evaluation can be communicated regarding pathology that was not visible in the image/video clips provided.

Thank you for this referral. If the clinical or image interpretation does not parallel your findings or if I can be of any further assistance please contact me.

Kathleen Sennello DVM,MS, Diplomate ACVIM (Small animal Internal Medicine)

info@sonopath.com