



PATIENT PRESENTING CLINICAL SIGNS

Flora Browniee
SPECIES
Canine
Chronic diarrhea. hx of chronic food sensitivities which had until recently been managed w/ homecooked diet. pet has chronic allergies (suspect combination of food and atopy) chronic proteinuria (stable) rx: benazepril 5mg BID chronic joint pain rx: adequan monthly inj, galliprant diarrhea resolved w/ short course of metronidazole, fortiflora; recurs w/ stopping of medications

BREED
Abnormal PE/Chem/CBC/UA Results: most recent BW shows ALT: 133, BUN 29 UPC 2.6 BP normotensive

West Highland White Terrier
ULTRASONOGRAPHIC EXAMINATION OF THE ABDOMEN

SEX
Urinary System

Spayed Female
AGE
The urinary bladder is moderately distended with anechoic urine. The Bladder wall, trigone, ureteral papillae and visible urethra (to a depth of 2cm) appear normal with no evidence of wall thickening, mucosal irregularities, masses or cystic calculi.

13 Years
WEIGHT
The left kidney has a normal shape and size (4.81 cm) with numerous small cortical cysts. Overall echogenicity is slightly hyperechoic with poor corticomedullary distinction and a typical 1:3 cortex:medulla ratio. There is no evidence of focal perinephric inflammation or effusion. There is no evidence of pyelectasia, nephroliths, infarcts or hydroureter. Renal vasculature is normal.

27 Pounds
INTERPRETED BY
The right kidney has a normal shape and size (4.93 cm) with numerous small cortical cysts. Overall echogenicity is slightly hyperechoic with poor corticomedullary distinction and a typical 1:3 cortex:medulla ratio. There is no evidence of focal perinephric inflammation or effusion. There is no evidence of pyelectasia, nephroliths, infarcts or hydroureter. Renal vasculature is normal.

Kathleen Sennello DVM,
MS, Diplomate ACVIM
(Small Animal Internal
Medicine)

IMAGING PERFORMED BY
Adrenal Glands

The left adrenal gland is normal in size measuring 0.42 cm at the caudal pole. It is observed in its normal position cranial to the left renal artery. It is normal in appearance (uniformly hypoechoic) and shape with no evidence of a mass effect.

Loetitia Saint-Jacques,
LVT

The right adrenal gland is normal in size measuring 0.38 cm at the caudal pole. It is observed in its normal position between the cranial aspect of the right kidney and the caudal vena cava. It is normal in appearance (uniformly hypoechoic) and shape with no evidence of a mass effect.

HOSPITAL NAME

MountainView AH

Spleen

The spleen is subjectively normal in size, echotexture is homogenous, and the splenic capsule is smooth with no irregularities. The blood flow through the hilus and splenic parenchyma appears normal. There are numerous small hypoechoic/cystic regions visualized in the parenchyma, most consistent with moth eaten diffuse lesions. Examples of these moth eaten areas measure approximately 0.39 cm and 0.49 cm in diameter.

REFERRING VET

Dr. Hill

INVOICE

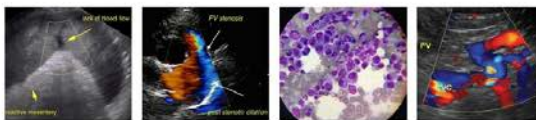
43407

Liver

The liver is large in size, and normal in echogenicity with smooth peripheral margins. The parenchyma is heterogenous in echotexture with subtle, indistinct focal mottling. The visible portions of the vasculature and biliary tract appear normal. No focal nodules or cystic lesions are observed.

DATE

6/22/23


PATIENT

Flora Browniee

The gall bladder lumen is moderately distended. The wall of the gall bladder is not thickened and has a smooth mucosal surface. There is a moderate amount of non-organized echogenic debris. The cystic and common bile ducts are normal/not visible.

SPECIES

Canine

Gastrointestinal

The stomach contains minimal luminal contents. It measures at a normal thickness of <0.7cm with some variability due to the presence of rugal folds. The distinction of the gastric wall layers is adequate and there is no impression of reduced peristaltic activity. No masses or focal lesions were observed.

BREED

West Highland White Terrier

The visualized areas of duodenum, jejunum and ileum have a uniform diameter with minimal fluid distension. Wall thickness is increased. Bowel loops follow a typical curvilinear path. Some areas have reduced detail of wall layering. Duodenum wall measures 0.51 cm. Jejunum wall measures 0.42 cm.

SEX

Spayed Female

Visualized peristalsis appears appropriate. There were no focal lesions consistent with obstruction or a mass effect observed.

AGE

13 Years

The ileocecal junction was visualized and exhibited normal intact wall layering and is subjectively of normal thickness. Sections of colon are visualized with formed fecal material and gas shadowing distally. The descending colon appears slightly prominent with a mildly thickened wall measuring 0.38 cm with intact wall layering.

WEIGHT

27 Pounds

Pancreas

The pancreas is prominent, hyperechoic and mottled compared to the surrounding isoechoic mesentery. Significant mottling involved with the parenchyma in some areas appears almost nodular with hypoechoic regions measuring 0.52 cm and 0.68 cm in the region of the right limb of the pancreas. There is no evidence of regional mesenteric inflammation or fluid.

INTERPRETED BY

 Kathleen Sennello DVM,
 MS, Diplomate ACVIM
 (Small Animal Internal
 Medicine)

Free Abdomen

Evaluation of the peritoneal cavity did not reveal any evidence of effusion, or subjective lymphadenomegaly. The Medial iliac nodes appear normal and there was no evidence of a caudal aortic thrombus at the bifurcation. The omentum is of normal uniform echogenicity.

IMAGING PERFORMED BY

 Loetitia Saint-Jacques,
 LVT

PRIMARY FINDINGS

- Subtle moth-eaten appearance to the spleen with numerous small cystic areas – The significance of these lesions is unclear. Recommend continued monitoring. These could represent benign cystic lesions or an early neoplastic lesion.
- Hyperechoic, prominent/nodular right limb of the pancreas – These changes could be consistent with pancreatic remodeling, nodular hyperplasia, or less likely pancreatic neoplasia.
- Large, heterogeneous liver – The diffuse hepatic changes are non-specific and could be consistent with vacuolar hepatopathy, nodular hyperplasia, inflammatory/immune-mediated disease, fibrosis, extramedullary hematopoiesis, toxic hepatopathy (e.g., copper), infiltrative neoplasia (less likely) or other hepatopathy.
- Moderate gallbladder debris – The significance of the aggregated gallbladder debris is unclear. This could represent an early mucocele, cholestasis, or may be secondary to fasting but seems unlikely to be causing a current issue. Recommend continued monitoring.

HOSPITAL NAME

MountainView AH

REFERRING VET

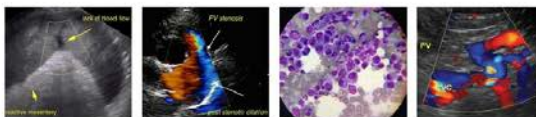
Dr. Hill

INVOICE

43407

DATE

6/22/23



PATIENT

Flora Browniee

SPECIES

Canine

BREED

West Highland White
Terrier

SEX

Spayed Female

AGE

13 Years

WEIGHT

27 Pounds

INTERPRETED BY

Kathleen Sennello DVM,
MS, Diplomate ACVIM
(Small Animal Internal
Medicine)

**IMAGING
PERFORMED BY**

Loetitia Saint-Jacques,
LVT

HOSPITAL NAME

MountainView AH

REFERRING VET

Dr. Hill

INVOICE

43407

DATE

6/22/23

- Subjectively thickened small intestine – The bowel wall thickening could be consistent with inflammation, edema, or infiltrative neoplasia.
- Prominent/thickened descending colon – Findings are most consistent with inflammatory disease, infectious disease, or early neoplastic change.

SECONDARY FINDINGS

- Decreased corticomedullary distinction in both kidneys with numerous small cortical cysts – The bilateral renal findings are consistent with age-related change.

INTERPRETATION OF THE FINDINGS & FURTHER RECOMMENDATIONS

There is generalized thickening of the small bowel, and the colon wall appears mildly thickened. Wall layering appears intact, so inflammatory disease would be most likely, although early neoplastic change cannot be ruled out.

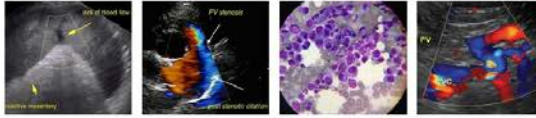
Consider such differentials as food allergy/dietary intolerance, GI parasitism, pancreatitis, dysbiosis, recurrent dietary indiscretion, IBD and less likely neoplasia, etc...

- Consider a novel protein/hydrolyzed protein diet (exclusively at least 4-6 weeks)
- Consider a GI panel to Texas A&M for evaluation of B12 levels, folate, PLI/TLI etc.. to further evaluate for pancreatic/small intestinal disease.
- Recommend chronic probiotic therapy.
- If symptoms are persistent despite taking these measures, consider obtaining GI biopsies.
- Additionally, I would recommend biopsies of the colon (colonoscopy due to the colon wall thickening observed). It is not clear if the diarrhea reported is large bowel or small bowel in origin.

The changes observed with the kidneys, liver and gallbladder are non-specific, possibly breed and age related. There are some moth-eaten/cystic lesions visualized in the spleen. The significance of these is uncertain. I suspect sampling would be challenging. Recommend continued monitoring with ultrasound. If this appears to be worsening, a splenectomy could be considered.

The right limb of the pancreas is prominent, hyperechoic and mottled with some ill-defined hypoechoic nodules. Correlate these findings with a quantitative PLI measurement. This could be associated with chronic pancreatic inflammation, pancreatic remodeling, or less likely pancreatic neoplasia. If the patient is not doing well you could consider a fine needle aspirate of the pancreas/pancreatic nodule.

Recommend three view thoracic radiographs to evaluate for possible concurrent thoracic disease/involvement.



PATIENT

Flora Browniee

SPECIES

Canine

BREED

West Highland White Terrier

SEX

Spayed Female

AGE

13 Years

WEIGHT

27 Pounds

INTERPRETED BY

Kathleen Sennello DVM,
MS, Diplomate ACVIM
(Small Animal Internal
Medicine)

IMAGING PERFORMED BY

Loetitia Saint-Jacques,
LVT

HOSPITAL NAME

MountainView AH

REFERRING VET

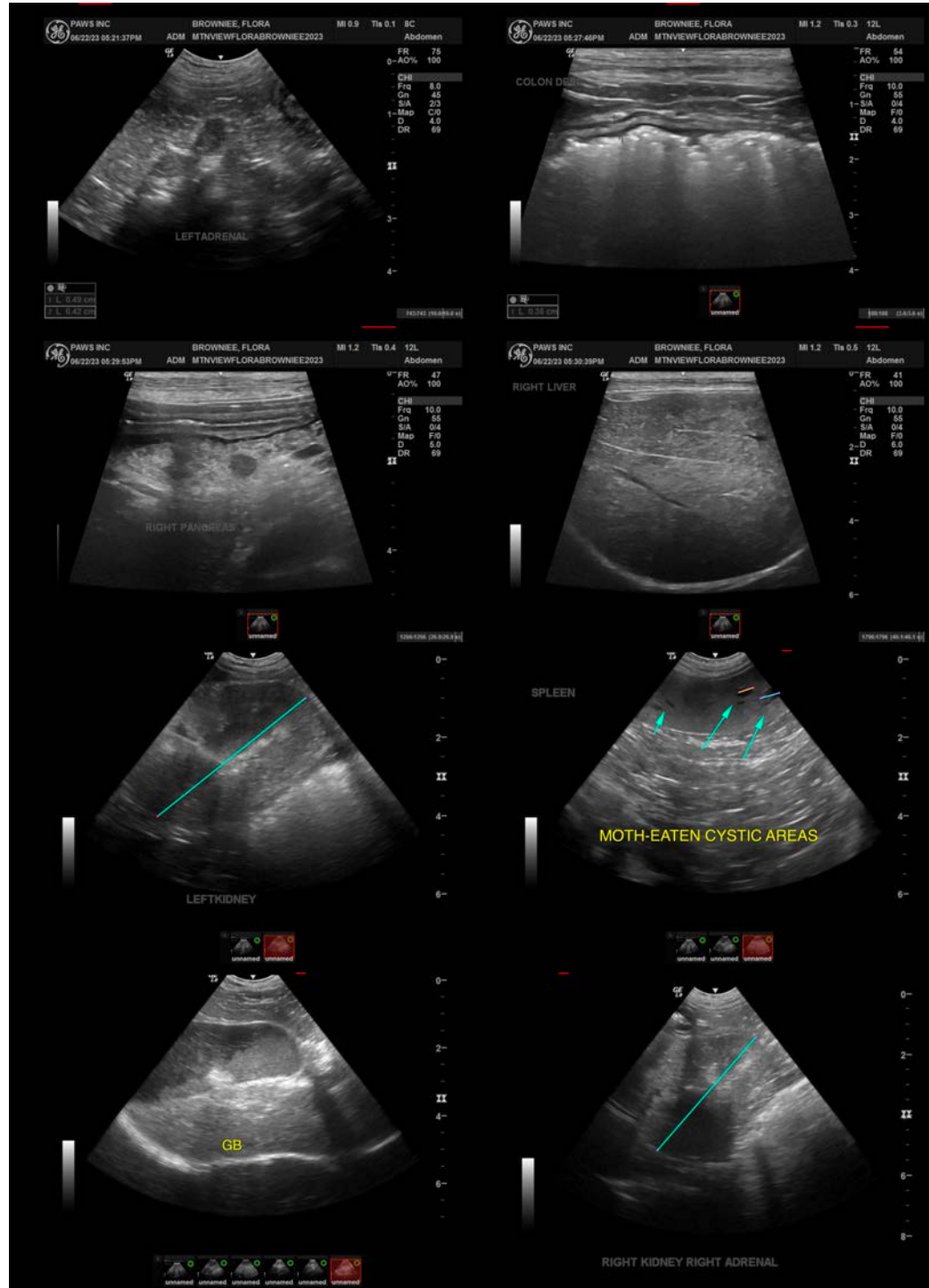
Dr. Hill

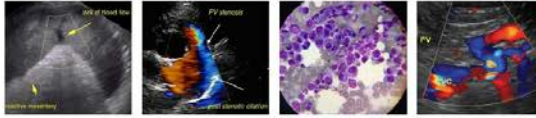
INVOICE

43407

DATE

6/22/23





PATIENT

Flora Browniee

SPECIES

Canine

BREED

West Highland White
Terrier

SEX

Spayed Female

AGE

13 Years

WEIGHT

27 Pounds

INTERPRETED BY

Kathleen Sennello DVM,
MS, Diplomate ACVIM
(Small Animal Internal
Medicine)

**IMAGING
PERFORMED BY**

Loetitia Saint-Jacques,
LVT

HOSPITAL NAME

MountainView AH

REFERRING VET

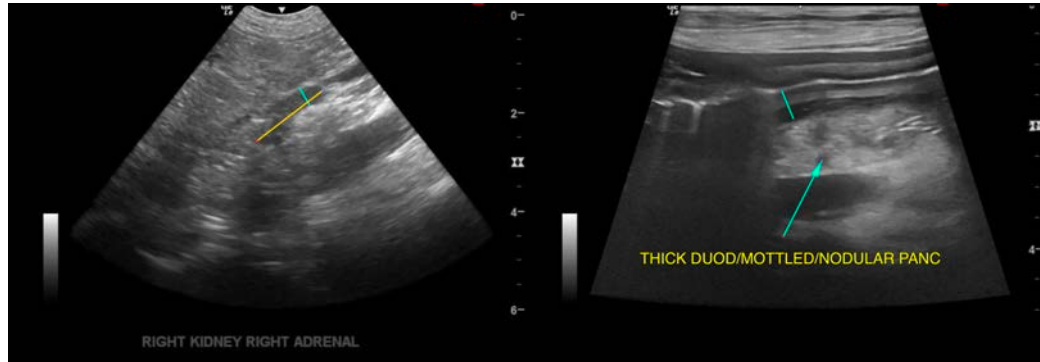Dr. Hill

INVOICE

43407

DATE

6/22/23



The information and recommendations provided are based on the images presented by the referring veterinarian/sonographer. No evaluation can be communicated regarding pathology that was not visible in the image/video clips provided.

Thank you for this referral. If the clinical or image interpretation does not parallel your findings or if I can be of any further assistance please contact me.

Kathleen Sennello DVM,MS, Diplomate ACVIM (Small animal Internal Medicine)

info@sonopath.com