



PATIENT PRESENTING CLINICAL SIGNS

Ebony Reece Change in appetite, hesitating when mealtimes. Seems to have a tense abdomen for palpation. No meds.

SPECIES Abnormal PE/Chem/CBC/UA Results: Rads showed poor definition in the area of the stomach. Bloodwork unremarkable.

Feline

BREED ULTRASONOGRAPHIC EXAMINATION OF THE ABDOMEN

DSH *Urinary System*

The urinary bladder is moderately distended with anechoic urine. The Bladder wall, trigone, ureteral papillae and visible urethra (to a depth of 2cm) appear normal with no evidence of wall thickening, mucosal irregularities, masses or cystic calculi.

SEX

Spayed Female

AGE

2.5 Years

The left kidney has a normal shape and size (3.52 cm). Overall echogenicity is normal with adequate corticomedullary distinction and a typical 1:3 cortex:medulla ratio. There is no evidence of focal perinephric inflammation or effusion. There is no evidence of pyelectasia, nephroliths, infarcts or hydroureter. Renal vasculature is normal.

WEIGHT

4.3 kg

The right kidney is normal in size (3.49 cm) but slightly irregular in shape (possibly due to previous infarct). Overall echogenicity is normal with adequate corticomedullary distinction and a typical 1:3 cortex:medulla ratio. There is no evidence of focal perinephric inflammation or effusion. There is no evidence of pyelectasia, nephroliths, infarcts or hydroureter. Renal vasculature is normal.

INTERPRETED BY

Kathleen Sennello DVM,
MS, Diplomate ACVIM
(Small Animal Internal
Medicine)

Adrenal Glands

The left adrenal gland is normal in size measuring 0.34 cm at the caudal pole. It is observed in its normal position cranial to the left renal artery. It is normal in appearance (uniformly hypoechoic) and shape with no evidence of a mass effect.

IMAGING PERFORMED BY

Crystal Hill

The right adrenal gland is normal in size measuring 0.42 cm at the caudal pole. It is observed in its normal position between the cranial aspect of the right kidney and the caudal vena cava. It is normal in appearance (uniformly hypoechoic) and shape with no evidence of a mass effect.

HOSPITAL NAME

Chippawa AH

Spleen

The spleen is subjectively normal in size (0.85 cm), echotexture is homogenous, and the splenic capsule is smooth with no irregularities. The blood flow through the hilus and splenic parenchyma appears normal. No focal parenchymal abnormalities are visualized.

REFERRING VET

Dr. Dowell/Van
Leeuwen

Liver

The liver is subjectively normal in size, and echogenicity with smooth peripheral margins. The parenchyma is homogenous echotexture. The visible portions of the vasculature and biliary tract appear normal. No focal nodules or cystic lesions are observed.

INVOICE

43387

DATE

6/22/23

The gallbladder lumen is moderately distended. The wall of the gall bladder is not thickened and has a smooth mucosal surface. Luminal contents are mild and primarily anechoic. The cystic and common bile ducts are normal/not visible.



PATIENT

Gastrointestinal

Ebony Reece

The stomach contains minimal luminal contents. It measures at a normal thickness of <0.36cm with some variability due to the presence of rugal folds. The distinction of the gastric wall layers is adequate and there is no impression of reduced peristaltic activity. No masses or focal lesions were observed.

SPECIES

Feline

The visualized areas of duodenum, jejunum and ileum have a relatively uniform diameter with minimal fluid distension. Wall thickness is normal. Bowel loops follow a curvilinear path with distinct wall layering maintaining the typical 1:3 muscularis:mucosa layer ratio. Duodenum wall measures 0.28 cm. Jejunum wall measures 0.22 cm. Visualized peristalsis appears appropriate. There is a focal area of small intestine that appears somewhat corrugated, measuring at a thickness of 0.27 cm with intact wall layering.

BREED

DSH

SEX

Spayed Female

The ileocecal junction was visualized and exhibited normal intact wall layering and is subjectively of normal thickness. Sections of colon are visualized with formed fecal material and gas shadowing distally. There is no observed focal or generalized colon wall thickening or loss of layering.

AGE

2.5 Years

Pancreas

The area of the pancreas is normal and isoechoic to surrounding mesentery. There is no evidence of nodules or cystic lesions. There is no evidence of regional mesenteric inflammation or fluid.

WEIGHT

4.3 kg

Free Abdomen

Evaluation of the peritoneal cavity did not reveal any evidence of effusion, or subjective lymphadenomegaly. The Medial iliac nodes appear normal and there was no evidence of a caudal aortic thrombus at the bifurcation. The omentum is of normal uniform echogenicity.

INTERPRETED BY

Kathleen Sennello DVM,
MS, Diplomate ACVIM
(Small Animal Internal
Medicine)

ULTRASONOGRAPHIC FINDINGS

- Slightly irregular right kidney – The irregularity and shape could be due to a previous infarct. Recommend continued monitoring.
- Focal area of small intestine with corrugation – Findings are most consistent with focal enteritis.

IMAGING PERFORMED BY

Crystal Hill

INTERPRETATION OF THE FINDINGS & FURTHER RECOMMENDATIONS

There is a small area of bowel corrugation noted with relatively normal appearing bowel (intact wall layering). This could be consistent with focal enteritis, which is a non-specific finding. Unfortunately, there are many causes for a decrease in appetite that cannot be diagnosed by ultrasound alone.

HOSPITAL NAME

Chippawa AH

REFERRING VET

Dr. Dowell/Van
Leeuwen

INVOICE

43387

DATE

6/22/23

- Consider a novel protein/hydrolyzed protein diet (exclusively at least 4-6 weeks)
- Consider a GI panel to Texas A&M for evaluation of B12 levels, folate, PLI/TLI etc.. to further evaluate for pancreatic/small intestinal disease.
- Recommend chronic probiotic therapy.
- Although no evidence of pancreatitis is visualized on today's exam, correlate with a quantitative fPLI level and consider empirical treatment for acute enteritis/mild pancreatitis.
- If symptoms are persistent, consider repeat imaging/lab work.
- If a primary enteropathy is present, GI biopsies may be necessary to obtain a diagnosis.



PATIENT

Ebony Reece

SPECIES

Feline

BREED

DSH

SEX

Spayed Female

AGE

2.5 Years

WEIGHT

4.3 kg

INTERPRETED BY

Kathleen Sennello DVM,
MS, Diplomate ACVIM
(Small Animal Internal
Medicine)

**IMAGING
PERFORMED BY**

Crystal Hill

HOSPITAL NAME

Chippawa AH

REFERRING VET

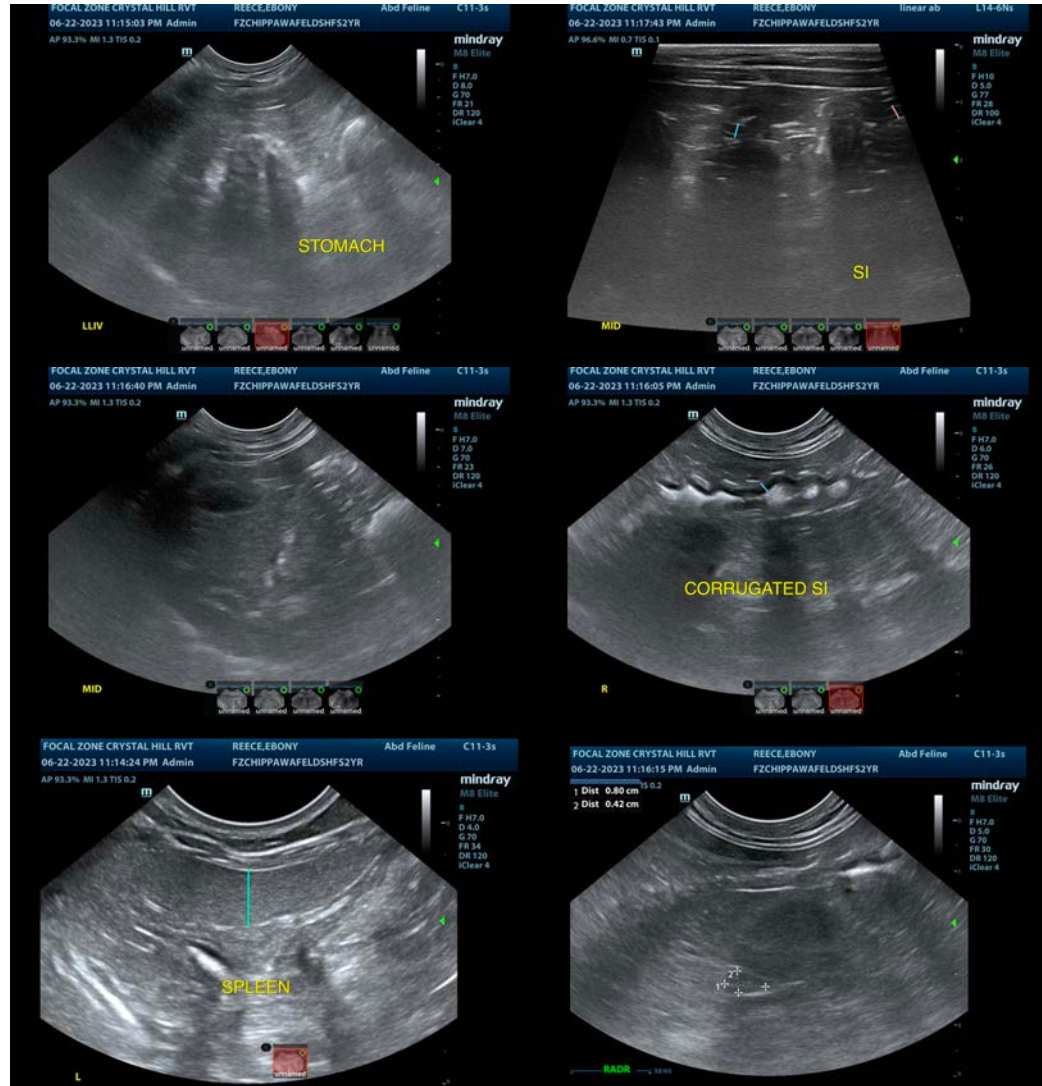
Dr. Dowell/Van
Leeuwen

INVOICE

43387

DATE

6/22/23





PATIENT

Ebony Reece

SPECIES

Feline

BREED

DSH

SEX

Spayed Female

AGE

2.5 Years

WEIGHT

4.3 kg

INTERPRETED BY

Kathleen Sennello DVM,
MS, Diplomate ACVIM
(Small Animal Internal
Medicine)

**IMAGING
PERFORMED BY**

Crystal Hill

HOSPITAL NAME

Chippawa AH

REFERRING VET

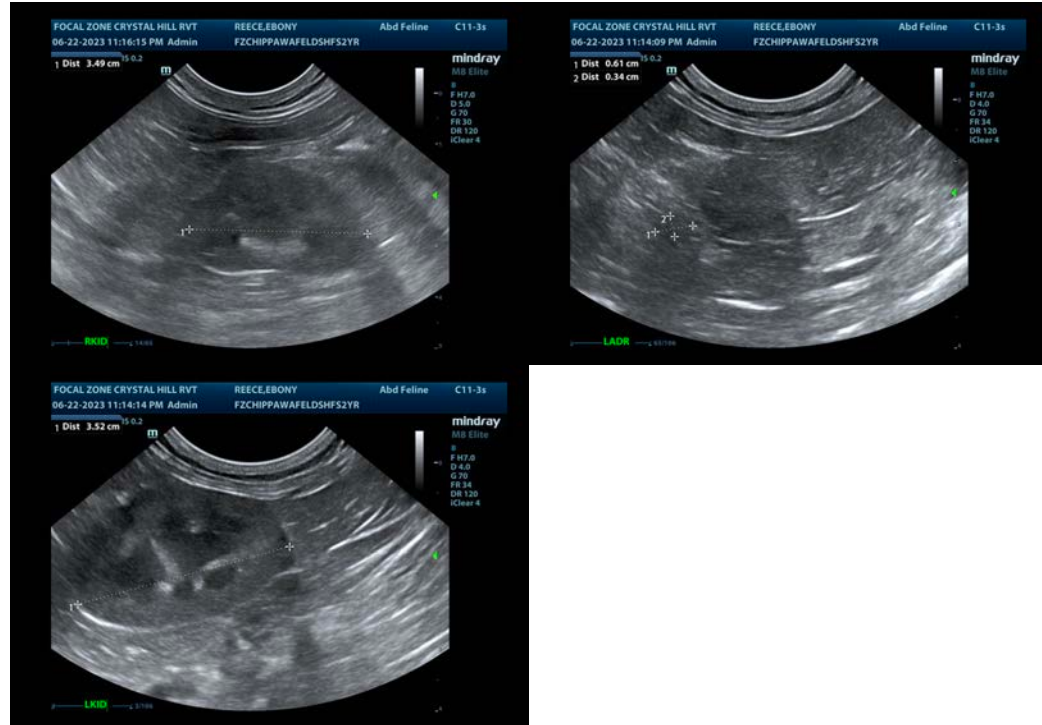
Dr. Dowell/Van
Leeuwen

INVOICE

43387

DATE

6/22/23



The information and recommendations provided are based on the images presented by the referring veterinarian/sonographer. No evaluation can be communicated regarding pathology that was not visible in the image/video clips provided.

Thank you for this referral. If the clinical or image interpretation does not parallel your findings or if I can be of any further assistance please contact me.

Kathleen Sennello DVM,MS, Diplomate ACVIM (Small animal Internal Medicine)

info@sonopath.com