



**PATIENT PRESENTING CLINICAL SIGNS**

Diego Coleman-Loh

Recent ultrasound performed but since then diagnosed as hyperthyroid and shortly after meds began, he went into renal failure. Has been losing weight. Assess kidneys. Currently thyroid levels back in normal range. Last ultrasound done May 23, 23.

**SPECIES**

Feline

**ULTRASONOGRAPHIC EXAMINATION OF THE ABDOMEN**

**BREED**

**Urinary System**

DSH

The urinary bladder is moderately distended with anechoic urine. The Bladder wall, trigone, ureteral papillae and visible urethra (to a depth of 2cm) appear normal with no evidence of wall thickening, mucosal irregularities, masses or cystic calculi.

**SEX**

Neutered Male

The left kidney has a normal shape and size (4.77 cm) with pyelectasia at 0.40 cm. Overall echogenicity is slightly hyperechoic with poor corticomedullary distinction and a typical 1:3 cortex:medulla ratio. There is no evidence of focal perinephric inflammation or effusion. There is no evidence of nephroliths, infarcts or hydronephrosis. Renal vasculature is normal.

**AGE**

15 Years

**WEIGHT**

5.7 kg

The right kidney has a normal shape and size (4.82 cm) with pyelectasia at 0.52 cm. Overall echogenicity is slightly hyperechoic with poor corticomedullary distinction and a typical 1:3 cortex:medulla ratio. There is no evidence of focal perinephric inflammation or effusion. There is no evidence of nephroliths, infarcts or hydronephrosis. Renal vasculature is normal.

**INTERPRETED BY**

**Adrenal Glands**

Kathleen Sennello DVM,  
MS, Diplomate ACVIM  
(Small Animal Internal  
Medicine)

The left adrenal gland is normal in size measuring 0.45 cm at the caudal pole. It is observed in its normal position cranial to the left renal artery. It is normal in appearance (uniformly hypoechoic) and shape with no evidence of a mass effect.

**IMAGING PERFORMED BY**

The right adrenal gland is normal in size measuring 0.41 cm at the caudal pole. It is observed in its normal position between the cranial aspect of the right kidney and the caudal vena cava. It is normal in appearance (uniformly hypoechoic) and shape with no evidence of a mass effect.

Crystal Hill

**HOSPITAL NAME**

**Spleen**

East Plains AH

The spleen is subjectively normal in size (0.90 cm), echotexture is homogenous, and the splenic capsule is smooth with no irregularities. The blood flow through the hilus and splenic parenchyma appears normal. No focal parenchymal abnormalities are visualized.

**REFERRING VET**

**Liver**

Dr. Loh

The liver is subjectively normal in size, and echogenicity with smooth peripheral margins. The parenchyma is homogenous echotexture. The visible portions of the vasculature and biliary tract appear normal. No focal nodules or cystic lesions are observed.

**INVOICE**

43389

**DATE**

6/22/23

The gallbladder lumen is moderately distended. The wall of the gall bladder is not thickened and has a smooth mucosal surface. Luminal contents are mild and primarily anechoic. The cystic and common bile ducts are normal/not visible.

**Gastrointestinal**

The stomach contains minimal luminal contents. It measures at a normal thickness of <0.36cm with some variability due to the presence of rugal folds. The distinction of the gastric wall layers is adequate and there is no impression of reduced peristaltic activity. No masses or focal lesions were observed.


**PATIENT**

Diego Coleman-Loh

**SPECIES**

Feline

**BREED**

DSH

**SEX**

Neutered Male

**AGE**

15 Years

**WEIGHT**

5.7 kg

**INTERPRETED BY**

 Kathleen Sennello DVM,  
 MS, Diplomate ACVIM  
 (Small Animal Internal  
 Medicine)

**IMAGING  
 PERFORMED BY**

Crystal Hill

**HOSPITAL NAME**

East Plains AH

**REFERRING VET**

Dr. Loh

**INVOICE**

43389

**DATE**

6/22/23

The visualized areas of duodenum, jejunum and ileum have a uniform diameter with minimal fluid distension. Wall thickness is normal to slightly increased. Bowel loops follow a typical curvilinear path with distinct wall layering, but some areas display a prominent muscularis layer which does not display the typical 1:3 muscularis:mucosa layer ratio. Jejunum wall measures 0.25 cm. Visualized peristalsis appears appropriate. There were no focal lesions consistent with obstruction or a mass effect observed.

The ileocecal junction was visualized and exhibited normal intact wall layering and is subjectively of normal thickness. Sections of colon are visualized with formed fecal material and gas shadowing distally. There is no observed focal or generalized colon wall thickening or loss of layering.

***Pancreas***

The pancreas is normal and isoechoic to surrounding mesentery. There is no evidence of nodules or cystic lesions. There is no evidence of regional mesenteric inflammation or fluid.

***Free Abdomen***

Evaluation of the peritoneal cavity did not reveal any evidence of effusion, or subjective lymphadenomegaly. The Medial iliac nodes appear normal and there was no evidence of a caudal aortic thrombus at the bifurcation. The omentum is of normal uniform echogenicity.

**ULTRASONOGRAPHIC FINDINGS**

- Decreased corticomedullary distinction in both kidneys with bilateral pyelectasia – Mild loss of corticomedullary distinction in both kidneys could be consistent with chronic degenerative disease or interstitial nephrosis. Pyelectasia of the kidney(s) could be consistent with pyelonephritis, chronic renal disease, secondary to PU/PD or fluid therapy (if applicable), other.
- Prominent muscularis layer of the small intestine – The small intestinal wall changes could be consistent with an underlying inflammatory process. These types of changes can sometimes be seen in normal older cats. Correlate with clinical signs.

**INTERPRETATION OF THE FINDINGS & FURTHER RECOMMENDATIONS**

The changes observed in the kidneys are most consistent with chronic progressive age related renal disease. There is mild bilateral pyelectasia with no evidence of an obstructive process. Recommend a blood pressure, urinalysis and culture as a baseline.

The muscularis of the small intestine is somewhat prominent. This can be a normal finding in some older cats. If primary GI disease is suspected, consider further evaluation with a GI panel to Texas A&M for qualitative fPLI, TLI, cobalamin and folate to further evaluate.



**PATIENT**

Diego Coleman-Loh

**SPECIES**

Feline

**BREED**

DSH

**SEX**

Neutered Male

**AGE**

15 Years

**WEIGHT**

5.7 kg

**INTERPRETED BY**

Kathleen Sennello DVM,  
MS, Diplomate ACVIM  
(Small Animal Internal  
Medicine)

**IMAGING  
PERFORMED BY**

Crystal Hill

**HOSPITAL NAME**

East Plains AH

**REFERRING VET**

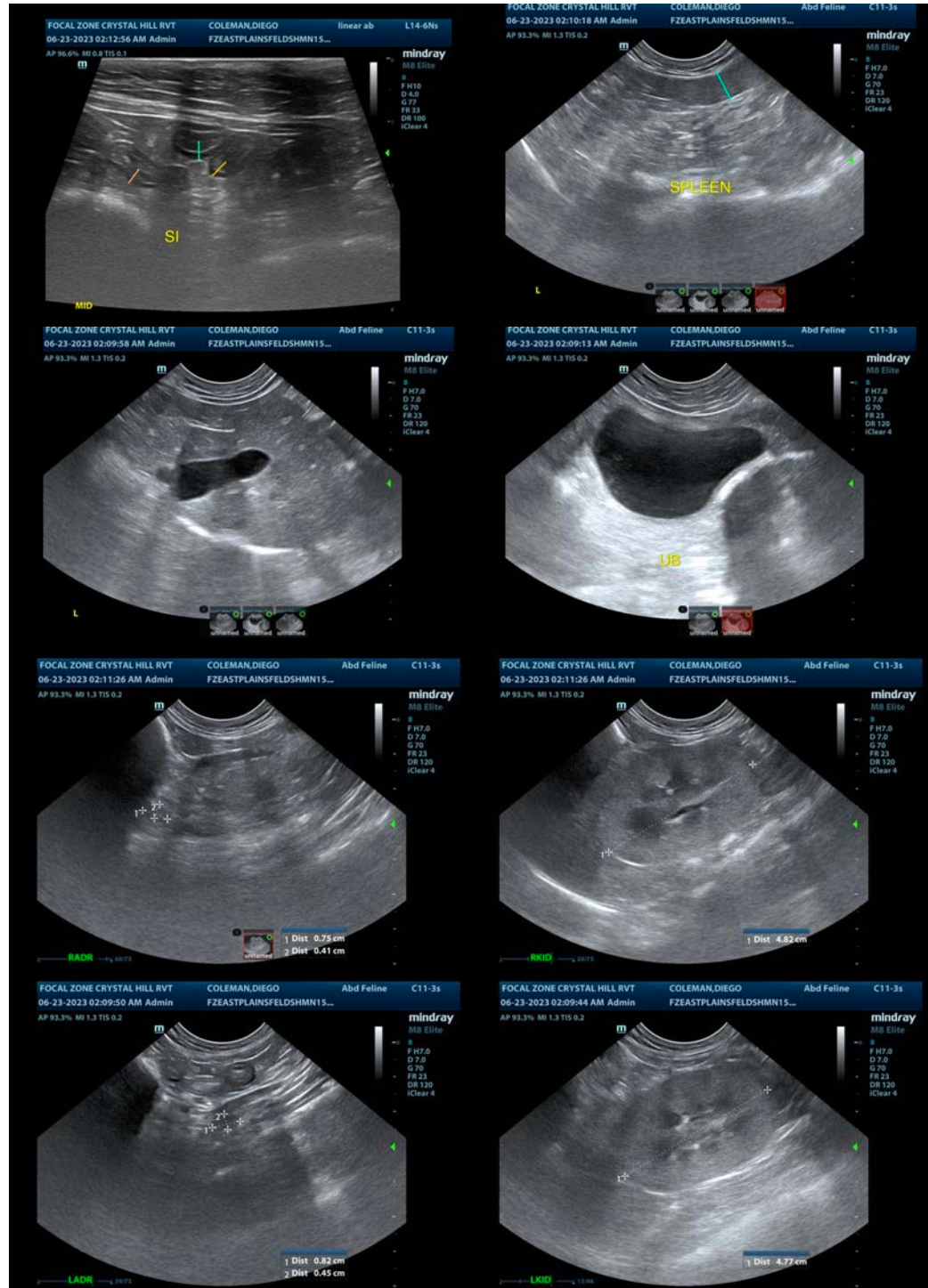
Dr. Loh

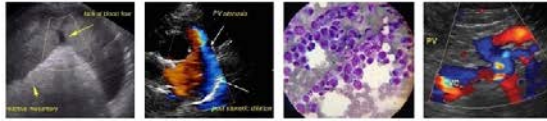
**INVOICE**

43389

**DATE**

6/22/23





**PATIENT**

Diego Coleman-Loh

The information and recommendations provided are based on the images presented by the referring veterinarian/sonographer. No evaluation can be communicated regarding pathology that was not visible in the image/video clips provided.

**SPECIES**

Feline

Thank you for this referral. If the clinical or image interpretation does not parallel your findings or if I can be of any further assistance please contact me.

**BREED**

DSH

Kathleen Sennello DVM,MS, Diplomate ACVIM (Small animal Internal Medicine)

**SEX**

Neutered Male

info@sonopath.com

**AGE**

15 Years

**WEIGHT**

5.7 kg

**INTERPRETED BY**

Kathleen Sennello DVM,  
MS, Diplomate ACVIM  
(Small Animal Internal  
Medicine)

**IMAGING  
PERFORMED BY**

Crystal Hill

**HOSPITAL NAME**

East Plains AH

**REFERRING VET**

Dr. Loh

**INVOICE**

43389

**DATE**

6/22/23