



**PATIENT PRESENTING CLINICAL SIGNS**

Stella Parkin Pt has been losing weight, was seen on 6/18 for vomiting and diarrhea. No current meds

**SPECIES ULTRASONOGRAPHIC EXAMINATION OF THE ABDOMEN**

**Canine Urinary System**

The urinary bladder is moderately distended with anechoic urine. The Bladder wall, trigone, ureteral papillae and visible urethra (to a depth of 2cm) appear normal with no evidence of wall thickening, mucosal irregularities, masses or cystic calculi.

**BREED**

Pug X

The left kidney has a normal shape and size (4.62 cm). Overall echogenicity is slightly hyperechoic with poor corticomedullary distinction and a typical 1:3 cortex:medulla ratio. There is no evidence of perinephric inflammation or effusion. There is no evidence of pyelectasia, nephroliths, infarcts or hydroureter. Renal vasculature is normal.

**SEX**

Spayed Female

The right kidney has a normal shape and size (5.02 cm). Overall echogenicity is slightly hyperechoic with poor corticomedullary distinction and a typical 1:3 cortex:medulla ratio. There is no evidence of perinephric inflammation or effusion. There is no evidence of pyelectasia, nephroliths, infarcts or hydroureter. Renal vasculature is normal.

**AGE**

12 Years 8 Months

**Adrenal Glands**

**WEIGHT**

22.2 Pounds

The left adrenal gland is normal in size measuring 0.96 cm at the cranial pole, 0.74 cm at the caudal pole, and 2.4 cm in length. It is observed in its normal position cranial to the left renal artery. It is somewhat abnormal in appearance in that there is a hyperechoic nodule in the cranial pole measuring 1.12 cm x 0.90 cm. This lesion does not deviate the shape of the adrenal significantly, and there is no obvious evidence of vascular invasion.

**INTERPRETED BY**

Kathleen Sennello DVM,  
MS, Diplomate ACVIM  
(Small Animal Internal  
Medicine)

The right adrenal gland is normal in size measuring 1.21 cm at the cranial pole, 0.57 at the caudal pole, and 3.43 cm in length. It is observed in its normal position between the cranial aspect of the right kidney and the caudal vena cava. It is somewhat abnormal in appearance in that there is a hyperechoic lesion mid body in the adrenal, measuring 0.75 cm x 0.56 cm. There is no obvious evidence of vascular invasion.

**IMAGING PERFORMED BY**

Jessica Miller

**Spleen**

The spleen is subjectively normal in size, echotexture is homogenous, and the splenic capsule is smooth with no irregularities. The blood flow through the hilus and splenic parenchyma appears normal. No focal parenchymal abnormalities are visualized.

**HOSPITAL NAME**

Berkeley Heights AH

**Liver**

The liver is subjectively normal in size with smooth peripheral margins. The parenchyma is hyperechoic and homogenous in echotexture. The visible portions of the vasculature and biliary tract appear normal. No focal nodules or cystic lesions are observed.

**REFERRING VET**

Dr. Seltzer

The gall bladder lumen is moderately distended. The wall of the gall bladder is not thickened and has a smooth mucosal surface. There is a moderate amount of hyperechoic debris. The cystic and common bile ducts are normal/not visible.

**INVOICE**

38969

**Gastrointestinal**

The stomach is moderately dilated with fluid and irregular shadowing material most consistent with normal ingesta and gas. It measures at a normal thickness of <0.7cm with some variability due to the

**DATE**

6/22/22



**PATIENT**

Stella Parkin

presence of rugal folds. The distinction of the gastric wall layering is adequate and there is no impression of reduced peristaltic activity. No masses or focal lesions were observed.

**SPECIES**

Canine

The visualized areas of duodenum, jejunum and ileum have a relatively uniform diameter with minimal fluid distension. Wall thickness is normal. Bowel loops follow a curvilinear path with distinct wall layering maintaining the typical 1:3 muscularis:mucosa layer ratio. Jejunum wall measured 0.32 cm. Visualized peristalsis appears appropriate. There were no focal lesions consistent with obstruction or a mass effect observed.

**BREED**

Pug X

The ileocecal junction was visualized and exhibited normal intact wall layering and is subjectively of normal thickness. Sections of colon are visualized with formed fecal material and gas shadowing distally. There is no observed focal or generalized colon wall thickening or loss of layering.

**SEX**

Spayed Female

**Pancreas**

The pancreas is normal and isoechoic to surrounding mesentery. There is no evidence of nodules or cystic lesions. There is no evidence of regional mesenteric inflammation or fluid.

**AGE**

12 Years 8 Months

**Free Abdomen**

Evaluation of the peritoneal cavity did not reveal any evidence of effusion, or subjective lymphadenomegaly. The Medial iliac nodes appear normal and there was no evidence of a caudal aortic thrombus at the bifurcation. The omentum is of normal uniform echogenicity.

**WEIGHT**

22.2 Pounds

**ULTRASONOGRAPHIC FINDINGS**

- Hyperechoic nodule in the cranial pole of the left adrenal gland and mid body in the right adrenal gland – The significance of these lesions is unclear. They could represent incidental hyperplasia, etc., be benign or malignant early neoplastic change, or less likely represent metastatic neoplasia.
- Decreased corticomedullary distinction in both kidneys – The bilateral renal findings are consistent with age-related change.
- Hyperechoic liver – The diffuse hepatic changes are non-specific and can be seen with vacuolar hepatopathy, reactive change, nodular hyperplasia or, less likely, inflammatory/immune-mediated disease, infiltrative neoplasia, or other hepatopathy.
- Moderate gallbladder debris – The significance of the aggregated gallbladder sludge is unclear. This could represent an early mucocele, cholestasis, or may be secondary to fasting.
- Moderate fluid and shadowing ingesta within the gastric lumen – correlate with feeding history. If the patient was adequately fasted, consider such differentials as delayed gastric emptying, pyloric outflow tract obstruction (not observed, but shadowing ingesta impairs evaluation of this area), etc.

**INTERPRETED BY**

Kathleen Sennello DVM,  
MS, Diplomate ACVIM  
(Small Animal Internal  
Medicine)

**IMAGING PERFORMED BY**

Jessica Miller

**HOSPITAL NAME**

Berkeley Heights AH

**REFERRING VET**

Dr. Seltzer

**INVOICE**

38969

**DATE**

6/22/22

**INTERPRETATION OF THE FINDINGS & FURTHER RECOMMENDATIONS**

An obvious lesion responsible for the vomiting, diarrhea and weight loss reported is not observed. Correlate these findings with bloodwork changes. If liver enzymes are elevated, consider a liver function test, fine needle aspirate, etc.

There are hyperechoic lesions visualized in both adrenal glands. Neither of these lesions are very large, nor do they significantly affect the normal shape of the adrenal gland. These could be incidental findings or be early benign/cancerous lesions, or active or non-active lesions. At this time, I would recommend a blood pressure evaluation and continued monitoring with ultrasound, as it does not sound like this pet



**PATIENT**

Stella Parkin

has symptoms typical of Cushing's disease (recheck adrenal nodules in approximately 2-3 months, sooner if there are concerns).

**SPECIES**

Canine

The renal changes observed are most consistent with age related kidney disease. If there is any evidence of azotemia or lack of concentrating ability, then consider a blood pressure evaluation, urinalysis and culture.

**BREED**

Pug X

If bloodwork does not indicate a metabolic cause for the GI signs noted, then consider primary gastrointestinal disease. No GI lesions were observed, but you can still have significant gastrointestinal disease with no observable ultrasonographic lesions.

**SEX**

Spayed Female

- Consider a GI panel to Texas A&M for a qualitative PLI, TLI, cobalamin and folate to look further for evidence of pancreatic or small intestinal disease.

**AGE**

12 Years 8 Months

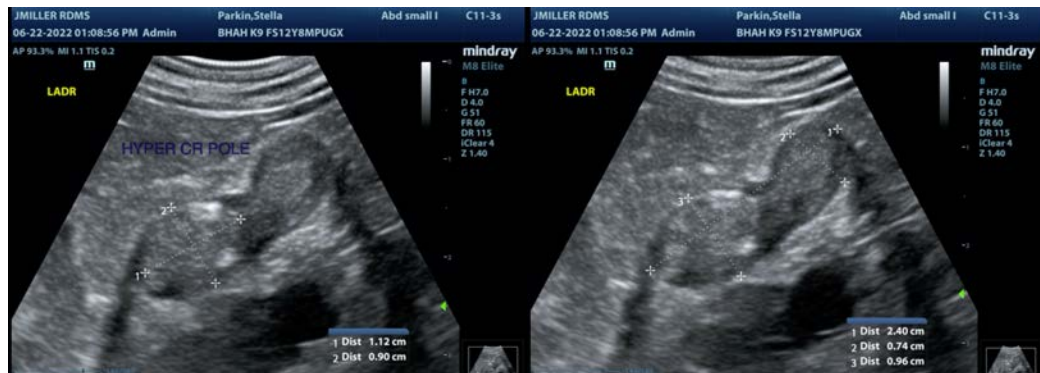- Consider a novel protein/hydrolyzed protein prescription diet.
- Recommend chronic probiotic therapy.
- If symptoms persist, consider reimaging and/or obtaining biopsies of the GI tract.
- Consider three view thoracic radiographs to rule out concurrent thoracic disease/involvement.

**WEIGHT**

22.2 Pounds

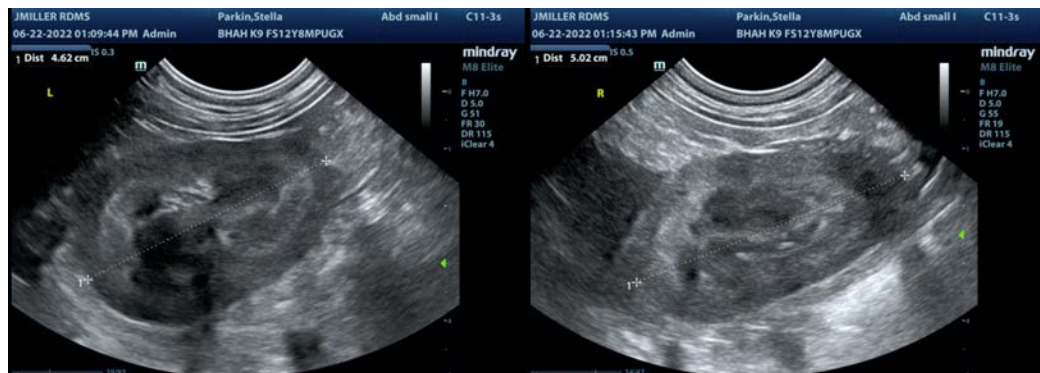**INTERPRETED BY**

Kathleen Sennello DVM, MS, Diplomate ACVIM (Small Animal Internal Medicine)



**IMAGING PERFORMED BY**

Jessica Miller



**HOSPITAL NAME**

Berkeley Heights AH

**REFERRING VET**

Dr. Seltzer

**INVOICE**

38969

**DATE**

6/22/22



**PATIENT**

Stella Parkin

**SPECIES**

Canine

**BREED**

Pug X

**SEX**

Spayed Female

**AGE**

12 Years 8 Months

**WEIGHT**

22.2 Pounds

**INTERPRETED BY**

Kathleen Sennello DVM,  
MS, Diplomate ACVIM  
(Small Animal Internal  
Medicine)

**IMAGING  
PERFORMED BY**

Jessica Miller

**HOSPITAL NAME**

Berkeley Heights AH

**REFERRING VET**

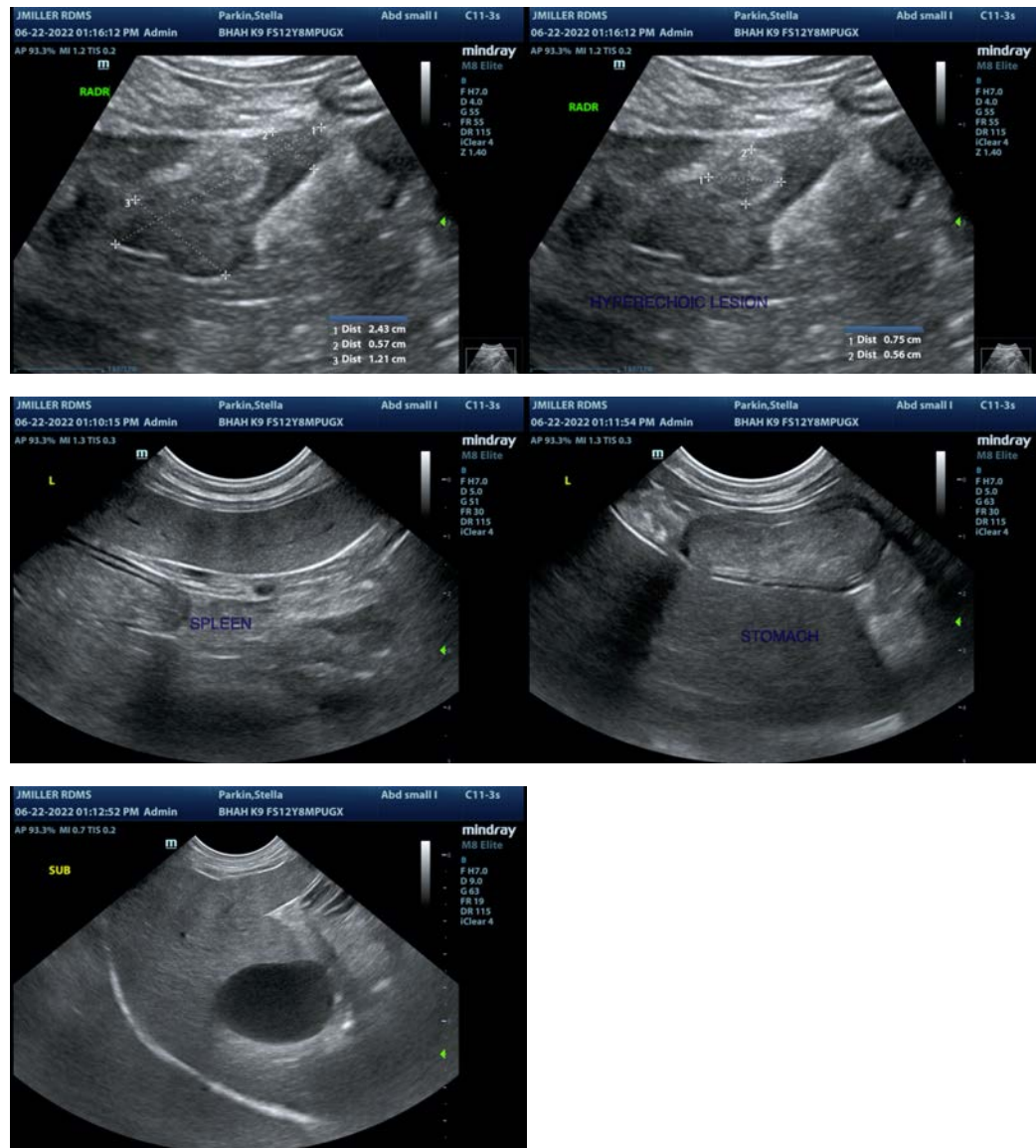
Dr. Seltzer

**INVOICE**

38969

**DATE**

6/22/22



The information and recommendations provided are based on the images presented by the referring veterinarian/sonographer. No evaluation can be communicated regarding pathology that was not visible in the image/video clips provided.

Thank you for this referral. If the clinical or image interpretation does not parallel your findings or if I can be of any further assistance please contact me.

Kathleen Sennello DVM,MS, Diplomate ACVIM (Small animal Internal Medicine)

kathleen.sennello@sonopath.com