



**PATIENT PRESENTING CLINICAL SIGNS**

Eddie Nightingale weight loss acting off at home  
Abnormal PE/Chem/CBC/UA Results: chem, cbc, t4 all normal Current Medications 5 mg  
Prednisolone daily

**SPECIES**

Feline

**BREED**

Bengal

**SEX**

Neutered Male

**AGE**

10 Years

**WEIGHT**

12.5 Pounds

**INTERPRETED BY**

Kathleen Sennello DVM,  
MS, Diplomate ACVIM  
(Small Animal Internal  
Medicine)

**IMAGING PERFORMED BY**

Sara Hansen

**HOSPITAL NAME**

Willakenzie AC

**REFERRING VET**

Dr. Brandt

**INVOICE**

38979

**DATE**

6/22/22

**ULTRASONOGRAPHIC EXAMINATION OF THE ABDOMEN**

**Urinary System**

The urinary bladder is moderately distended with anechoic urine. The Bladder wall, trigone, ureteral papillae and visible urethra (to a depth of 2cm) appear normal with no evidence of wall thickening, mucosal irregularities, masses or cystic calculi.

The left kidney has a normal shape and size (4.72 cm). Overall echogenicity is normal with adequate corticomedullary distinction and a typical 1:3 cortex:medulla ratio. There is no evidence of perinephric inflammation or effusion. There is no evidence of pyelectasia, nephroliths, infarcts or hydroureter. Renal vasculature is normal.

The right kidney has a normal shape and size (3.15 cm) with a 0.62 cm peripheral cortical cyst. Overall echogenicity is normal with adequate corticomedullary distinction and a typical 1:3 cortex:medulla ratio. There is no evidence of perinephric inflammation or effusion. There is no evidence of pyelectasia, nephroliths, infarcts or hydroureter. Renal vasculature is normal.

**Adrenal Glands**

The left adrenal gland is normal in size measuring 0.32 cm at the caudal pole. It is observed in its normal position cranial to the left renal artery. It is normal in appearance (uniformly hypoechoic) and shape with no evidence of a mass effect.

The right adrenal gland is normal in size measuring 0.32 cm at the caudal pole. It is observed in its normal position between the cranial aspect of the right kidney and the caudal vena cava. It is normal in appearance (uniformly hypoechoic) and shape with no evidence of a mass effect.

**Spleen**

The spleen is subjectively normal in size (0.8 cm at the level of the hilus), echotexture is homogenous, and the splenic capsule is smooth with no irregularities. The blood flow through the hilus and splenic parenchyma appears normal. No focal parenchymal abnormalities are visualized.

**Liver**

The liver is subjectively normal in size, and echogenicity with smooth peripheral margins. The parenchyma is homogenous echotexture. The visible portions of the vasculature and biliary tract appear normal. No focal nodules or cystic lesions are observed.

The gallbladder lumen is moderately distended. The wall of the gall bladder is not thickened and has a smooth mucosal surface. Luminal contents are primarily anechoic. The cystic and common bile ducts are normal/not visible.

**Gastrointestinal**

The stomach is moderately dilated with fluid and irregular shadowing material most consistent with normal ingesta and gas. It measures at a normal thickness of <0.36cm with some variability due to the



**PATIENT**

Eddie Nightingale

**SPECIES**

Feline

**BREED**

Bengal

**SEX**

Neutered Male

**AGE**

10 Years

**WEIGHT**

12.5 Pounds

**INTERPRETED BY**

Kathleen Sennello DVM,  
MS, Diplomate ACVIM  
(Small Animal Internal  
Medicine)

**IMAGING  
PERFORMED BY**

Sara Hansen

**HOSPITAL NAME**

Willakenzie AC

**REFERRING VET**

Dr. Brandt

**INVOICE**

38979

**DATE**

6/22/22

presence of rugal folds. The distinction of the gastric wall layering is adequate and there is no impression of reduced peristaltic activity. No masses or focal lesions were observed.

The visualized areas of duodenum, jejunum and ileum have a relatively uniform diameter with moderate fluid distension. Wall thickness is normal. Bowel loops follow a curvilinear path with distinct wall layering maintaining the typical 1:3 muscularis:mucosa layer ratio. Jejunum wall measured 0.24 cm. Visualized peristalsis appears appropriate. There were no focal lesions consistent with obstruction or a mass effect observed.

The ileocecal junction was visualized and exhibited normal intact wall layering and is subjectively of normal thickness. Sections of colon are visualized with formed fecal material and gas shadowing distally. There is no observed focal or generalized colon wall thickening or loss of layering.

***Pancreas***

The pancreas is normal and isoechoic to surrounding mesentery. There is no evidence of nodules or cystic lesions. There is no evidence of regional mesenteric inflammation or fluid.

***Free Abdomen***

Evaluation of the peritoneal cavity did not reveal any evidence of effusion, or subjective lymphadenomegaly. The Medial iliac nodes appear normal and there was no evidence of a caudal aortic thrombus at the bifurcation. The omentum is of normal uniform echogenicity.

**ULTRASONOGRAPHIC FINDINGS**

- Moderate fluid/ingesta dilation of the stomach and small intestine – Correlate with feeding history. If the patient was adequately fasted, consider delayed gastric emptying/ileus, or much less likely a distal partial obstruction (none observed).

**INTERPRETATION OF THE FINDINGS & FURTHER RECOMMENDATIONS**

Today's scan is relatively normal. No large focal lesions were visualized associated with the gastrointestinal tract or other abdominal structures. There is a generalized fluid distention of the small intestine and stomach. This could be post-prandial or be consistent with malabsorption/ileus, etc. If primary GI disease is suspected, then consider the following:

- Consider a novel protein/hydrolyzed protein prescription diet.
- Consider chronic probiotic therapy.
- Recommend a GI panel to Texas A&M for a qualitative fPLI, TLI, cobalamin and folate to further evaluate the small intestine and pancreas.
- Recommend 3-view thoracic radiographs.
- Correlate ultrasound findings with abdominal radiographs. No obstructive lesion is observed, but cannot be definitively ruled out based on ultrasound alone.
- If symptoms persist, and underlying GI disease is thought likely, consider obtaining GI biopsies.



**PATIENT**

Eddie Nightingale

**SPECIES**

Feline

**BREED**

Bengal

**SEX**

Neutered Male

**AGE**

10 Years

**WEIGHT**

12.5 Pounds

**INTERPRETED BY**

Kathleen Sennello DVM,  
MS, Diplomate ACVIM  
(Small Animal Internal  
Medicine)

**IMAGING PERFORMED BY**

Sara Hansen

**HOSPITAL NAME**

Willakenzie AC

**REFERRING VET**

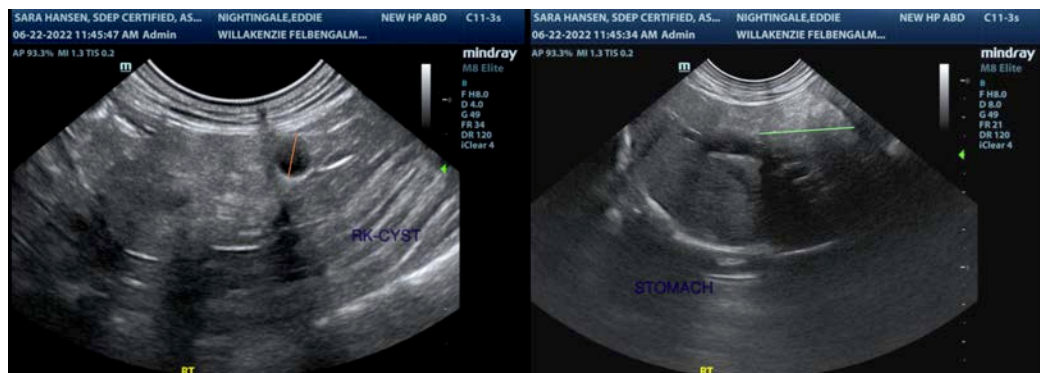
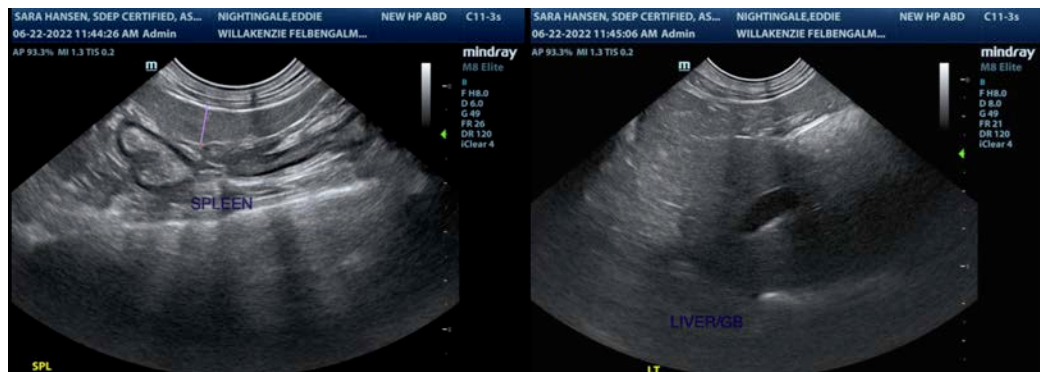
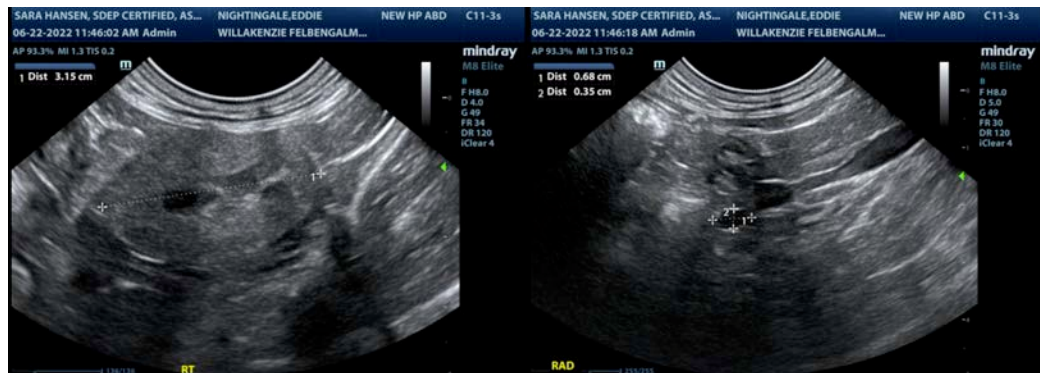
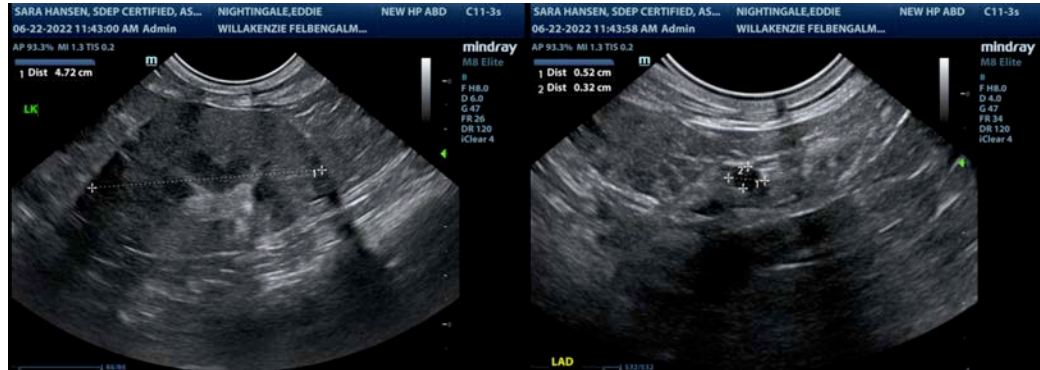
Dr. Brandt

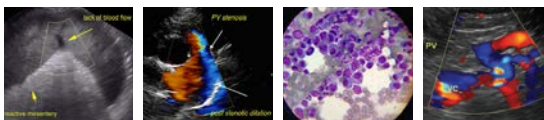
**INVOICE**

38979

**DATE**

6/22/22





## PATIENT

Eddie Nightingale

## SPECIES

Feline

## BREED

Bengal

## SEX

Neutered Male

## AGE

10 Years

## WEIGHT

12.5 Pounds

## INTERPRETED BY

Kathleen Sennello DVM,  
MS, Diplomate ACVIM  
(Small Animal Internal  
Medicine)

## IMAGING PERFORMED BY

Sara Hansen

## HOSPITAL NAME

Willakenzie AC

## REFERRING VET

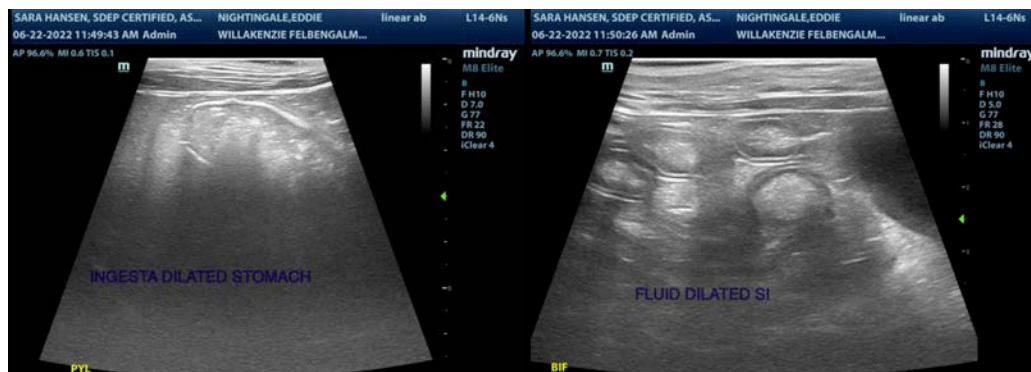
Dr. Brandt

## INVOICE

38979

## DATE

6/22/22



The information and recommendations provided are based on the images presented by the referring veterinarian/sonographer. No evaluation can be communicated regarding pathology that was not visible in the image/video clips provided.

Thank you for this referral. If the clinical or image interpretation does not parallel your findings or if I can be of any further assistance please contact me.

Kathleen Sennello DVM,MS, Diplomate ACVIM (Small animal Internal Medicine)

kathleen.sennello@sonopath.com