

**DATE PRESENTING CLINICAL SIGNS**

6/21/23 Diarrhea started on 6/19/2023. Has never had diarrhea before. Decreased appetite. Have not examined since routine dental cleaning on May 1, 2023--will do so on Wed. BW May 1 normal. Proactive owner, interested in baseline AUS.

**PATIENT**

Samantha Lucas

Current Medications: Will be on gabapentin prior to ultrasound.

Date of Previous IntraPet Ultrasound: No previous.

Sedation: Patient sedated with Torbugesic &amp; Midazolam.

Stat Report: Not requested.

Imaging Performed By: Andi Parkinson, BS, RDMS.

**SPECIES**

Feline

**BREED**

DLH

**SEX**

Spayed Female

**AGE**

1/1/14

**WEIGHT**

8.6 Pounds

**INTERPRETED BY**

Kathleen Sennello DVM,  
MS, Diplomate ACVIM  
(Small Animal Internal  
Medicine)

**ULTRASONOGRAPHIC EXAMINATION OF THE ABDOMEN****Urinary System**

The urinary bladder is moderately distended with anechoic urine. The Bladder wall, trigone, ureteral papillae and visible urethra (to a depth of 2cm) appear normal with no evidence of wall thickening, mucosal irregularities, masses or cystic calculi.

The left kidney has a normal shape and size (3.46 cm). Overall echogenicity is normal with adequate corticomedullary distinction and a typical 1:3 cortex:medulla ratio. There is no evidence of focal perinephric inflammation or effusion. There is no evidence of pyelectasia, nephroliths, infarcts or hydroureter. Renal vasculature is normal.

The right kidney has a normal shape and size (3.65 cm). Overall echogenicity is normal with adequate corticomedullary distinction and a typical 1:3 cortex:medulla ratio. There is no evidence of focal perinephric inflammation or effusion. There is no evidence of pyelectasia, nephroliths, infarcts or hydroureter. Renal vasculature is normal.

**Adrenal Glands**

The left adrenal gland is normal in size measuring 0.42 cm at the caudal pole. It is observed in its normal position cranial to the left renal artery. It is normal in appearance (uniformly hypoechoic) and shape with no evidence of a mass effect.

The right adrenal gland is normal in size measuring 0.28 cm at the caudal pole. It is observed in its normal position between the cranial aspect of the right kidney and the caudal vena cava. It is normal in appearance (uniformly hypoechoic) and shape with no evidence of a mass effect.

**HOSPITAL NAME**

Paradise AH

**REFERRING VET**

Dr. Riehl

**Spleen**

The spleen is subjectively normal in size (1.0 cm), echotexture is homogenous, and the splenic capsule is smooth with no irregularities. The blood flow through the hilus and splenic parenchyma appears normal. No focal parenchymal abnormalities are visualized.

**INVOICE**

43335

**Liver**

The liver is subjectively normal in size, and echogenicity with smooth peripheral margins. The parenchyma is homogenous echotexture. The visible portions of the vasculature and biliary tract appear normal. No focal nodules or cystic lesions are observed.

The gallbladder lumen is moderately distended. The wall of the gall bladder is not thickened and has a smooth mucosal surface. Luminal contents are mild and primarily anechoic. The bile duct appears somewhat tortuous and prominent, measuring at 0.22 cm.

### ***Gastrointestinal***

The stomach contains minimal luminal contents. It measures at a normal thickness of <0.36cm with some variability due to the presence of rugal folds. The distinction of the gastric wall layers is adequate and there is no impression of reduced peristaltic activity. No masses or focal lesions were observed.

The visualized areas of duodenum, jejunum and ileum have a uniform diameter with minimal fluid distension. Wall thickness is normal to slightly increased. Bowel loops follow a typical curvilinear path with distinct wall layering, but some areas display a prominent muscularis layer which does not display the typical 1:3 muscularis:mucosa layer ratio. Jejunum wall measures 0.18 cm. Visualized peristalsis appears appropriate. There are some focal areas of bowel in the mid abdomen that appear thickened up to 0.26 cm with reduced detail of wall layering. Large hypoechoic lymph nodes are visualized in this region.

The ileocecal junction was visualized and exhibited normal intact wall layering and is subjectively of normal thickness. Sections of colon are visualized with formed fecal material and gas shadowing distally. There is no observed focal or generalized colon wall thickening or loss of layering.

### ***Pancreas***

The pancreas is prominent and mottled (particularly in the left limb) compared to the surrounding isoechoic mesentery. There is no evidence of nodules or cystic lesions. There is no evidence of regional mesenteric inflammation or fluid.

### ***Free Abdomen***

Evaluation of the peritoneal cavity did not reveal any evidence of effusion. There is a diffuse mesenteric lymphadenopathy present with prominent lymph nodes at the ileocecal junction measuring 0.36 and 0.29 cm and mesenteric lymph nodes measuring 0.49 and 0.47 cm. In the region of the thickened bowel loops, there are larger more hypoechoic lymph nodes visualized measuring 0.63 cm and 0.54 cm. The omentum is of normal echogenicity.

## **PRIMARY FINDINGS**

- Prominent muscularis layer of the small intestine with focal bowel thickening with reduced detail of wall layering – The bowel wall thickening could be consistent with inflammation, edema, or infiltrative neoplasia.
- Moderate mesenteric lymphadenopathy – The prominent abdominal lymph nodes are most consistent with reactive lymphadenitis or lymphoid hyperplasia. Neoplastic infiltration is considered less likely.

## **SECONDARY FINDINGS**

- Prominent, mottled left limb of the pancreas – The pancreatic changes are most consistent with age-related parenchymal remodeling, potentially secondary to a prior inflammatory episode, early fibrosis or chronic pancreatitis.
- Prominent, tortuous bile duct – No evidence of an obstruction visualized.

## **INTERPRETATION OF THE FINDINGS & FURTHER RECOMMENDATIONS**

In general, the small bowel appears somewhat “ropey” with a prominent muscularis layer. In the mid abdomen, there are some more focal regions that appear more thickened with reduced detail of wall layering. These changes are concerning for focal enteritis/inflammatory change or could be consistent with early neoplastic change. There are prominent lymph nodes in this region. If a window for a fine needle aspirate of one of the larger mesenteric lymph nodes is available, consider a fine needle aspirate.

The left limb of the pancreas is somewhat prominent and mottled. Correlate with a quantitative fPLI level. If elevated, consider medical management for pancreatic inflammation.

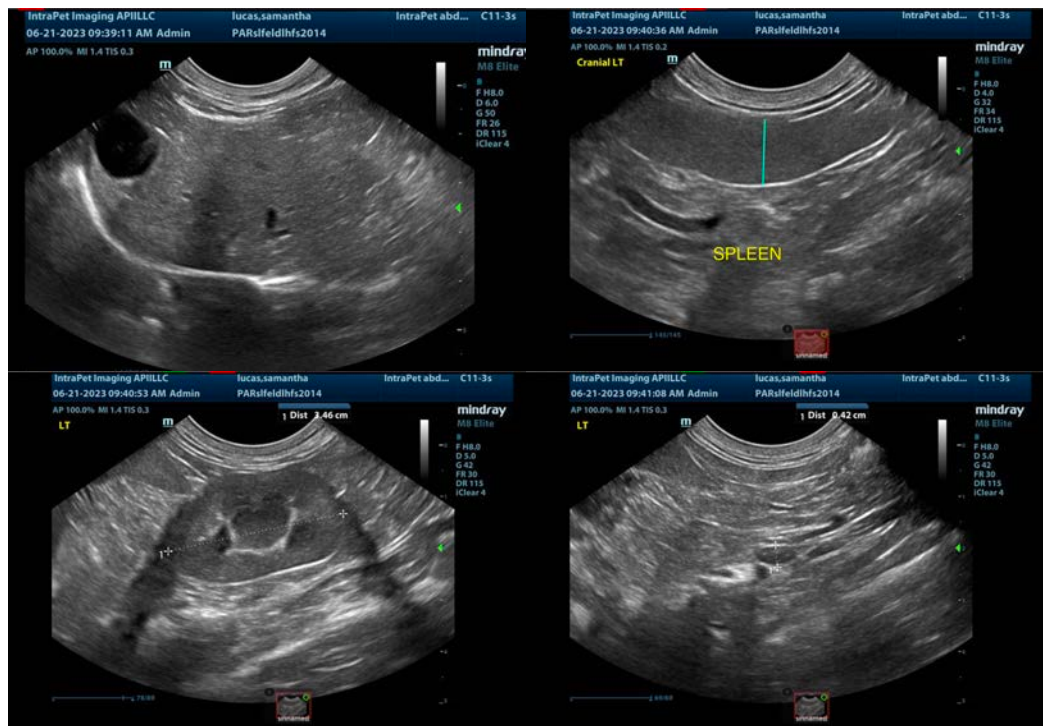
If not already done, consider the following steps for empirical management of diarrhea:

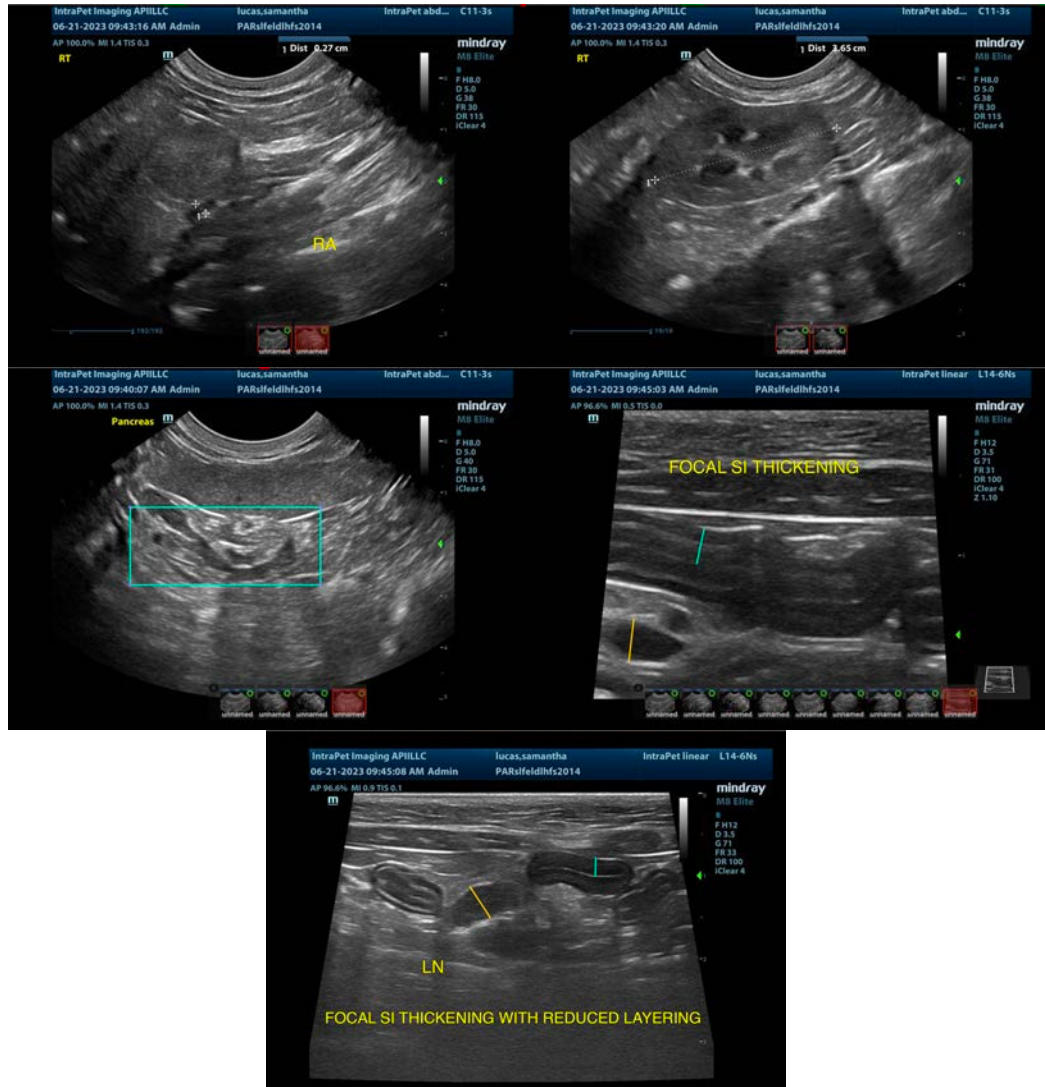
- Consider a novel protein/hydrolyzed protein diet (exclusively at least 4-6 weeks)
- Consider a GI panel to Texas A&M for evaluation of B12 levels, folate, PLI/TLI etc.. to further evaluate for pancreatic/small intestinal disease.
- Recommend chronic probiotic therapy.

In this situation, I would consider a fine needle aspirate of a mesenteric lymph node.

If symptoms are persistent, consider repeat imaging of the small bowel to look for possible progression of the previously described lesions. Surgical biopsies would likely be necessary to further evaluate the focally thickened bowel loops observed.

Recommend three view thoracic radiographs to evaluate for possible concurrent thoracic disease/involvement.





The information and recommendations provided are based on the images presented by the referring veterinarian/sonographer. No evaluation can be communicated regarding pathology that was not visible in the image/video clips provided.

Thank you for this referral. If the clinical or image interpretation does not parallel your findings or if I can be of any further assistance please contact me.

Kathleen Sennello DVM,MS, Diplomate ACVIM (Small animal Internal Medicine)  
 info@sonopath.com