

**DATE PRESENTING CLINICAL SIGNS**

6/21/23 Presents for elevated liver values on routine screening BW. Has lost 2 lb. in the last year, O has been working a little bit on weight loss, but not aggressively. Ran bile acids, pre and post samples very elevated (both >100). Otherwise, E/D well, no V/D, normal activity level.

PATIENT

Applejack Payne

Current Medications: Was on convenia + metronidazole 10mg/kg. Switched 6/19 to Zeniquin 2.75 mg/kg + Clavamox 13 mg/kg. Added in Denamarin.

SPECIES

Feline

Lab Results: On 6/9- ALT= 319, AST= 117, ALP= 185, TBil= 0.9, unconjugated (0.5) > conjugated (0.4), BUN and Alb well wnl. On 6/18 after 1 week of being on convenia/ metronidazole ALT= 232, AST= 68 ALP= 169, TBil= 0.7 (was not given conj vs unconj values). Bile acids Pre: 110.1, Post: 123.1.

Date of Previous IntraPet Ultrasound: No previous.

BREED

DSH

Sedation: Patient sedated with Dexdomitor & Torbugesic.

Stat Report: Not requested.

Imaging Performed By: Andi Parkinson, BS, RDMS.

SEX

Spayed Female

ULTRASONOGRAPHIC EXAMINATION OF THE ABDOMEN**Urinary System**

The urinary bladder is moderately distended with mild primarily suspended echogenic debris present. The Bladder wall, trigone, ureteral papillae and visible urethra (to a depth of 2cm) appear normal with no evidence of wall thickening, mucosal irregularities, masses or calculi. Echogenic debris of this type can be associated with small crystals, cellular debris and proteinaceous debris.

AGE

1/25/12

WEIGHT

10.9 Pounds

The left kidney has a normal shape and size (3.73 cm). Overall echogenicity is normal with adequate corticomedullary distinction and a typical 1:3 cortex:medulla ratio. There is no evidence of focal perinephric inflammation or effusion. There is no evidence of pyelectasia, nephroliths, infarcts or hydroureter. Renal vasculature is normal.

INTERPRETED BY

Kathleen Sennello DVM,
MS, Diplomate ACVIM
(Small Animal Internal
Medicine)

The right kidney has a normal shape and size (3.82 cm). Overall echogenicity is normal with adequate corticomedullary distinction and a typical 1:3 cortex:medulla ratio. There is no evidence of focal perinephric inflammation or effusion. There is no evidence of pyelectasia, nephroliths, infarcts or hydroureter. Renal vasculature is normal.

HOSPITAL NAME

Paradise AH

Adrenal Glands

The left adrenal gland is normal in size measuring 0.48 cm at the caudal pole. It is observed in its normal position cranial to the left renal artery. It is normal in appearance (uniformly hypoechoic) and shape with no evidence of a mass effect.

REFERRING VET

Dr. Halpern

The right adrenal gland is normal in size measuring 0.65 cm at the caudal pole. It is observed in its normal position between the cranial aspect of the right kidney and the caudal vena cava. It is normal in appearance (uniformly hypoechoic) and shape with no evidence of a mass effect.

INVOICE

43333

Spleen

The spleen is borderline large (1.2 cm), echotexture is homogenous, and the splenic capsule is smooth with no irregularities. The blood flow through the hilus and splenic parenchyma appears normal. No focal parenchymal abnormalities are visualized.

Liver

The liver is subjectively normal in size, and echogenicity with smooth peripheral margins. The parenchyma is heterogenous in echotexture with subtle, indistinct focal mottling. The visible portions of the vasculature and biliary tract appear normal. No focal nodules or cystic lesions are observed.

The gallbladder lumen is moderately distended. The wall of the gall bladder is not thickened and has a smooth mucosal surface. Luminal contents are mild and primarily anechoic. The cystic and common bile ducts are normal/not visible.

Gastrointestinal

The stomach contains minimal luminal contents. It measures at a normal thickness of <0.36cm with some variability due to the presence of rugal folds. The distinction of the gastric wall layers is adequate and there is no impression of reduced peristaltic activity. No masses or focal lesions were observed.

The visualized areas of duodenum, jejunum and ileum have a relatively uniform diameter with minimal fluid distension. Wall thickness is normal. Bowel loops follow a curvilinear path with distinct wall layering maintaining the typical 1:3 muscularis:mucosa layer ratio. Jejunum wall measures 0.19 cm. Visualized peristalsis appears appropriate. There were no focal lesions consistent with obstruction or a mass effect observed.

The ileocecal junction was visualized and exhibited normal intact wall layering and is subjectively of normal thickness. Sections of colon are visualized with formed fecal material and gas shadowing distally. There is no observed focal or generalized colon wall thickening or loss of layering.

Pancreas

The left limb of the pancreas is prominent and mottled compared to the surrounding isoechoic mesentery. There is no evidence of nodules or cystic lesions. There is no evidence of regional mesenteric inflammation or fluid.

Free Abdomen

Evaluation of the peritoneal cavity did not reveal any evidence of effusion. There is a diffuse mild lymphadenopathy present. There is a small cluster near the ileocecal junction with lymph nodes measuring 0.55 cm and 0.50 cm in diameter, a large portal lymph node measuring 0.87 cm, etc. The omentum is of normal echogenicity.

PRIMARY FINDINGS

- Borderline large spleen – This could be normal for a larger cat. No focal lesions are visualized. Possible differentials would include congestion or infiltrative disease.
- Prominent, mottled pancreas – The pancreatic changes are most consistent with age-related parenchymal remodeling, potentially secondary to a prior inflammatory episode, early fibrosis or chronic pancreatitis.
- Mildly heterogeneous liver – Hepatic changes are non-specific and could be consistent with inflammation/infection (cholangiohepatitis), infiltrative neoplasia, lipidosis or other hepatopathy.
- Diffuse mild mesenteric lymphadenopathy – The prominent abdominal lymph nodes are most consistent with reactive lymphadenitis or lymphoid hyperplasia. Neoplastic infiltration is considered less likely.

SECONDARY FINDINGS

- Echogenic debris in the urinary bladder – The echogenic debris in the bladder lumen could be consistent with cells, crystals, and/or mucus.

INTERPRETATION OF THE FINDINGS & FURTHER RECOMMENDATIONS

No focal lesions are visualized associated with the liver to explain the elevation in enzymes and bile acids reported. The gallbladder and biliary tract appear within normal limits. Provided there is no evidence of hemolysis or anemia, these findings would be consistent with a primary hepatopathy. Consider the following:

- Consider close evaluation of history for possible toxic changes examine medications, diet, dietary indiscretion etc.
- Recommend thyroid evaluation (if not already done)
- Consider screening for toxoplasmosis
- If not already done consider pre and post prandial bile acids to evaluate liver function
- Consider Fine needle aspirate if round cell neoplasia is on your differential list (25 g needle, normal coags)
- Consider liver biopsy with samples obtained for histopathology and culture
- If triaditis is suspected consider therapy for cholangiohepatitis, testing for pancreatitis and evaluation for IBD (GI panel to Texas A&M GI lab)
- Consider a feeding tube if patient is not eating for a prolonged period of time

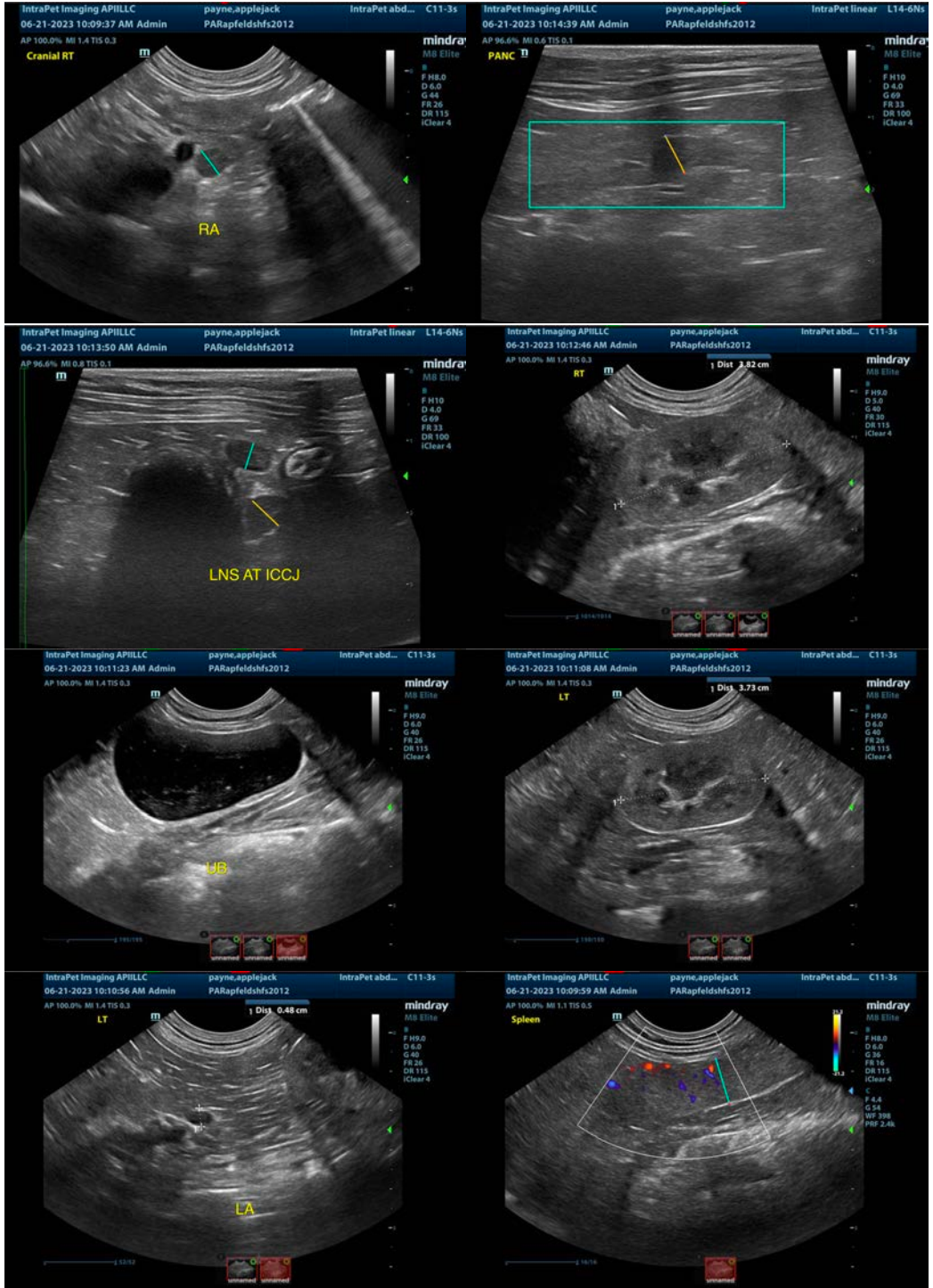
Given the severely elevated liver function test, I would strongly recommend sampling (fine needle aspirate +/- biopsy of the liver if values are not improving (provided coagulation parameters are normal).

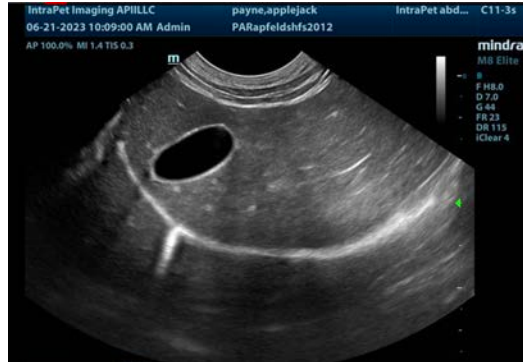There is some suspended echogenic debris visualized in the urinary bladder. Recommend a urinalysis and culture.

The spleen measures as slightly large. I suspect this is within normal limits for this individual. If round cell neoplasia is high on your differential list and a liver aspirate is not helpful, consider a fine needle aspirate of the spleen.

The changes observed in the pancreas are relatively mild and most consistent with previous episodes of pancreatic inflammation, although mild current inflammation cannot be ruled out. Correlate with a quantitative fPLI level.

Recommend three view thoracic radiographs to evaluate for possible concurrent thoracic disease/involvement.





The information and recommendations provided are based on the images presented by the referring veterinarian/sonographer. No evaluation can be communicated regarding pathology that was not visible in the image/video clips provided.

Thank you for this referral. If the clinical or image interpretation does not parallel your findings or if I can be of any further assistance please contact me.

Kathleen Sennello DVM,MS, Diplomate ACVIM (Small animal Internal Medicine)
info@sonopath.com