IMAGING PERFORMED BY

IntraPet.com

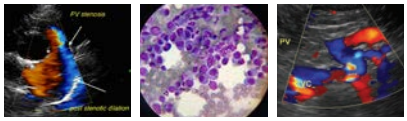

SonoPath
Clinical Sonography & Telecytology
EDUCATIONAL TELECONSULTATION SERVICES™
1-800-838-4268 info@sonopath.com SonoPath.com

DATE

6/21/22

PATIENT

Caster White

SPECIES

Canine

BREED

Greyhound

SEX

Neutered Male

AGE

1/1/12

WEIGHT

70.6 Pounds

INTERPRETED BY

Beth Johnson, DVM DACVIM

IMAGING PERFORMED BY

Kathleen Sennello DVM, MS, Diplomate ACVIM (Small Animal Internal Medicine)

HOSPITAL NAME

Creswell Vet Clinic

REFERRING VET

Dr. Cullum

INVOICE

38958

PRESENTING CLINICAL SIGNS

P was seen for a physical on 6/14/22 and O noted P has had low energy recently. Shortly after his vet appointment P has been refusing food and began having diarrhea.

Current Medications: 3cc Cerenia given 6/20/22, 50mg Tramadol BID-TID will be started this evening (6/20).
Radiographs: See attached.
Date of Previous IntraPet Ultrasound: No previous.
Sedation: Not required to complete full diagnostic ultrasound.
Stat Report: Declined.

ULTRASONOGRAPHIC EXAMINATION OF THE ABDOMEN

Urinary System

The urinary bladder is moderately distended with anechoic urine. The Bladder wall appears largely normal with a smooth mucosal surface and no evidence of wall thickening. In the apical portion, there is a small hyperechoic focal irregularity to the bladder wall measuring 0.34 cm x 0.46 cm, possibly consistent with a polypoid like lesion. The area of the trigone and ureteral papillae and proximal urethra (to a depth of 2cm) appear free of any mass lesions or calculi. Recommend urinalysis and culture and reevaluation of this lesion in 4-6 weeks.

The prostate is normal/borderline large at 1.48 cm.

The left kidney has a normal shape and size (7.51 cm). Overall echogenicity is normal with adequate corticomedullary distinction and a typical 1:3 cortex:medulla ratio. There is no evidence of perinephric inflammation or effusion. There is no evidence of pyelectasia, nephroliths, infarcts or hydroureter. Renal vasculature is normal.

The right kidney is large, measuring 9.4 cm in length, and is irregular in shape. It is of mixed echogenicity with very abnormal architecture, including several irregular cystic portions. The appearance of the right kidney could be consistent with a mass effect. There is no evidence of pyelectasia, obvious infarcts or hydroureter. Renal vasculature is normal.

Adrenal Glands

The left adrenal gland is normal in size measuring 0.72 cm at the caudal pole. It is observed in its normal position cranial to the left renal artery. It is normal in appearance (uniformly hypoechoic) and shape with no evidence of a mass effect.

A normal right adrenal gland is not clearly visualized. This is in part due to the abnormal right kidney and associated mass effect. Additionally, there is a heterogeneous, irregular, solid mass effect in the right cranial abdomen, measuring approximately 9.28 cm x 6.66 cm, which could be consistent with a right adrenal mass, pancreatic mass, hepatic mass, other.

Spleen

The spleen is large in size. The spleen echotexture is heterogenous and mottled, the splenic capsule is smooth with no irregularities. The blood flow through the hilus and splenic parenchyma appears normal. There is a hypoechoic nodule visualized measuring 1.47 cm x 1.08 cm near the head of the spleen.

Liver

The liver is subjectively normal in size, and echogenicity with smooth peripheral margins. The parenchyma is homogenous echotexture. The visible portions of the vasculature and biliary tract appear normal. No focal nodules or cystic lesions are observed.

The gallbladder lumen is moderately distended. The wall of the gall bladder is not thickened and has a smooth mucosal surface. Luminal contents are primarily anechoic. The cystic and common bile ducts are normal/not visible.

Gastrointestinal

The stomach contains minimal luminal contents. It measures at a normal thickness of <0.7cm with some variability due to the presence of rugal folds. The distinction of the gastric wall layers is adequate and there is no impression of reduced peristaltic activity. No masses or focal lesions were observed.

The visualized areas of duodenum, jejunum and ileum have a relatively uniform diameter with minimal fluid distension. Wall thickness is normal. Bowel loops follow a curvilinear path with distinct wall layering maintaining the typical 1:3 muscularis:mucosa layer ratio. The duodenum measured as normal (between 0.3-0.5cm in wall thickness) and the jejunum measured as normal (between 0.2-0.47cm.) Visualized peristalsis appears appropriate. There were no focal lesions consistent with obstruction or a mass effect observed.

The ileocecal junction was visualized and appeared somewhat abnormal. In the region of the ileocecal junction (mid cranial abdomen), there is a heterogeneous ovoid mass lesion measuring approximately 2.58 cm in diameter. In some views this appears associated with bowel wall, possibly colon(?). Additionally, this could be a lymph node in the region or a pancreatic mass.

Pancreas

The pancreas is large and hypoechoic to surrounding mesentery, particularly in the left limb. There is no evidence of nodules or cystic lesions. There is evidence of regional mesenteric inflammation. Consistent with moderate pancreatitis.

Free Abdomen

There is scant free abdominal fluid. There is no evidence of a diffuse lymphadenopathy, and the omentum is of increased echogenicity around the pancreas, right kidney and right abdominal mass.

Other

A brief view of the heart was submitted. No significant pericardial effusion was seen.

There were two abdominal mass lesions described above, which have uncertain origins. One is a heterogeneous, irregular mass lesion in the right cranial abdomen, suspicious for possibly a right adrenal mass or a pancreatic mass lesion. The other is a mid cranial abdominal smaller, heterogeneous, ovoid mass lesion, which is in proximity to the ileocecal junction and could involve bowel, pancreas, or be a lymph node.

ULTRASONOGRAPHIC FINDINGS

- Small hyperechoic focal irregularity in the urinary bladder wall – This could be consistent with a benign polypoid lesion or an early neoplastic lesion. Recommend urinalysis and culture and reevaluation in 4-6 weeks.

- Mottled spleen with hypoechioc nodule – The diffuse splenic changes are non-specific and could be consistent with lymphoid hyperplasia, extramedullary hematopoiesis, infiltrative neoplasia, inflammation, other. Cytology or histopathology would be necessary to get a definitive diagnosis. Recommend a fine needle aspirate of the splenic nodule.

- Hypoechoic, prominent pancreas surrounded by hyperechoic mesentery – The pancreatic changes are most consistent with moderate pancreatitis/pancreatic inflammation. Recommend fPLI testing and continued monitoring for improvement or possible development of a pancreatic abscess. Consider fine needle aspirate if not improving.

- Large, irregular, partially cystic right kidney – concerning for right kidney mass lesion. This could represent a benign or neoplastic lesion.

- Heterogeneous ovoid mid cranial mass lesion – This lesion appears in the region of the ileocecal junction and pancreas. Alternately, it could be an effaced lymph node. Recommend fine needle aspirate.

- Large irregular heterogeneous right cranial abdominal mass (9.28 cm x 6.66 cm) – suspicious for a right adrenal mass lesion or a hepatic/pancreatic lesion. Recommend a fine needle aspirate.

INTERPRETATION OF THE FINDINGS & FURTHER RECOMMENDATIONS

There are numerous lesions present within the abdomen. Unfortunately, there is concern that some of these appear somewhat aggressive in nature and are involving important structure. Initial steps should focus on cytologic sampling. Recommend a fine needle aspirate of the splenic nodule, right cranial abdominal mass lesion, right kidney, and, if possible, the mid cranial mass lesion. Additionally, recommend 3-view thoracic radiographs.

If a cytologic diagnosis can be obtained in some of these areas, you could consider a contrast CT scan to further evaluate for surgical options (if no evidence of metastatic disease), or you could consider consultation with ha veterinary oncologist regarding prognosis and treatment options. Due to the appearance and location of several of these lesions, there is concern for an underlying neoplastic condition.

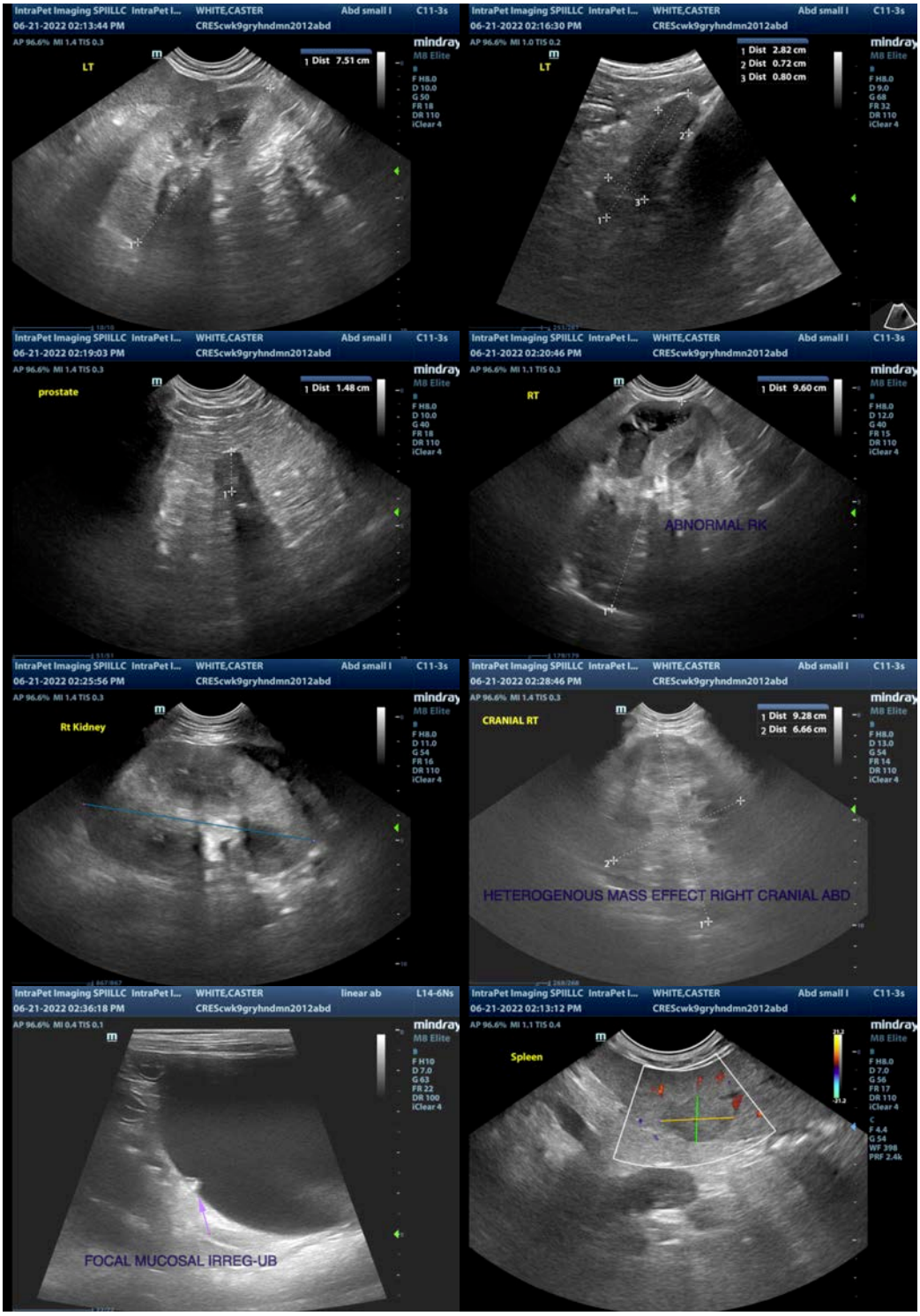
IntraPet Imaging SPIILLC IntraPet I... WHITE,CASTER Abd small I C11-3s
06-21-2022 02:13:44 PM CREScwk9gryhndmn2012abd
LT
1 Dist 7.51 cm
IntraPet Imaging SPIILLC IntraPet I... WHITE,CASTER Abd small I C11-3s
06-21-2022 02:16:30 PM CREScwk9gryhndmn2012abd
LT
1 Dist 2.82 cm
2 Dist 0.72 cm
3 Dist 0.80 cm
IntraPet Imaging SPIILLC IntraPet I... WHITE,CASTER Abd small I C11-3s
06-21-2022 02:19:03 PM CREScwk9gryhndmn2012abd
prostate
1 Dist 1.48 cm
IntraPet Imaging SPIILLC IntraPet I... WHITE,CASTER Abd small I C11-3s
06-21-2022 02:20:46 PM CREScwk9gryhndmn2012abd
RT
1 Dist 9.60 cm
ABNORMAL RK
IntraPet Imaging SPIILLC IntraPet I... WHITE,CASTER Abd small I C11-3s
06-21-2022 02:25:56 PM CREScwk9gryhndmn2012abd
Rt Kidney
IntraPet Imaging SPIILLC IntraPet I... WHITE,CASTER Abd small I C11-3s
06-21-2022 02:28:46 PM CREScwk9gryhndmn2012abd
CRANIAL RT
1 Dist 9.28 cm
2 Dist 6.66 cm
HETEROGENOUS MASS EFFECT RIGHT CRANIAL ABD
IntraPet Imaging SPIILLC IntraPet I... WHITE,CASTER linear ab L14-6Ns
06-21-2022 02:36:18 PM CREScwk9gryhndmn2012abd
FOCAL MUCOSAL IRREG-UB
IntraPet Imaging SPIILLC IntraPet I... WHITE,CASTER Abd small I C11-3s
06-21-2022 02:13:12 PM CREScwk9gryhndmn2012abd
Spleen

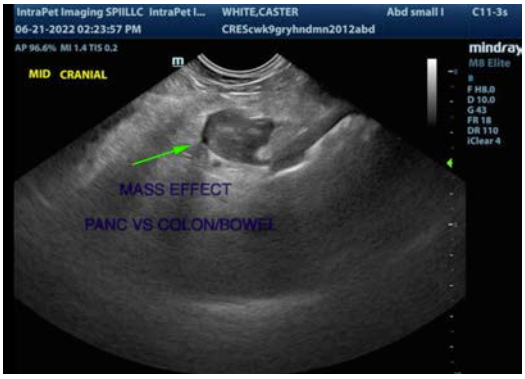

The information and recommendations provided are based on the images presented by the referring veterinarian/sonographer. No evaluation can be communicated regarding pathology that was not visible in the image/video clips provided.

Thank you for this referral. If the clinical or image interpretation does not parallel your findings or if I can be of any further assistance please contact me.

Kathleen Sennello DVM,MS, Diplomate ACVIM (Small animal Internal Medicine)
kathleen.sennello@sonopath.com