

IMAGING PERFORMED BY

IntraPet.com



SonoPath

Clinical Sonography & Telecytology

EDUCATIONAL TELECONSULTATION SERVICES™

1-800-838-4268 info@sonopath.com SonoPath.com

DATE PRESENTING CLINICAL SIGNS

6/21/22

Presented to rdvm for dental: - was noted to have lost 10# over the past year - BW: HCT 34.3%, ALP 571, GGT 47, Glob 5, TP 8.3, K 6 - UA: USG 1.018, pH 7 - Rads: - When induced with propofol, gums turned white and HR dropped - did not perform dental - Expressed concerns for potential splenic mass - Hx of CKD

PATIENT

Ace Shindle

Current Medications: Cerenia.
Lab Results: See attached.

SPECIES

Canine

Date of Previous IntraPet Ultrasound: No previous.
Sedation: Not required to complete full diagnostic ultrasound.
Stat Report: Not requested.

BREED

Pit Bull x

SEX

Neutered Male

AGE

6/20/07

WEIGHT

55.8 Pounds

INTERPRETED BY

Kathleen Sennello DVM,
MS, Diplomate ACVIM
(Small Animal Internal
Medicine)

IMAGING PERFORMED BY

Rachel Brilhart RDMS

HOSPITAL NAME

Animal Emergency
Hospital

REFERRING VET

Dr. Nacke-Horney

INVOICE

38939

ULTRASONOGRAPHIC EXAMINATION OF THE ABDOMEN

Urinary System

The urinary bladder is moderately distended with anechoic urine. The Bladder wall, trigone, ureteral papillae and visible urethra (to a depth of 2cm) appear normal with no evidence of wall thickening, mucosal irregularities, masses or cystic calculi.

The visualized areas of prostate and surrounding tissue appear normal. Unfortunately, the prostate is not fully visualized likely due to its intrapelvic location. Correlate with rectal exam findings.

The left kidney has a normal shape and size (6.53 cm) with mild pyelectasia at 0.23 cm. Overall echogenicity is slightly hyperechoic with poor corticomedullary distinction and a typical 1:3 cortex:medulla ratio. There is no evidence of perinephric inflammation or effusion. There is no evidence of nephroliths, infarcts or hydronephrosis. Renal vasculature is normal.

The right kidney is large, measuring 7.37 cm. It appears partially hydronephrotic with a renal pelvis measuring 1.78 cm in diameter. Additionally, there is a hypoechoic focal area in the cortex, concerning for a possible nodule, measuring 1.12 cm.

Adrenal Glands

The left adrenal gland is large in size measuring 1.35 cm at the cranial pole, 1.86 cm at the caudal pole, and 3.97 cm in length. It is observed in its normal position cranial to the left renal artery. It is abnormal in appearance in that it is generally enlarged. There is no obvious vascular invasion observed.

The right adrenal gland is severely enlarged in size and irregular, measuring approximately 7.84 cm x 4.98 cm and is located medial to the right kidney, but appears expansile. No overt vascular invasion is noted, but there is strong concern for this possibility. Findings are concerning for a large right adrenal mass.

Spleen

The spleen is subjectively normal in size, echotexture is homogenous, and the splenic capsule is smooth with no irregularities. The blood flow through the hilus and splenic parenchyma appears normal. No focal parenchymal abnormalities are visualized.

Liver

The liver is large in size and irregular. The parenchyma is heterogenous in echotexture with subtle, indistinct focal mottling. The visible portions of the vasculature and biliary tract appear normal. There are too numerous to count discrete hypoechoic nodules throughout the hepatic parenchyma, concerning for possible metastatic disease, although benign nodules are possible.

The gallbladder lumen is moderately distended. The wall of the gall bladder is not thickened and has a smooth mucosal surface. Luminal contents are primarily anechoic. The cystic and common bile ducts are normal/not visible.

Gastrointestinal

The stomach contains minimal luminal contents. It measures at a normal thickness of <0.7cm with some variability due to the presence of rugal folds. The distinction of the gastric wall layers is adequate and there is no impression of reduced peristaltic activity. No masses or focal lesions were observed.

The visualized areas of duodenum, jejunum and ileum have a relatively uniform diameter with minimal fluid distension. Wall thickness is normal. Bowel loops follow a curvilinear path with distinct wall layering maintaining the typical 1:3 muscularis:mucosa layer ratio. The duodenum measured as normal (between 0.3-0.5cm in wall thickness) and the jejunum measured as normal (between 0.2-0.47cm.) Visualized peristalsis appears appropriate. There were no focal lesions consistent with obstruction or a mass effect observed.

The ileocecal junction was visualized and exhibited normal intact wall layering and is subjectively of normal thickness. Sections of colon are visualized with formed fecal material and gas shadowing distally. There is no observed focal or generalized colon wall thickening or loss of layering.

Pancreas

The pancreas is normal and isoechoic to surrounding mesentery. There is no evidence of nodules or cystic lesions. There is no evidence of regional mesenteric inflammation or fluid.

Free Abdomen

Evaluation of the peritoneal cavity did not reveal any evidence of effusion, or subjective lymphadenomegaly. The Medial iliac nodes appear normal and there was no evidence of a caudal aortic thrombus at the bifurcation. The omentum is of normal uniform echogenicity.

ULTRASONOGRAPHIC FINDINGS

- Large, irregular right adrenal mass with concern for possible vascular invasion or impingement on local vasculature – Right adrenomegaly could be consistent with neoplasia (e.g., adenoma, carcinoma, pheochromocytoma), hyperplasia, inflammation, other.
- Large left adrenal gland – This adrenal gland is large, but appears much more normal in shape and appearance. This could be consistent with hyperplasia, PDH, or metastatic disease.
- Diffusely nodular liver – The nodules are distinct and too numerous to count. There is concern for possible metastatic neoplasia. Recommend a fine needle aspirate of the liver.
- Hydronephrotic right kidney with a small hypoechoic lesion/nodule – I suspect this is secondary to impingement on the ureter from the right adrenal mass and possible metastatic disease.

INTERPRETATION OF THE FINDINGS & FURTHER RECOMMENDATIONS

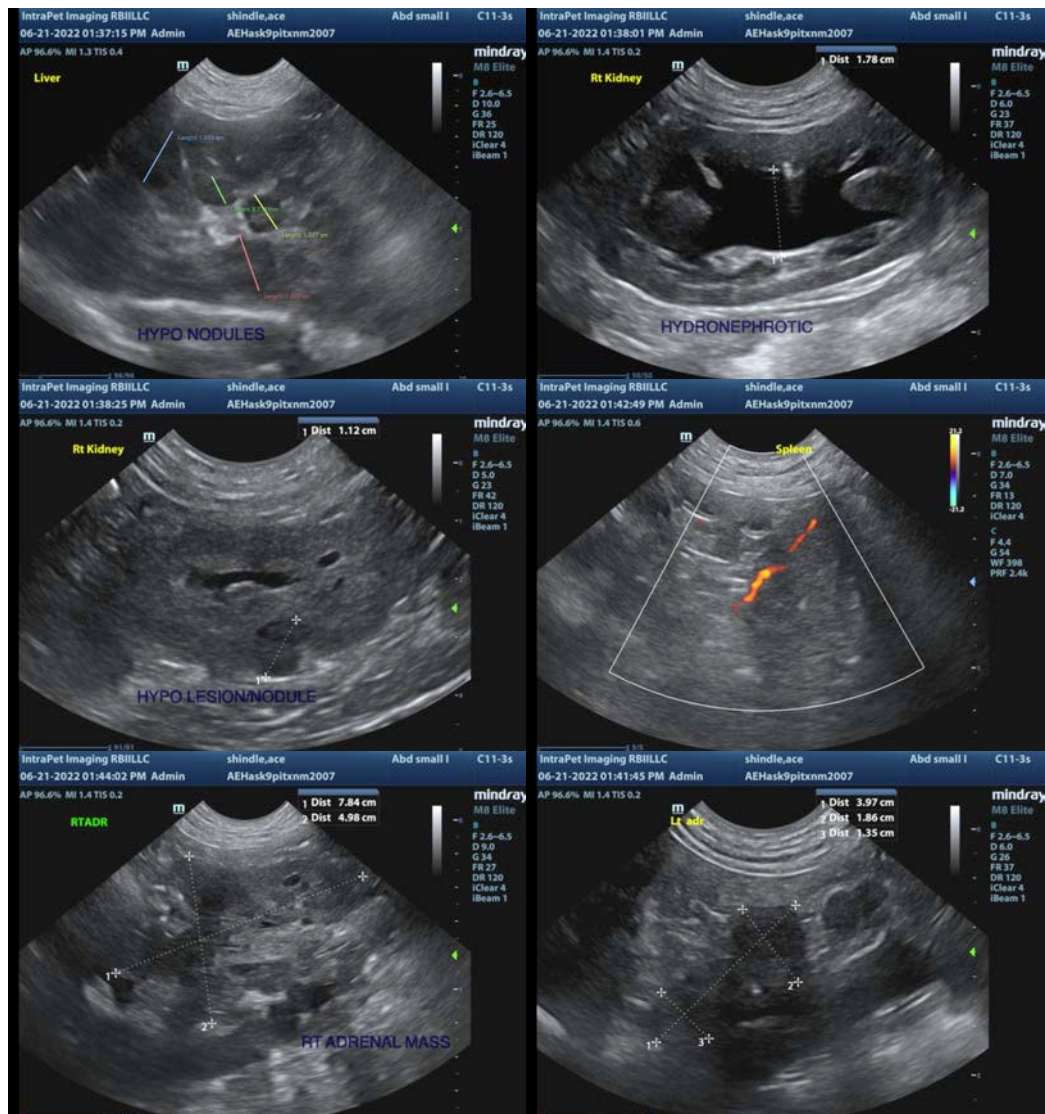
The results of today's scan are concerning, because there is a large right-sided adrenal mass that appears irregular, expansile, and likely invasive. There is associated early hydronephrosis of the right kidney. Recommend a contrast CT scan to better evaluate invasiveness of this lesion and the feasibility of surgical intervention. Prior to doing this, I would recommend a fine needle aspirate of the liver to try and determine if the nodules within the parenchyma recommended metastatic disease.

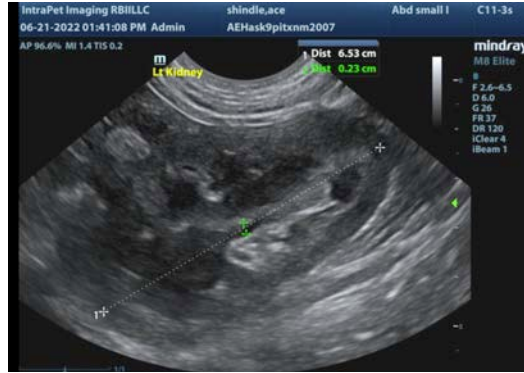
Consider three view thoracic radiographs to rule out concurrent thoracic disease/involvement.

Additionally, recommend a blood pressure evaluation, as some of your anesthetic complications could be due to a pheochromocytoma (or may be unrelated).

The left adrenal gland is large as well, but appears much more typical of a benign enlargement, but metastatic disease cannot be excluded as a possibility.

Recommend urinalysis and culture.





The information and recommendations provided are based on the images presented by the referring veterinarian/sonographer. No evaluation can be communicated regarding pathology that was not visible in the image/video clips provided.

Thank you for this referral. If the clinical or image interpretation does not parallel your findings or if I can be of any further assistance please contact me.

Kathleen Sennello DVM,MS, Diplomate ACVIM (Small animal Internal Medicine)
kathleen.sennello@sonopath.com