

PATIENT PRESENTING CLINICAL SIGNS

Scooter Dwyer

Presented with inability to walk, urinate or defecate. Swollen abdomen. Still eating. On PE, tense abdomen, cranial organomegaly, ambulatory x 4, positive cps, mild ataxia. Platlets 82, lymph 525; phos 7.7; ca 12.0; TP high, AST 100, ALP 269; Tbili 0.4; conj bili 0.4. On Methocarbamol, Gabapentin. Hepatomegaly on radiographs.

SPECIES

Canine

ULTRASONOGRAPHIC EXAMINATION OF THE ABDOMEN

BREED

Urinary System

Mixed

The urinary bladder is moderately distended with anechoic urine. The Bladder wall, trigone, ureteral papillae and visible urethra (to a depth of 2cm) appear normal with no evidence of wall thickening, mucosal irregularities, or masses. There is a small pinpoint shadowing mineralization in the dependent portion of the urinary bladder measuring 0.22 cm, consistent with a very small pile of sandy debris or a small stone.

SEX

Spayed Female

The left kidney has a normal shape and size (4.61 cm) with mild pyelectasia at 0.20 cm. Overall echogenicity is normal with adequate corticomedullary distinction and a typical 1:3 cortex:medulla ratio. There is no evidence of perinephric inflammation or effusion. There is no evidence of nephroliths, infarcts or hydroureter. Renal vasculature is normal.

AGE

12 Years

The right kidney has a normal shape and size (4.4 cm). Overall echogenicity is normal with adequate corticomedullary distinction and a typical 1:3 cortex:medulla ratio. There is no evidence of perinephric inflammation or effusion. There is no evidence of pyelectasia, nephroliths, infarcts or hydroureter. Renal vasculature is normal.

WEIGHT

17.9 Pounds

Adrenal Glands

INTERPRETED BY

Kathleen Sennello DVM, MS, Diplomate ACVIM (Small Animal Internal Medicine)

The left adrenal gland is normal in size measuring 0.65 cm at the caudal pole. It is observed in its normal position cranial to the left renal artery. It is normal in appearance (uniformly hypoechoic) and shape with no evidence of a mass effect.

The right adrenal gland is normal in size measuring 0.61 cm at the caudal pole. It is observed in its normal position between the cranial aspect of the right kidney and the caudal vena cava. It is normal in appearance (uniformly hypoechoic) and shape with no evidence of a mass effect.

IMAGING PERFORMED BY

Pamela Harrigan, RDMS

Spleen

The spleen is subjectively normal in size, echotexture is homogenous, and the splenic capsule is smooth with no irregularities. The blood flow through the hilus and splenic parenchyma appears normal. No focal parenchymal abnormalities are visualized.

HOSPITAL NAME

Norfolk County VS

Liver

The liver is subjectively normal in size, and echogenicity with smooth peripheral margins. The parenchyma is heterogenous in echotexture with subtle, indistinct focal mottling. The visible portions of the vasculature and biliary tract appear normal. No focal nodules or cystic lesions are observed.

REFERRING VET

Dr. Emily McCabe

The gall bladder lumen is significantly distended. Some areas of the wall appear mildly thickened with adherent debris. There is a large amount of primarily non-organized echogenic debris. There is no evidence of bile duct dilation. These changes can be consistent with an early gall bladder mucocele.

INVOICE

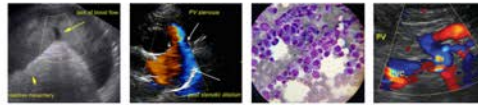
38341

Gastrointestinal

DATE

6/2/22

The stomach is moderately dilated with fluid and irregular shadowing material most consistent with normal ingesta and gas. It measures at a normal thickness of <0.7cm with some variability due to the



PATIENT

Scooter Dwyer

presence of rugal folds. The distinction of the gastric wall layering is adequate and there is no impression of reduced peristaltic activity. No masses or focal lesions were observed.

SPECIES

Canine

The visualized areas of duodenum, jejunum and ileum have a relatively uniform diameter with minimal fluid distension. Wall thickness is normal. Bowel loops follow a curvilinear path with distinct wall layering maintaining the typical 1:3 muscularis:mucosa layer ratio. Duodenum wall measured 0.48 cm. Jejunum wall measured 0.37 cm. Visualized peristalsis appears appropriate. There were no focal lesions consistent with obstruction or a mass effect observed.

BREED

Mixed

The ileocecal junction was visualized and exhibited normal intact wall layering and is subjectively of normal thickness. Sections of colon are visualized with formed fecal material and gas shadowing distally. There is no observed focal or generalized colon wall thickening or loss of layering.

SEX

Spayed Female

Pancreas

The pancreas is normal and isoechoic to surrounding mesentery. There is no evidence of nodules or cystic lesions. There is no evidence of regional mesenteric inflammation or fluid.

AGE

12 Years

Free Abdomen

Evaluation of the peritoneal cavity did not reveal any evidence of effusion, or subjective lymphadenomegaly. The Medial iliac nodes appear normal. The omentum is of normal uniform echogenicity.

WEIGHT

17.9 Pounds

PRIMARY FINDINGS

- Pinpoint mineralization in the urinary bladder – most consistent with a small stone or sandy debris. Recommend urinalysis and culture.
- Mildly heterogeneous liver – The diffuse hepatic changes are non-specific and could be consistent with vacuolar hepatopathy, nodular hyperplasia, inflammatory/immune-mediated disease, fibrosis, extramedullary hematopoiesis, toxic hepatopathy (e.g., copper), infiltrative neoplasia (less likely) or other hepatopathy.
- Large gallbladder debris – There is a large amount debris visualized in the gallbladder with no evidence of significant wall thickening or inflammation. Recommend continued monitoring. Consider starting Ursodiol if liver enzyme elevations are present.
- Moderate ingesta visualized within the gastric lumen – correlate with feeding history. If the patient was adequately fasted, consider such differentials as delayed gastric emptying or partial outflow tract obstruction (none observed).

INTERPRETED BY

Kathleen Sennello DVM,
MS, Diplomate ACVIM
(Small Animal Internal
Medicine)

IMAGING PERFORMED BY

Pamela Harrigan, RDCS

HOSPITAL NAME

Norfolk County VS

SECONDARY FINDINGS

- Mild left-sided pyelectasia – This is very mild and likely clinically insignificant. Consider urinalysis and culture.

REFERRING VET

Dr. Emily McCabe

INTERPRETATION OF THE FINDINGS & FURTHER RECOMMENDATIONS

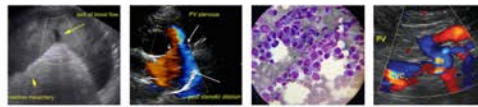
The abnormalities reported on today's scan were very mild and largely non-specific. The gallbladder has a moderate amount of debris, but no obvious inflammation or wall thickening. Continued monitoring is warranted +/- Ursodiol therapy. I do not see a physical obstruction to explain an inability to urinate or defecate. Recommend digital rectal exam of both the urethra and the rectum, including sublumbal lymph nodes, etc. Consider consultation with a veterinary neurologist if a neurologic problem is suspected.

INVOICE

38341

DATE

6/2/22



PATIENT

Scooter Dwyer

SPECIES

Canine

BREED

Mixed

SEX

Spayed Female

AGE

12 Years

WEIGHT

17.9 Pounds

INTERPRETED BY

Kathleen Sennello DVM,
 MS, Diplomate ACVIM
 (Small Animal Internal
 Medicine)

IMAGING PERFORMED BY

Pamela Harrigan, RDCS

HOSPITAL NAME

Norfolk County VS

REFERRING VET

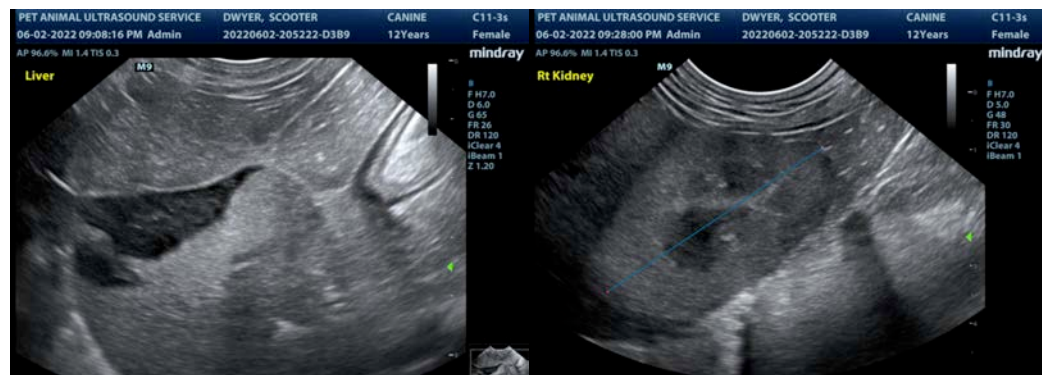
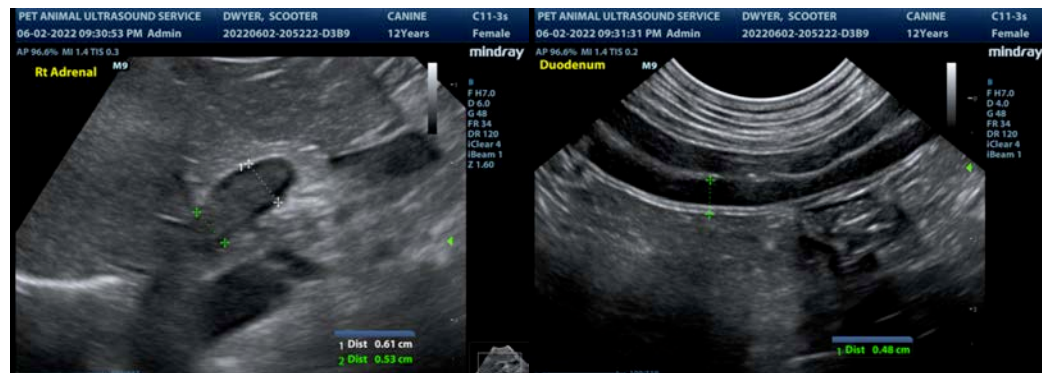
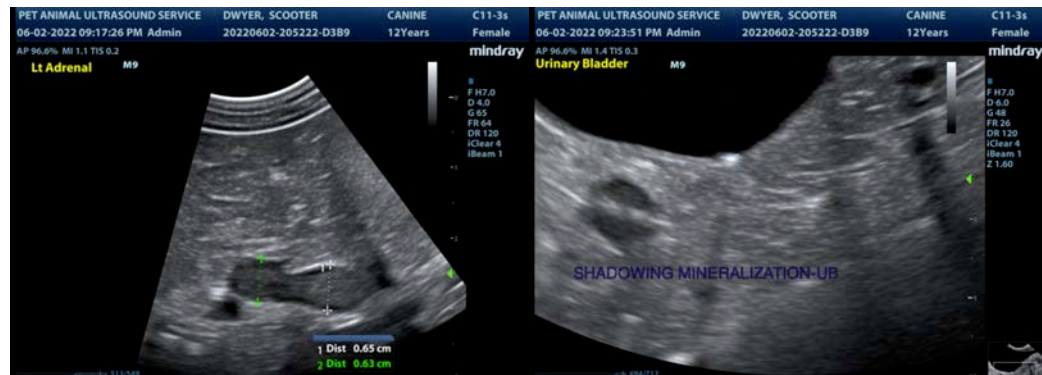
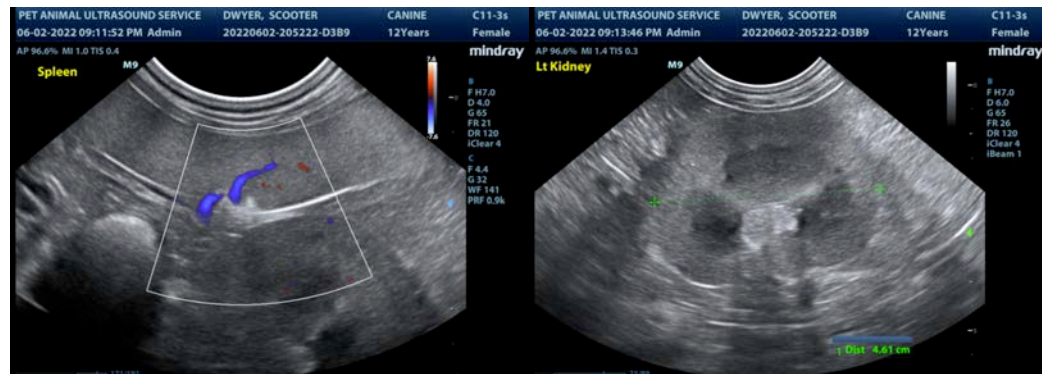
Dr. Emily McCabe

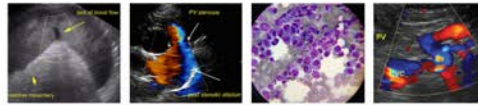
INVOICE

38341

DATE

6/2/22





PATIENT

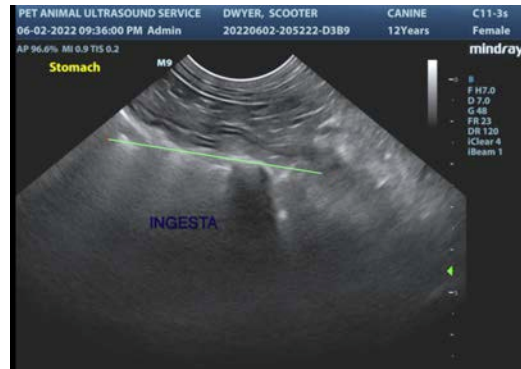
Scooter Dwyer

SPECIES

Canine

BREED

Mixed



SEX

Spayed Female

The information and recommendations provided are based on the images presented by the referring veterinarian/sonographer. No evaluation can be communicated regarding pathology that was not visible in the image/video clips provided.

AGE

12 Years

Thank you for this referral. If the clinical or image interpretation does not parallel your findings or if I can be of any further assistance please contact me.

Kathleen Sennello DVM,MS, Diplomate ACVIM (Small animal Internal Medicine)

kathleen.sennello@sonopath.com

WEIGHT

17.9 Pounds

INTERPRETED BY

Kathleen Sennello DVM,
 MS, Diplomate ACVIM
 (Small Animal Internal
 Medicine)

IMAGING PERFORMED BY

Pamela Harrigan, RDMS

HOSPITAL NAME

Norfolk County VS

REFERRING VET

Dr. Emily McCabe

INVOICE

38341

DATE

6/2/22