

PATIENT

Hugho Dillon

PRESENTING CLINICAL SIGNS

SPECIES

Canine

BREED

Mini Schnauzer

Chief Concern/Provisional Diagnosis: P has diarrhea, decreased appetite, vomiting, lethargic. Diagnosis: ddx: microhepatica History/Physical Findings: BAR, obese BCS: 9/9, abdomen is rounded and tense. Summary of Laboratory Abnormalities: BW ran on 6/1/2022: ALT elevated at 568, ALK phos elevated at 1045, globulin elevated at 4.0, neutrophils elevated at 92, lymphocytes decreased at 4, monocytes decreased at 2, all other values WNL. Radiographic Abnormalities: abdominal radiographs revealed what appears to be microhepatica. Current Therapy and Medications: Cerenia (10 mg/ ml) 0.4 ml SQ given 6/1/2022, liquitinic 5 ml PO BID, metronidazole 250 mg: ½ tab PO BID

ULTRASONOGRAPHIC EXAMINATION OF THE ABDOMEN

SEX

Neutered Male

Urinary System

The urinary bladder is moderately distended with anechoic urine. The Bladder wall, trigone, ureteral papillae and visible urethra (to a depth of 2cm) appear normal with no evidence of wall thickening, mucosal irregularities, masses or cystic calculi.

AGE

7 Years

The prostate is normal in size (0.95 cm) and shape for this neutered male dog. The parenchyma is homogenous and the external margins are smooth. The prostatic urethra appears normal with no evidence of irregularity, invasion, mass effect or calculi.

WEIGHT

41.6 Pounds

The left kidney has a normal shape and size (7.56 cm). Overall echogenicity is normal with adequate corticomedullary distinction and a typical 1:3 cortex:medulla ratio. There is no evidence of perinephric inflammation or effusion. There is no evidence of pyelectasia, nephroliths, infarcts or hydroureter. Renal vasculature is normal.

INTERPRETED BY

Kathleen Sennello DVM,
MS, Diplomate ACVIM
(Small Animal Internal
Medicine)

The right kidney has a normal shape and size (5.81 cm). Overall echogenicity is normal with adequate corticomedullary distinction and a typical 1:3 cortex:medulla ratio. There is no evidence of perinephric inflammation or effusion. There is no evidence of pyelectasia, nephroliths, infarcts or hydroureter. Renal vasculature is normal.

IMAGING BY

Loetitia Saint-Jacques,
LVT

Adrenal Glands

The left adrenal gland is normal in size measuring 0.66 cm at the caudal pole. It is observed in its normal position cranial to the left renal artery. It is normal in appearance (uniformly hypoechoic) and shape with no evidence of a mass effect.

HOSPITAL NAME

Valley Vet Clinic

The right adrenal gland is normal in size measuring 0.64 cm at the caudal pole. It is observed in its normal position between the cranial aspect of the right kidney and the caudal vena cava. It is normal in appearance (uniformly hypoechoic) and shape with no evidence of a mass effect.

REFERRING VET

Dr. Megan Plateman

Spleen

The spleen is subjectively normal in size, echotexture is homogenous, and the splenic capsule is smooth with no irregularities. The blood flow through the hilus and splenic parenchyma appears normal. No focal parenchymal abnormalities are visualized.

Liver

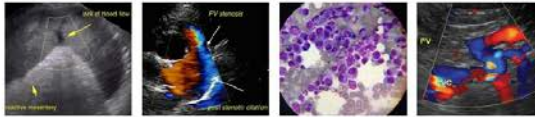
The liver is subjectively normal in size, and echogenicity with smooth peripheral margins. The parenchyma is heterogenous in echotexture with subtle, indistinct focal mottling. The visible

INVOICE

38355

DATE

6/2/22



PATIENT

Hugho Dillon

SPECIES

Canine

BREED

Mini Schnauzer

SEX

Neutered Male

AGE

7 Years

WEIGHT

41.6 Pounds

INTERPRETED BY

Kathleen Sennello DVM,
MS, Diplomate ACVIM
(Small Animal Internal
Medicine)

IMAGING BY

Loetitia Saint-Jacques,
LVT

HOSPITAL NAME

Valley Vet Clinic

REFERRING VET

Dr. Megan Plateman

INVOICE

38355

DATE

6/2/22

portions of the vasculature and biliary tract appear normal. The liver appears normal in size, but some atypical in that there is hyperechoic tissue between liver lobes, almost consistent with fat, possible lipoma(?). Hepatic tissue appears adequate in volume, and the caudate lobe touches the right kidney.

The gall bladder lumen is moderately distended. The wall of the gall bladder has irregular polypoid projections and there is a moderate amount of non-organized echogenic debris. The cystic and common bile ducts are normal/not visible.

Gastrointestinal

The stomach contains minimal luminal contents. It measures at a normal thickness of <0.7cm with some variability due to the presence of rugal folds. The distinction of the gastric wall layers is adequate and there is no impression of reduced peristaltic activity. No masses or focal lesions were observed.

The visualized areas of duodenum, jejunum and ileum have a relatively uniform diameter with minimal fluid distension. Wall thickness is normal. Bowel loops follow a curvilinear path with distinct wall layering maintaining the typical 1:3 muscularis:mucosa layer ratio. The duodenum measured as normal (between 0.3-0.5cm in wall thickness) and the jejunum measured as normal (between 0.2-0.47cm.) Visualized peristalsis appears appropriate. There were no focal lesions consistent with obstruction or a mass effect observed.

The ileocecal junction was visualized and exhibited normal intact wall layering and is subjectively of normal thickness. Sections of colon are visualized with formed fecal material and gas shadowing distally. There is no observed focal or generalized colon wall thickening or loss of layering.

Pancreas

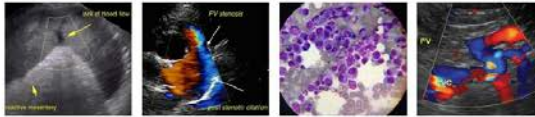
The pancreas is large and hypoechoic to surrounding mesentery. Consistent with mild/moderate pancreatitis. There are several small cystic structures visualized in the region of the pancreas, forming a cluster, measuring approximately 1.2 cm in size. These lesions appear to be filled with anechoic fluid. There is some regional mesenteric inflammation, but no free fluid visualized. The tip of the liver lobe is also in this area, and in some views the cystic lesions could appear to be hepatic in origin.

Free Abdomen

Evaluation of the peritoneal cavity did not reveal any evidence of effusion, or subjective lymphadenomegaly. The Medial iliac nodes appear normal and there was no evidence of a caudal aortic thrombus at the bifurcation. The omentum is of normal uniform echogenicity.

ULTRASONOGRAPHIC FINDINGS

- Hypoechoic, prominent pancreas with surrounding hyperechoic mesentery and possible cystic structures – The pancreatic changes are most consistent with mild to moderate pancreatitis/pancreatic inflammation. Recommend fPLI testing and continued monitoring for improvement or possible development of a pancreatic abscess. Consider fine needle aspirate if not improving.
- Heterogeneous liver – The diffuse hepatic changes are non-specific and could be consistent with vacuolar hepatopathy, nodular hyperplasia, inflammatory/immune-mediated disease,



PATIENT

Hugho Dillon

fibrosis, extramedullary hematopoiesis, toxic hepatopathy (e.g., copper), infiltrative neoplasia (less likely) or other hepatopathy.

SPECIES

Canine

- Gallbladder polyps – The significance of the gall bladder polyps and debris is unclear. This could represent an early mucocele, cholestasis, or chronic inflammation, or could be an incidental finding.

BREED

Mini Schnauzer

INTERPRETATION OF THE FINDINGS & FURTHER RECOMMENDATIONS

The pancreas appears prominent and hypoechoic compared to surrounding mesentery. This is particularly true in the right limb caudal to the stomach and in the area of the duodenum. Additionally, there are some cystic lesions in this region. It is difficult to distinguish if these cystic lesions are associated with the pancreas or the liver. They appear relatively anechoic and should be monitored. If there is concern that they are changing, you could consider a fine needle aspirate or drainage of these cystic lesions. Recommend evaluation of quantitative PLI and treatment for pancreatitis. If this patient is not responding to therapy, then consider a fine needle aspirate of the pancreas, as it does appear prominent and “meaty” in echotexture.

SEX

Neutered Male

AGE

7 Years

The liver parenchyma appears adequate in volume. There appears to be a large amount of fat echogenicity tissue in the area of the liver and amongst the liver lobes, most consistent with omental fat. Historically, radiographs have been an excellent way to determine liver size (except in very deep chested dogs), so I am unsure of the significance of these finding. Recommend evaluation of the liver in both views on radiographs in case intraabdominal fat is shifting the lobes or stomach axis(?).

WEIGHT

41.6 Pounds

No focal lesions are visualized associated with the liver. These are my recommendations for evaluation of a dog with an elevated ALP and relatively normal sized adrenals.

INTERPRETED BY

Kathleen Sennello DVM,
MS, Diplomate ACVIM
(Small Animal Internal
Medicine)

- Induction phenomena are the most common cause for an elevation in ALP. These are systemic illnesses that 'turn on' the liver enzyme. Causes of this include Cushing's disease, dental disease, arthritis, and numerous others. In many cases the exact cause is unclear but as long as ultrasound and bile acids tests are normal most patients do not have progressive changes in their liver. While liver biopsy is not routinely performed, vacuolar hepatopathy, is noted on most biopsies. This is often non-progressive but in rare cases can be more severe and lead to liver failure.

IMAGING BY

Loetitia Saint-Jacques,
LVT

- If signs of cushings disease are present recommend endocrine function testing to evaluate for cushings disease.

HOSPITAL NAME

Valley Vet Clinic

- Consider fine needle aspirate to rule out round cell neoplasia -if this is a concern.

REFERRING VET

Dr. Megan Plateman

- If a cause for the ALP elevation is not identified: I recommend recheck general blood work every 6 months, ultrasound once per year, and bile acids test every 1-2 years based on other results. If the ALP continues to climb a biopsy could be considered.

- Consider long term use of denamarin, and monitoring for the signs of cushings developing.

INVOICE

38355

- A primary vacuolar hepatopathy can be breed related and is seen in Scottish Terriers, Schnauzers, Cocker spaniels etc.

DATE

6/2/22



PATIENT

Hugho Dillon

The gallbladder has some polypoid lesions along the wall. This is a non-specific finding often seen with cholecystitis. Consider treatment with Ursodiol +/- antibiotics and continued monitoring with ultrasound for progression of this to a surgical lesions.

SPECIES

Canine

BREED

Mini Schnauzer

SEX

Neutered Male

AGE

7 Years

WEIGHT

41.6 Pounds

INTERPRETED BY

Kathleen Sennello DVM,
MS, Diplomate ACVIM
(Small Animal Internal
Medicine)

IMAGING BY

Loetitia Saint-Jacques,
LVT

HOSPITAL NAME

Valley Vet Clinic

REFERRING VET

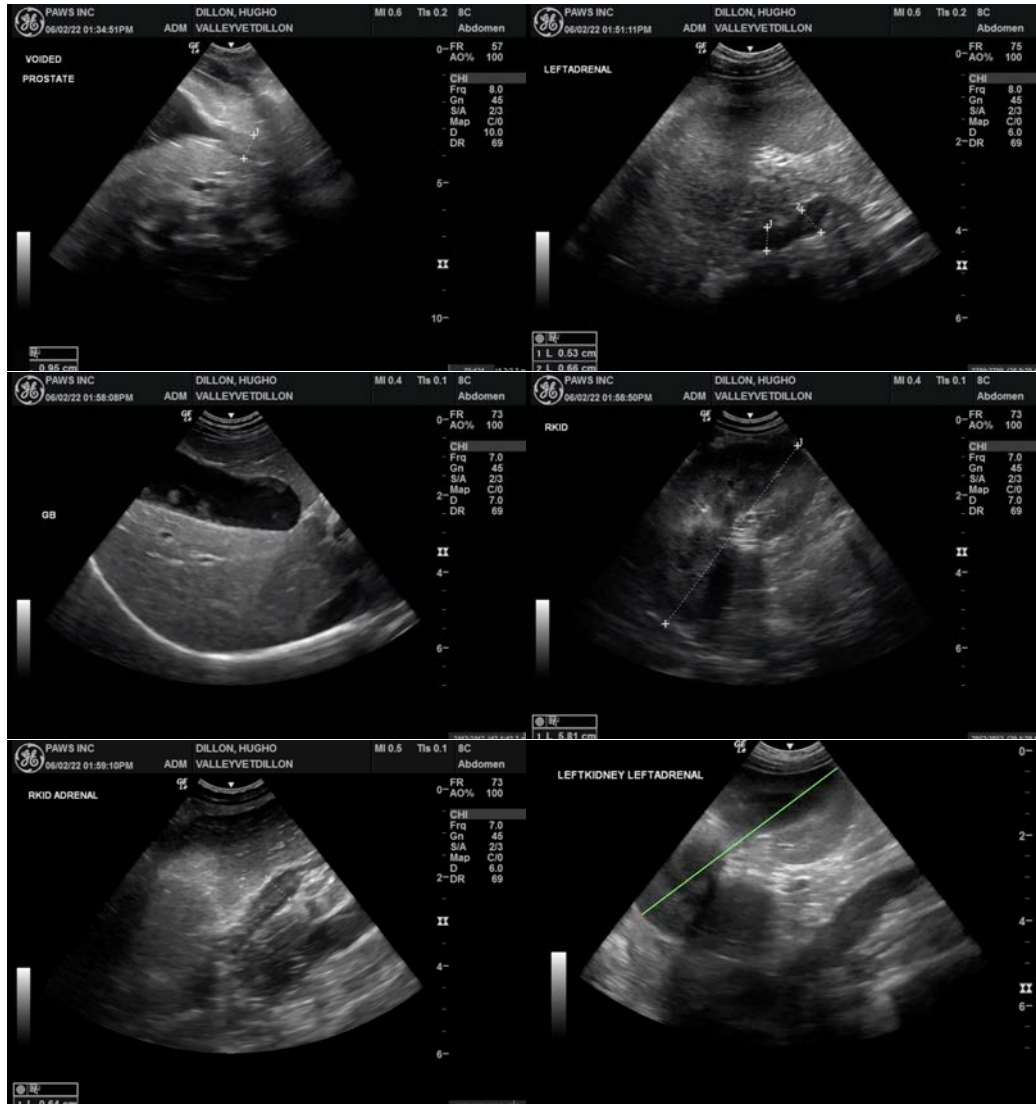
Dr. Megan Plateman

INVOICE

38355

DATE

6/2/22





PATIENT

Hugho Dillon

SPECIES

Canine

BREED

Mini Schnauzer

SEX

Neutered Male

AGE

7 Years

WEIGHT

41.6 Pounds

INTERPRETED BY

Kathleen Sennello DVM,
MS, Diplomate ACVIM
(Small Animal Internal
Medicine)

IMAGING BY

Loetitia Saint-Jacques,
LVT

HOSPITAL NAME

Valley Vet Clinic

REFERRING VET

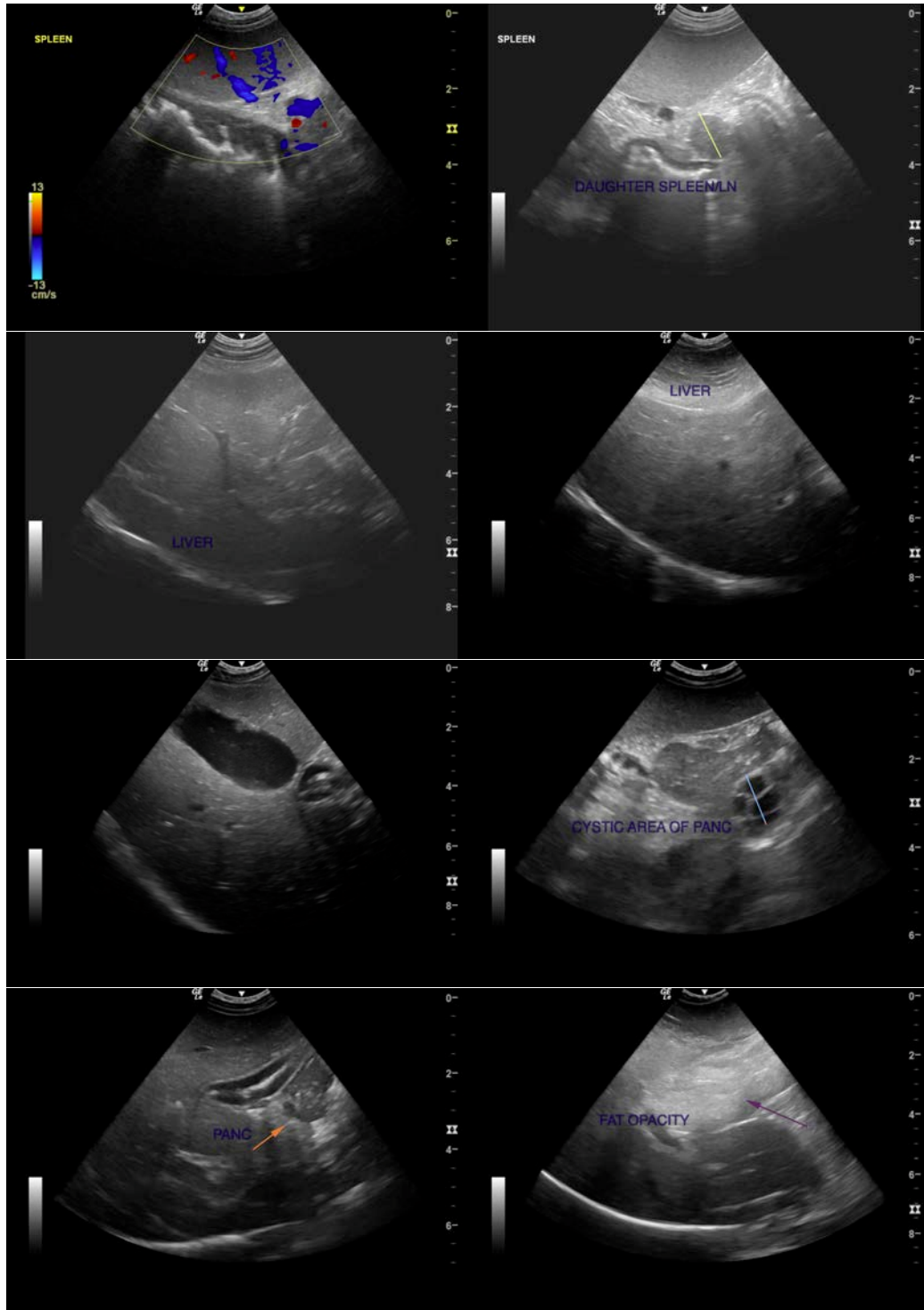
Dr. Megan Plateman

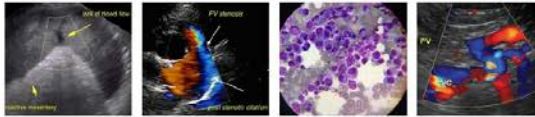
INVOICE

38355

DATE

6/2/22





Portable Animal Wellness Sonography, Inc.

IMAGING PERFORMED BY

pawsonography@gmail.com  530-786-8340

PATIENT

Hugho Dillon

SPECIES

Canine

BREED

Mini Schnauzer

The information and recommendations provided are based on the images presented by the referring veterinarian/sonographer. No evaluation can be communicated regarding pathology that was not visible in the image/video clips provided.

Thank you for this referral. If the clinical or image interpretation does not parallel your findings or if I can be of any further assistance please contact me.

Kathleen Sennello DVM,MS, Diplomate ACVIM (Small animal Internal Medicine)
kathleen.sennello@sonopath.com

SEX

Neutered Male

AGE

7 Years

WEIGHT

41.6 Pounds

INTERPRETED BY

Kathleen Sennello DVM,
MS, Diplomate ACVIM
(Small Animal Internal
Medicine)

IMAGING BY

Loetitia Saint-Jacques,
LVT

HOSPITAL NAME

Valley Vet Clinic

REFERRING VET

Dr. Megan Plateman

INVOICE

38355

DATE

6/2/22