

**PATIENT**

Bonnie Fitzpatrick

**SPECIES**

Canine

**BREED**

Chihuahua X

**SEX**

Spayed Female

**AGE**

10 Years

**WEIGHT**

10.8 Pounds

**INTERPRETED BY**Kathleen Sennello DVM,  
MS, Diplomate ACVIM  
(Small Animal Internal  
Medicine)**IMAGING  
PERFORMED BY**

Amy Mayhew, LVT

**HOSPITAL NAME**

SVS Imaging MI

**REFERRING VET**

Dr. Fitz' Bayside AC

**INVOICE**

38332

**DATE**

6/2/22

**PRESENTING CLINICAL SIGNS**

Recheck echo from May 2022. Diagnosed with pulmonary hypertension. Decreased appetite since diagnosis. No vomiting. \*\*patient difficult to medicate  
 Abnormal PE/Chem/CBC/UA Results: Symptoms are improving since last echo. Currently on vetmedin 1.25 mg BID, theophylline 50mg SID, Sildenafil 12.5 mg BID and Trazodone 12.5 mg BID. She will be finished with a course of orbax on May 18th. We will be emailing bloodwork prior to visit.

**ULTRASONOGRAPHIC EXAMINATION OF THE ABDOMEN****Urinary System**

The urinary bladder is moderately distended with anechoic urine. The Bladder wall, trigone, ureteral papillae and visible urethra (to a depth of 2cm) appear normal with no evidence of wall thickening, mucosal irregularities, masses or cystic calculi.

The left kidney has a normal shape and size (3.4 cm) with small cortical cysts. Overall echogenicity is slightly hyperechoic with poor corticomedullary distinction and a typical 1:3 cortex:medulla ratio. There is no evidence of perinephric inflammation or effusion. There is no evidence of pyelectasia, nephroliths, infarcts or hydronephrosis. Renal vasculature is normal.

The right kidney has a normal shape and size (3.87 cm) with small cortical cysts and pyelectasia at 0.19 cm. Overall echogenicity is slightly hyperechoic with poor corticomedullary distinction and a typical 1:3 cortex:medulla ratio. There is no evidence of perinephric inflammation or effusion. There is no evidence of nephroliths, infarcts or hydronephrosis. Renal vasculature is normal.

**Adrenal Glands**

The left adrenal gland is normal in size measuring 0.39 cm at the caudal pole. It is observed in its normal position cranial to the left renal artery. It is normal in appearance (uniformly hypoechoic) and shape with no evidence of a mass effect.

The right adrenal gland is normal in size measuring 0.37 cm at the caudal pole. It is observed in its normal position between the cranial aspect of the right kidney and the caudal vena cava. It is normal in appearance (uniformly hypoechoic) and shape with no evidence of a mass effect.

**Spleen**

The spleen is subjectively normal in size, echotexture is homogenous, and the splenic capsule is smooth with no irregularities. The blood flow through the hilus and splenic parenchyma appears normal. There is a small hypoechoic lesion within the splenic parenchyma measuring 0.30 cm x 0.39 cm.

**Liver**

The liver is subjectively normal in size, and echogenicity with smooth peripheral margins. The parenchyma is heterogenous in echotexture with subtle, indistinct focal mottling. The visible portions of the vasculature and biliary tract appear normal. No focal nodules or cystic lesions are observed.

The gall bladder lumen is moderately distended. The wall of the gall bladder is not thickened and has a smooth mucosal surface. There is a moderate amount of non-organized echogenic debris. The cystic and common bile ducts are normal/not visible.

**IMAGING PERFORMED BY**

SVS Mobile Imaging MI 734-637-7711  
svsimagingmi@gmail.com



EDUCATIONAL TELECONSULTATION SERVICES™  
1-800-838-4268 info@sonopath.com SonoPath.com

**PATIENT**

Bonnie Fitzpatrick

**SPECIES**

Canine

**BREED**

Chihuahua X

**SEX**

Spayed Female

**AGE**

10 Years

**WEIGHT**

10.8 Pounds

**INTERPRETED BY**

Kathleen Sennello DVM,  
MS, Diplomate ACVIM  
(Small Animal Internal  
Medicine)

**IMAGING PERFORMED BY**

Amy Mayhew, LVT

**HOSPITAL NAME**

SVS Imaging MI

**REFERRING VET**

Dr. Fitz' Bayside AC

**INVOICE**

38332

**DATE**

6/2/22

**Gastrointestinal**

The stomach is moderately dilated with shadowing material most consistent with normal ingesta and gas. It measures at a normal thickness of <0.7cm with some variability due to the presence of rugal folds. The distinction of the gastric wall layering is adequate and there is no impression of reduced peristaltic activity. No masses or focal lesions were observed.

The visualized areas of duodenum, jejunum and ileum have a relatively uniform diameter with minimal fluid distension. Wall thickness is normal. Bowel loops follow a curvilinear path with distinct wall layering maintaining the typical 1:3 muscularis:mucosa layer ratio. The duodenum measured as normal (between 0.3-0.5cm in wall thickness) and the jejunum measured as normal (between 0.2-0.47cm.) Visualized peristalsis appears appropriate. There were no focal lesions consistent with obstruction or a mass effect observed.

The ileocecal junction was visualized and exhibited normal intact wall layering and is subjectively of normal thickness. Sections of colon are visualized with formed fecal material and gas shadowing distally. There is no observed focal or generalized colon wall thickening or loss of layering.

**Pancreas**

The pancreas is prominent and mottled compared to the surrounding isoechoic mesentery. There is no evidence of nodules or cystic lesions. There is no evidence of regional mesenteric inflammation or fluid.

**Free Abdomen**

Evaluation of the peritoneal cavity did not reveal any evidence of effusion, or subjective lymphadenomegaly. The Medial iliac nodes appear normal and there was no evidence of a caudal aortic thrombus at the bifurcation. The omentum is of normal uniform echogenicity.

**PRIMARY FINDINGS**

- Small, hypoechoic lesion visualized within the splenic parenchyma – There is a non-cavitated, hypoechoic splenic nodule visualized. Differentials include lymphoid hyperplasia, extramedullary hematopoiesis, infiltrative neoplasia, inflammation, other. Cytology or histopathology would be necessary to get a definitive diagnosis.
- Decreased corticomedullary distinction in both kidneys with small cortical cysts and right-sided pyelectasia – Mild loss of corticomedullary distinction in both kidneys could be consistent with chronic degenerative disease or interstitial nephrosis. Pyelectasia of the right kidney could be consistent with pyelonephritis, chronic renal disease, secondary to PU/PD or fluid therapy (if applicable), other.
- Moderate shadowing material within the gastric lumen – There is shadowing material seen within the stomach. This could be consistent with ingesta, foreign material, etc. Correlate with abdominal radiographs and feeding history.

**SECONDARY FINDINGS**

- Prominent, mottled pancreas – The pancreatic changes are most consistent with age-related parenchymal remodeling, potentially secondary to a prior inflammatory episode, early fibrosis or chronic pancreatitis.
- Moderate gallbladder debris – The significance of the aggregated gallbladder sludge is unclear. This could represent an early mucocele, cholestasis, or may be secondary to fasting.
- Mildly heterogeneous liver – The hepatic changes are consistent with age-related parenchymal remodeling and are not considered clinically significant at this time.

**IMAGING PERFORMED BY**

SVS Mobile Imaging MI 734-637-7711  
svsimagingmi@gmail.com



**PATIENT**

Bonnie Fitzpatrick

**SPECIES**

Canine

**BREED**

Chihuahua X

**SEX**

Spayed Female

**AGE**

10 Years

**WEIGHT**

10.8 Pounds

**INTERPRETED BY**

Kathleen Sennello DVM,  
MS, Diplomate ACVIM  
(Small Animal Internal  
Medicine)

**IMAGING PERFORMED BY**

Amy Mayhew, LVT

**HOSPITAL NAME**

SVS Imaging MI

**REFERRING VET**

Dr. Fitz' Bayside AC

**INVOICE**

38332

**DATE**

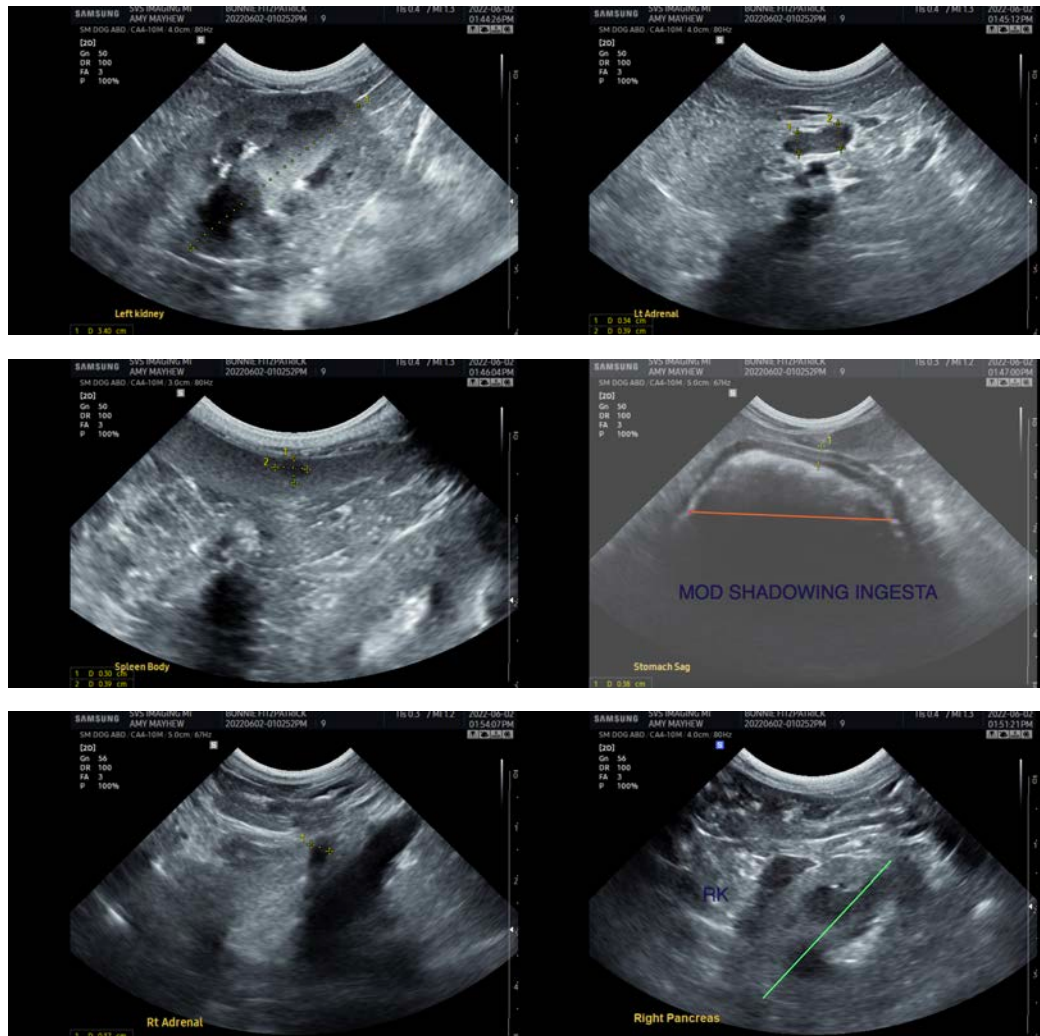
6/2/22

**INTERPRETATION OF THE FINDINGS & FURTHER RECOMMENDATIONS**

An obvious cause for the symptoms described is not visualized, although there is some shadowing material within the gastric lumen. Correlate with radiographs and history to try and determine if this is foreign material or just ingesta. Additionally, the changes in the kidneys are consistent with chronic progressive disease. Recommend blood pressure, urinalysis and culture.

There is a small lesion observed within the spleen. Options moving forward would include continued monitoring or a fine needle aspirate.

Additionally, the pancreas is somewhat prominent. If pancreatitis is thought likely based on the clinical signs exhibited, you could consider a quantitative PLI and empirical treatment for pancreatitis.



**IMAGING PERFORMED BY**

SVS Mobile Imaging MI 734 - 637 - 7711  
svsimagingmi@gmail.com



**PATIENT**

Bonnie Fitzpatrick

The information and recommendations provided are based on the images presented by the referring veterinarian/sonographer. No evaluation can be communicated regarding pathology that was not visible in the image/video clips provided.

**SPECIES**

Canine

Thank you for this referral. If the clinical or image interpretation does not parallel your findings or if I can be of any further assistance please contact me.

Kathleen Sennello DVM,MS, Diplomate ACVIM (Small animal Internal Medicine)

kathleen.sennello@sonopath.com

**BREED**

Chihuahua X

**SEX**

Spayed Female

**AGE**

10 Years

**WEIGHT**

10.8 Pounds

**INTERPRETED BY**

Kathleen Sennello DVM,  
MS, Diplomate ACVIM  
(Small Animal Internal  
Medicine)

**IMAGING  
PERFORMED BY**

Amy Mayhew, LVT

**HOSPITAL NAME**

SVS Imaging MI

**REFERRING VET**

Dr. Fitz' Bayside AC

**INVOICE**

38332

**DATE**

6/2/22